ORIGINAL RESEARCH PAPER
Volume-6 | Issue-11 | November-2017 | ISSN No 2277 - 8179 | IF : 4.176 | IC Value : 78.46
INTERNATIONAL JOURNAL OF SCIENTIFIC RESEARCH

STRONGYLOIDIASIS – AN OPPORTUNISTIC INFECTION IN HIV+ PATIENT

Medical Science

Shivani Sarkar NRS Medical College, Kolkata
Ajay Wani MGM Medical College, Navi Mumbai
Shilpi Sahu Associate Professor, MGM Medical College, Navi Mumbai.

ABSTRACT

A 37 year male from village came to medicine OPD with the complaints of hemoptysis, abdominal pain , fever , weight loss and persistent diarrhea since 20 days. On further investigations patient came to be a known case of HIV since 8 years with current CD4 counts being 48 cells/micro litre. He started receiving ART 5 months back. The patient was given symptomatic treatment and was discharged. After 3 days patient was readmitted with severe vomiting and died immediately on admission. Post-mortem showed small bowel mucosal edema and plenty of strongyloides stercoralis larvae with transmural migration.

KEYWORDS

Strongyloides stercoralis, HIV-1, Vomiting, ART.

INTRODUCTION:

Strongyloidiasis is a human parasitic disease caused by the nematode (roundworm) called strongyloides stercoralis, or sometimes S. fulleborni which is a type of helminth. This intestinal worm can cause a number of symptoms in people, abdominal pain, diarrhea, and weight loss. In some people, particularly those who require corticosteroids or other immunosuppressive medications, Strongyloides can cause a hyperinfection syndrome that can lead to death if untreated. The diagnosis is made by blood and stool tests. Treatment is ivermectin. Strongyloidiasis is a type of soil transmitted helminthiasis. It is thought to affect 30–100 million people worldwide, mainly in tropical and subtropical countries. It belongs to the group of neglected tropical diseases, and worldwide efforts are aimed at eradicating the infection.[1]

CASE STUDY :

In our case patient came from north Indian village & was HIV positive since 8 years. He did not take ART well in time. In some primary health centre he was prescribed ART 5 months back. When the patient came to us he was very weak and had abdominal pain, vomiting and diarrhea. Several investigations like stool and blood tests were done. Stool examination was negative for any parasitic eggs. No eosinophilia was noted in blood. He refused to get admitted and was prescribed symptomatic treatment. After 3 days he returned with severe hemoptysis and died before hospitalization. Post mortem was done and histopathological diagnosis of Strongyloidiasis was made.

Disseminated strongyloidiasis occurs when patients with chronic strongyloidiasis become immunosupressed. It presents with abdominal pain, distension, shock, pulmonary and neurologic complications and septicaemia, and is potentially fatal. The worms enter the bloodstream from the bowel wall, simultaneously allowing entry of bowel bacteria such as E.coli. This may cause symptoms such as sepsis (bloodstream infection),[2] and the bacteria may spread to other organs where they may cause localized infection such as meningitis.[3]

Dissemination can occur many decades after the initial infection[4] and has been associated with high dose corticosteroides, organ transplant, HIV,[5][6] lepromatous leprosy, tertiary syphillis, aplastic anemia, malnutrition, advanced tuberculosis and radiation poisoning.[7] It is often recommended that patients being started on immunosuppression be screened for chronic strongyloidiasis; however, this is often impractical (screen tests are often unavailable) and in developed countries, the prevalence of chronic strongyloidiasis is very small, so screening is usually not cost-effective, except in endemic areas.

It is important to note that there is not necessarily any eosinophilia in the disseminated disease. Absence of eosinophilia may indicate poor prognosis.[8]

Finding Strongyloides in the stool is negative in up to 70% of tests. It is important to undergo frequent stool sampling as well as duodenal biopsy if a bad infection is suspected. The duodenal fluid can be examined using techniques such as the Enterotest string or duodenal aspiration.[9] Larvae may be detected in sputum from patients with disseminated infections.

Given the poor ability of stool examination to diagnose strongyloides, detecting antibodies by ELISA can be useful.[10] Serology can cross-react with other parasites, remain positive for years after successful treatment or be falsely negative in immunocompromised patients.[12][15] Infected patients will also often have an elevated eosinophil count, with an average of absolute eosinophil count of 1000 in one series.[16] The combination of clinical suspicion, a positive antibody and a peripheral eosinophilia can be strongly suggestive of infection.

Post mortem was done and grossly the bowels were edematous, hyperemic. On cut section appeared ulcerated . Focally pseudo-membranes were present.

On histopathology-

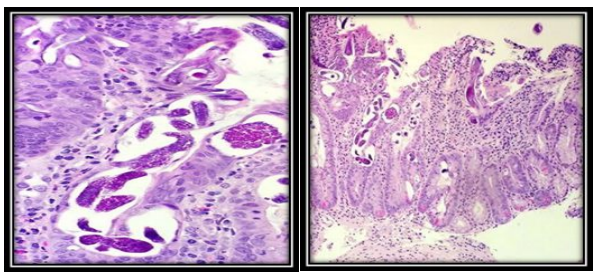

(1) (2)

Figure 1- 400x view- Mucosa of small bowel shows strongyloides stercoralis in all forms.

Figure-2- 100x view- Ulcerated & edematous mucosa of small bowel harbouring strongyloides stercoralis larvae in crypts.

Conclusion- Strongyliodiasis is an opportunistic infection in HIV patients especially when CD4 counts are below 100 cells/microliter. Involvement of the intestines may be asymptomatic but may be associated with abdominal pain, diarrhea, weight loss, malabsorption, nausea, GI bleeding or vomiting. Ivermectin, decreasing immunosuppression and regular checkups are needed to keep these kind of infections in check. Failing to do so increases the risk of mortality.

REFERENCES :

1) "Neglected tropical diseases". Cdc.gov. June 6, 2011. Retrieved 28 November 2014.
2) Ghoshal, UC; Ghoshal, U; Jain, M; Kumar, A; Aggarwal, R; Misra, A; Ayyagari, A; Naik, SR (December 2002). "Strongyloides stercoralis infestation associated with septicemia due to intestinal transmural migration of bacteria". Journal of Gastroenterology and Hepatology. 17 (12): 1331–3. PMID 12423282.

doi:10.1046/j.1440-1746.2002.02750.x
3) Graeff-Teixeira C, da Silva AC, Yoshimura K (Apr 2009). "Update on Eosinophilic Meningoencephalitis and Its Clinical Relevance". Clinical Microbiology Reviews. 22 (2): 322–48. PMC 2668237
4) Gill GV, Beeching NJ, Khoo S, et al. (2004). "A British Second World War veteran with disseminated strongyloidiasis". Trans R Soc Trop Med Hyg. 98 (6): 382–6. PMID 15099996. doi:10.1016/j.trstmh.2003.11.002.
5) Kramer MR, Gregg PA, Goldstein M, Llamas R, Krieger BP (1990). "Disseminated strongyloidiasis in AIDS and non-AIDS immunocompromised hosts: diagnosis by sputum and bronchoalveolar lavage". South Med J. 83 (10): 1226–9. PMID 2218668.
6) Gompels MM, Todd J, Peters BS, Main J, Pinching AJ (1991). "Disseminated strongyloidiasis in AIDS: uncommon but important". AIDS. 5 (3): 329–32.
7) Purtilo DT, Meyers WM, Connor DH (1974). "Fatal strongyloidiasis in immunosuppressed patients". Am J Med. 56 (4): 488–93.
8) Full Text:Hyperinfection by Strongyloides Stercoralis". Omjournal.org. Retrieved 2015-03-13.
9) A new technique for sampling duodenal contents: demonstration of upper small-bowel pathogens.". Am J Trop Med Hyg. 19: 349–52. Mar 1970
10) Carroll, S. M.; Karthigasu, K. T.; Grove, D. I. (1981-01-01). "Serodiagnosis of human strongyloidiasis by an enzyme-linked immunosorbent assay". Transactions of The Royal Society of Tropical Medicine and Hygiene. 75 (5): 706–709. ISSN 0035-9203.
11) "Strongyloidiasis: a review and update by case example". Clin Lab Sci. 21: 82–8. 2008. PMID 18507302.
12) Nuesch, Reto; Zimmerli, Lukas; Stockli, Rolf; Gyr, Niklaus; Christoph Hatz, F.r. (2005-03-01). "Imported Strongyloidosis: A Longitudinal Analysis of 31 Cases". Journal of Travel Medicine. 12 (2): 80–84. ISSN 1708-8305. doi:10.2310/7060.2005.12204.