ORIGINAL RESEARCH PAPER

Volume-8 | Issue-2 | February-2019 | PRINT ISSN No 2277 - 8179

INTERNATIONAL JOURNAL OF SCIENTIFIC RESEARCH

STUDY OF OCULAR FUNDUS FINDINGS IN HYPERTENSIVE PATIENTS ATTENDING TERTIARY CARE CENTER,TELANGANA.

Ophthalmology

Dr. V.E.Raju Asst. Prof., Dept. of Ophthalmology, Gandhi Medical College, Gandhi Hospital, Secunderabad.

Dr.B. Kantha Sree* Assoc. Prof., Dept. Of Ophthalmology, Gandhi Medical College, Gandhi Hospital, Secunderabad. *Corresponding author

Dr. Spandana Post graduate, Department of Ophthalmology, Gandhi Medical College, Gandhi hospital, Secunderabad

Dr.Sai Sharath Meghana House surgeon, Gandhi hospital, Secunderabad, S.V.S Medical College, Mahbubnagar.

ABSTRACT

Blood pressure is the lateral force exerted by the flowing blood on the wall of the arteries. Increase in this pressure leads to hypertension, which in turn affects different organs of the body, when neglected.

AIM: To study the ocular fundus findings in patients with hypertension.

METHODS AND MATERIAL: It is a hospital based interventional study of 50 patients who are diagnosed as hypertensive attending Ophthalmology outpatient department, Gandhi hospital, Secunderabad, in the month of September, from 1st to 30th 2018.

RESULTS: 70% of the patients showed hypertensive changes with male preponderance of 52%.

CONCLUSION: Regular fundoscopy examinations in hypertensive patients can be useful to identify systemic complications before organ damage is apparent.

KEYWORDS

Fundus picture, Complications, hypertension

INTRODUCTION:

Blood pressure means the force exerted by the blood against any unit area of the vessel wall..Hypertension acts as a silent killer Before any apparent end organ damage is clinically seen. Hence, the importance of refining risk stratification strategies to ensure reliable detection of hypertension related end organ damage before it becomes Symptomatic,is important.[2]

Retinal arterioles can be visualised easily and non-invasively and shows similar properties of cerebral and coronary microcirculation such as:[3].

1. They lack sympathetic innervation.
2. They have autoregulation of blood flow
3. Presence of blood retinal barrier.

Therefore retina acts as a window for studying the human circulation.[2] Presence of hypertensive retinopathy may be an indicator of presence of other complications of hypertension, commonly nephropathy.[4]

Hypertensive retinopathy refers to fundus findings in the patients suffering from systemic hypertension. Hypertensive retinopathy can be classified by Keith and Wagner classification [5]:

Grade I :
- Mild generalised arteriolar attenuation (mainly of small branches)
- Broadening of arteriolar light reflex and vein concealment.

Grade II :
- Marked generalized narrowing and focal attenuation of arterioles
- Deflection of veins at arteriovenous crossing (Salus' sign).

Grade III:
- Grade II plus copper wiring of arterioles
- Banking of veins distal to arteriovenous crossings (Bonnet sign)
- Tapering of veins on either side of crossings (Gunn sign)
- Right angle deflection of veins (Salus' sign)
- Flame-shaped hemorrhages
- Cotton wool spots
- Hard exudates.

Grade IV:
- Grade III plus silver wiring of arterioles
- Papilledema

METHODS AND MATERIALS:

This is a hospital based interventional study of 50 patients who came to Ophthalmology outpatient department and are known hypertensives in the month of September 2018, from 1st to 30th, in Department of Ophthalmology of Gandhi hospital, Secunderabad.

A total of 50 patients were identified: a standard proforma of details (name, age, gender, blood pressure recordings) have been taken and associated investigations have been done. All the patients were taken for ocular fundus examination after Dilatation with with 0.5% Tropicamide eye drops using indirect ophthalmoscope and +20 lens and their results have been noted down.

The retinal changes have been graded according to the Keith and Wagner classification into four grades and patients with changes of both diabetic and hypertensive retinopathy changes have been labeled under mixed retinopathy changes.

RESULTS:

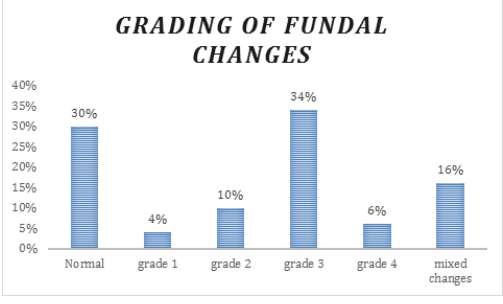

Out of 50 hypertensive patients, 35(70%) showed varying grades of fundus pictures. These patients showed Grade1=2(4%) ; Grade 2 = 5(10%) ; Grade 3 = 17(34%) ; Grade 4 = 3(6%) and 8 (16%) patients showed mixed changes. The findings have been shown in the following figures.

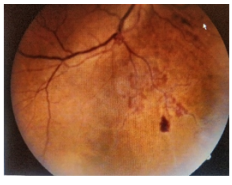



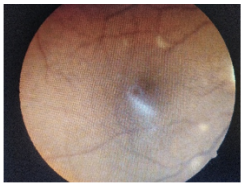
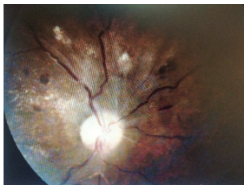

Further investigations showed co morbidities present in the patients. Most of the patients had chronic kidney disease(54%). The co-morbidities were high in the age group of 55-65 years. These are shown in fig1.1 and 1.2.

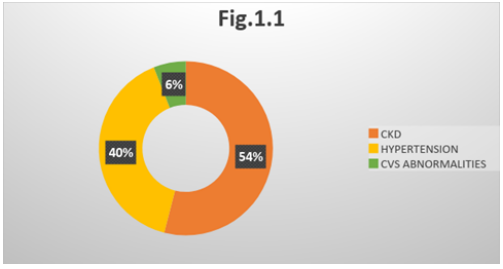

In the present study, a 18 year old female patient came with the BP recordings of 200/110 mm/Hg. in her lower limbs and 140/90 mm/Hg. in her upper limbs, she had grade 3 retinopathy changes in both her eyes and was diagnosed with renal artery stenosis.

Another 27yr old female patient came with accelerated hypertension of 200/120 mm of Hg showed grade 3 hypertensive retinopathy changes, was diagnosed with left ventricular dysfunction.

In adolescents and young adults with a hypertensive crisis, a secondary cause of hypertension must be suspected, and among them, renovascular disease is one of the most frequent causes.[6]



DISCUSSION:

In this study, there was a preponderance of male (52%) , compared to female(48%) patients. When the ocular fundus changes have been graded, 34% of the patients were showing Grade 3 changes in the retina; while the co-morbidities were high in the age group of 55-65 years and are associated chronic kidney disease which is also high in the same age group.A similar study done in Bangladesh showed the maximum of grade 1 changes as14.7% and showed CKD(9.78%)as highly associated co morbidity[5].Another study done in Africa showed hypertensive retinopathy changes as grade1=42.1%, grade 2=11.3%, grade3=23.3%, grade 4=6.9%. The same study showed CKD as the maximum associated disease.[7]A study done by Singh J group showed grade 1(24%) changes in majority of the patients, and showed CKD as a majorly associated co morbidity of the patients(10%).[8]

STUDY	*Grade 1*	*Grade 2*	*Grade 3*	*Grade 4*
Bangladesh	14.7%	8.6%	5.8%	0.3%
Singh J study	24%	50%	15%	11%
African study	42.1%	11.3%	23.3%	6.9%
Present study	4%	10%	34%	6%

CONCLUSION:

In this study, patients with hypertension showed various systemic complications along with the ocular fundus changes. This shows that there is a need for all the hypertensive patients to go for regular checkups and fundoscopy examinations to prevent further systemic complications of hypertension; as the fundal changes in the eye to an extent reflect upon the severity of the systemic changes of hypertension in the patient.

DISCLOSURE:

The conicts of authors disclose no potential interest. There is no financial interest behind this study.

REFERENCES:

1. Hall and Guyton; Guyton and Hall textbook of Physiology; 12th edition; p.162.
2. A.Grosso,F. Veglio, T Y Wong, etal., Hypertensive retinopathy revisited;Br J Opthalmol. 2005 Dec; 89(12): 1646-1654.
3. Chaine G, Kohner EM. [Hypertensive retinopathy]. J Fr Ophtalmol. 1983;6(12):995-1005.
4. Mondal RN, Matin MA, Rani M, Hossain ZM, Shaha AC, et al. (2017) Prevalence and Risk Factors of Hypertensive Retinopathy in Patients. J Hypertens 6: 241. doi:10.4172/2167-1095.1000241
5. AK Khurana, Aruj K Khurana, Bhawna P Khurana, Comprehensive Opthalmology , 7th edition,2019, p.281-284.
6. Karen Janeth Arriozola-Rodríguez, Juan Carlos Serna-Ojeda,,* Virginia Alejandra Martínez-Hernández, and José Luis Rodríguez-Loaiza; Case Rep Ophthalmol. 2015 Sep-Dec; 6(3): 415–419.;Published online 2015 Dec 2
7. N Kabedi, David L Kayembe,Tharcisse K Kayembe,etal.;Cardiovasc J Afr. 2014 Sep-Oct;25(5):228-232.
8. Singh J,Tewari M.K.,Khosla PK,Azad R;Hypertensive Retinopathy,Indian J Ophthalmol. 1983;31,suppl S1: 971-4