ORIGINAL RESEARCH PAPER

Volume-8 | Issue-6 | June-2019 | PRINT ISSN No. 2277 - 8179

INTERNATIONAL JOURNAL OF SCIENTIFIC RESEARCH

STUDY OF ROLE OF SKIN SURFACE BIOPSY IN SUPERFICIAL CUTANEOUS FUNGAL INFECTIONS

Dermatology

Dr Rajendra Shinde Associate Professor, Department of Dermatology, MIMER Medical College, Talegaon Dabhade, Pune -410507, Maharashtra, India

Dr. Richa Chopra* Ex-Resident, Department of Dermatology, MIMER Medical College, Talegaon Dabhade, Pune -410507, Maharashtra, India *Corresponding Author

Dr. Sunil Tolat Hon. Professor, Department of Dermatology, BJGMC, Pune -411001, Maharashtra, India

ABSTRACT

Context : Cutaneous fungal infections are very common in a tropical country like India. Though most of them are diagnosed clinically some may require lab investigations. Skin scraping is the commonest way of sample collection but with certain limitations. Skin surface biopsy is another very simple and efficient way of collecting the sample required for lab diagnosis and confirmation of cutaneous fungal infections.

Aims : To study the role of skin surface biopsy in superficial cutaneous fungal infections and compare it with scraping.

Settings & Design : Hospital based comparative study was done in a rural tertiary care hospital for a duration of 24 months.

Materials &Methods : 100 patients fulfilling inclusion criteria were enrolled after consent and skin scraping along with skin surface biopsy was done under all aseptic precautions. 10 % KOH mount was prepared and seen under light microscope of both the samples.

Results : The positive yield was 86% in skin surface biopsy compared to 74% in scraping.

Conclusion : Skin surface biopsy is an easy, cost effective, rapid and efficient method of sample collection in lab diagnosis of superficial cutaneous fungal infections.

KEYWORDS

skin surface biopsy cutaneous fungal infections

INTRODUCTION :

Superficial cutaneous fungal infections are limited to the epidermis, as opposed to systemic fungal infections (i.e. endemic mycoses and opportunistic infections). Three groups of cutaneous fungi cause superficial infections: Dermatophytes, Malassezia species and Candida species [1]. Dermatophytes (which include Trichophyton spp., Microsporum spp., and Epidermophyton spp.) infect keratinized tissues: the stratum corneum, the nail or the hair. Dermatophytoses are estimated to affect 20-25% of people worldwide, making them one of the most common infections [1]. Most diagnoses of fungal infections of the skin can be made by physical examination, assisted by the use of a Wood's lamp, skin scrapings for microscopic examination. Skin scrapings are often difficult to collect and tend to be blown away by the slightest breath of air. The small keratin fragments show little of the growth patterns of superficial fungi, which proliferate largely in a horizontal plane. A good method for the diagnosis of a superficial mycosis should combine ease of collection with simple processing for direct examination and culture [2]. The technique of taking a skin surface biopsy suits these requirements and allows the ready removal of large areas of intact stratum corneum cells without much discomfort to the patient. The cells, being cemented firmly to the glass slide, are already mounted for examination and cannot be lost or deteriorate to any extent even if there is a delay in transit to the laboratory. These unfixed specimens are suitable for a variety of staining techniques as well.

Cyanoacrylate gel (N-ethyl-2-cyanoacrylate gel) is an acrylate adhesive with avid affinity for cutaneous surface, is non-toxic, non-adherent, optically clear, polymerizes and bonds rapidly in the presence of small amounts of moisture and pressure. It was these properties of the resin which prompted us to try and make use of it in diagnostic dermatology.

Goldschmidt and Kligman described a method using a glass slide with a sticky mass to obtain stratum corneum for examination in the horizontal plane [3]. Marks and Dawber in 1971, mentioned a simple non-invasive sampling method to collect the horny layer of the skin which they described as "skin surface biopsy" [4]. The skin surface biopsy technique has been used to study the superficial fungal infections [5], erythrasma organism in situ [6] and Demodex folliculorum [7]. Cyanoacrylate has also been studied for use in primary closure of skin incisions [8]. Thus, we conducted this study to find the role of skin surface biopsy in superficial cutaneous fungal infections.

MATERIALS AND METHODS :

Type of Study & Study Area: A hospital based Comparative study was conducted at Department of Dermatology, MIMER Medical College, Talegaon General Hospital for duration of 2 years (July 2013 to May 2015).

Source of data: All patients attending the dermatology OPD with complaints suggestive of superficial cutaneous fungal infection were included in the study after counseling and obtaining informed written consent.

Inclusion criteria:

1. All patients attending the skin OPD of MIMER Medical College, Talegaon General Hospital and having any kind of superficial cutaneous fungal infection.
2. Only those patients having superficial fungal infections and giving their consent for the study.

Exclusion criteria:

1. Patient with known allergy to cyanoacrylate gel
2. Patient (or their guardians in case of minor) not willing to sign the consent form for inclusion in the study
3. Patients with history of using topical or systemic antifungals.

Sampling Technique and Sample Size:

Previous studies show that sensitivity by skin surface biopsy is 80%. Considering allowable error of 10% at 95% confidence interval ($p < 0.05$) with 80% Power of test, estimated minimum sample size is 67 in each group. In order to avoid personal and other clinical bias, samples by both methods were taken from the same patient. So, 100 cases were included in the study. Sample was taken from each patient by both techniques i.e. skin surface biopsy and skin scraping.

Methodology

A detailed history regarding duration of existing problem and clinical examination was done according to the case study proforma. Skin surface biopsy and skin scraping was performed on each patient. 10% KOH mounting and microscopic examination was done and results were noted down. Counseling and treatment of the infection was done after obtaining results and patients were followed up depending on the type of infection.

For taking skin surface biopsy, the adhesive drops (Fevi-quick) were placed on skin and then glass slide was pressed over it and removed gently after it was allowed to dry for 30 seconds.

Precautions

1. The glass slide sticking to the patients skin was overcame by

applying acetone, which readily dissolved the cyanoacrylate gel.
2. Fumes causing irritation to the eyes and nose was prevented by taking sample in well ventilated rooms.

Statistical Analysis

All the data was entered in Microsoft Excel sheet and then transferred to SPSS software ver. 17 for statistical analysis. Appropriate tests were applied according to type and distribution of data and a p-value of less than 0.05 was taken as significant.

RESULTS AND OBSERVATIONS :

Table 1.Site wise distribution of patients

Site	No of patients / %
Extremities (LL/UL)	20
Groin	15
Abdomen	11
Chest	11
Back	10
Face	9
Neck	9
Feet	8
Hand	3
Scalp	2
Shoulder	2

Table 2. Age wise distribution of patients

Age group in years	No of patients /%
</=20	22
21-40	48
41-60	25
>60	5

Table 3 Gender distribution of patients

Gender	No of patients / %
Male	69
Female	31





Fig. 1 & 2 : Skin surface biopsy

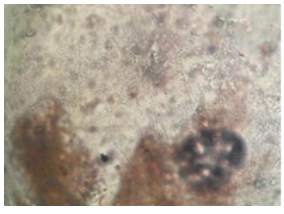



Fig 3 & 4 Fungal elements under microscope

Table 4. Comparison of +ve yield by skin surface biopsy and scraping in various diagnosis

Diagnosis	No.	Skin surface biopsy		Scraping	
		Positive	%	Positive	%
P. versicolor	36	33	91.7	27	75
Tinea Corporis	20	17	85	11	55
Tinea incognito	17	17	100	16	94.1
Tinea facie	7	7	100	5	71.4
Tinea pedis	7	5	71.4	6	85.7
Tinea cruris	6	5	83.3	5	83.3
Tinea manuum	3	1	33.3	3	100
Tinea capitis	1	1	100	1	100
Candidial intertrigo	3	0	0	0	0
Total	100	86	86	74	74

DISCUSSION :

The dermatophytes are amongst the commonest infectious agents of man. India has a varied topography with areas falling within the tropical and subtropical zones. The geographical and climatic conditions have always predisposed the population to superficial mycotic infections [9]. Superficial mycoses form a large group of patients attending the Dermatology OPD of our tertiary care hospital. The temperature and moisture in this area is high most of the time. The higher temperature as well as body sweating facilitates fungal growth [9-11].

Socio-demography

Mean age of the study subjects in present study was 33.1 years. This can be explained by the fact that higher incidence of physical activity is present in this age group which increases sweating and thereby chances of fungal infections. In a similar study by Bhavsar H et al. mean age of the study subjects was 39.1 years with over half of them between 20-40 years of age [12]. In another study by Das S et al. mean age of the study subjects was 35.8 years [13]. Sarika G et al. also observed the maximum incidence (47%) in the age group of 16 to 30 years [14]. Male predominance was observed in present study with male (69%) to female (31%) ratio of 2.25:1. This can be again explained by the fact that higher (66) proportions of males were involved in outdoor physical activity which increases sweating. In a study by Das S et al., male: female ratio was 1.65: 1. [13]. In a similar study by Sarika G et al., out of 150 clinically suspected patients, 74% (111) patients were males and 26 % (39) were females [14]. Other studies, done by Aruna Aggarwal (1.8:1) [15], Nawal (1.8:1) [10], Grover WCS (4.26:1) [16], Parul Patel (1.79:1) [11], V Bindu (2.06:1) [17] have similar observations.

Site & diagnosis :

Most common affected site was trunk (32%) followed by upper or lower limbs (20%), groin (15%), face and neck (9% each) and feet (8%). Most common diagnosis was P. versicolor, observed in one third of the patients (36%) followed by tinea corporis (20%), incognito (17%), facie (7%), pedis (7%) and cruris (6%). Candida infection was observed in 3% subjects. In a study by Das S et al., most common site involved was trunk with tinea corporis (21.4%) being the most common laboratory-confirmed infection followed by onychomycoses (14.7%) and tinea capitis (6.2%)[13]. In another study by Sarika G et al., maximum infection was reported from groin (32.67%) followed by hands/legs (21.33%) and thighs (15.33%) [14]. Bhavsar H et al. also noted trunk as the most common site with tinea corporis (199/377) as most common clinical presentation (52.78%) followed by tinea cruris (15.64%). P. versicolor occupied the third position with 12.46% patients [12]. Most common infection observed in a study by Tan H et al. was tinea pedis (27.3%), followed by pityriasis versicolor (25.2%) and tinea cruris (13.5%) [18]. Our findings also correlated well with other studies i.e. Aggarwal et al. [15], Nawal et al. [10], Patel et al. [11], and Bindu et al. [17].

Skin surface biopsy and scraping

In dermatology, a potassium hydroxide (KOH) mount of a skin scraping /brushing is a common procedure performed to demonstrate the evidence of fungal infection in skin, hair and nails. In present study the overall sensitivity and diagnostic yield of skin scraping and KOH mount was 74%. Miller and Hodgson reported a sensitivity of 77% of KOH examination of skin scrapings [19]. Ecemis T et al. noted the sensitivity and specificity of direct microscopy as 95.7% and 69.6% respectively [20]. The results of Jacob L et al. showed the sensitivity for KOH smear as 41.7% (34.6 to 49.1%) [21]. Das S et al. found the sensitivity of KOH as 86.5% [13]. In another similar study by Sarika G et al., samples from 150 patients were collected and subjected to KOH test and culture. About 84% of the KOH positive samples showed positive test for culture, thereby indicating its high sensitivity as a diagnostic tool [14]. The skin surface biopsy is a practical, easily performed and non invasive method for obtaining a sample of infected stratum corneum or hair. This technique is particularly useful in diagnosing superficial fungal infections. In present study the overall sensitivity and diagnostic yield of the skin surface biopsy was 86%. In 1963, Keddie et al. used a cyanoacrylatc adhesive to obtain strips of horny layer[22]. This technique was re-evaluated in 1971 by Marks & Dawber[4]. These authors added minor modifications to the initial technique and named it 'skin surface biopsy'. Their method consisted of the following very simple steps: (i) a drop of the adhesive is placed on the skin. (2) a clear glass slide (or cover slip) is gently pressed on the drop for 30 seconds. (3) the slide is then removed. A layer of stratum corneum is removed with the adhesive which remains attached to the glass slide. In 1974, Whiting & Bisset investigated a large number of superficial fungal infections of the skin by the same technique. They showed that the method proved to be a useful tool for the clinician [5]. Since then, very few studies have assessed the efficacy of skin surface

biopsy in diagnosing superficial mycosis. In one such study, Katz h et al. found that skin surface touch print is a practical, easily performed and non invasive method for obtaining a sample of infected stratum corneum or hair. They found this technique particularly useful in diagnosing superficial fungal infections [23]. Gerald P et al. in their review concluded that cyanoacrylate skin surface biopsy , represents a convenient low cost procedure. It is a minimally invasive method collecting a continuous sheet of stratum corneum and horny follicular casts. In the vast majority of cases, it is painless and is unassociated with adverse events [24]. In present study, the sensitivity of skin surface biopsy and scraping was 86% and 74% respectively with yield of skin surface biopsy better or equal to skin scraping in most of the fungal pathologies. Candidiasis was much more difficult to diagnose as the pseudohyphae are thinner and harder to find than dermatophytic hyphae and the spores may be scanty. In a similar study by Lachapelle JM et al., direct microscopic comparison has been made between a modified technique of skin biopsy and conventional scraping as procedures for collecting material from interdigital spaces in 30 patients with bilateral athlete's foot. It has been shown that the skin surface biopsy gives a slightly greater number of positive results than the conventional scraping technique [25]. Thus, we observed that skin surface biopsy method is a useful tool for the diagnosis and study of superficial fungal infections involving the face, trunk, groins and limbs. It is a quick and easy way of collecting intact sheets of stratum corneum and hair, which remain attached to the glass slide and arrive in the laboratory intact. Skin surface biopsy offers some unquestionable advantages over conventional scraping:

(a) It allows good observation of the areal extent and growth pattern of superficial fungi.
(b) It provides permanent slides, available for comparison, especially for evaluating the efficiency of topically applied anti-fungal drugs.
(c) It is a useful method for taking samples in children and apprehensive patients who are afraid of blade used for taking skin scraping.
(d) Finally, it might be useful to grow cultures from horny material obtained with the modified skin surface biopsy, by placing glass slides directly on sabouraud's dextrose agar. A significantly greater number of positive cultures can be obtained by this technique than by conventional scraping.

CONCLUSION :

The most common diagnosis was P. versicolor, observed in one third of the patients (36%) followed by tinea corporis (20%), incognito (17%), faciei (7%), pedis (7%) and cruris (6%). Candida infection was observed in 3% subjects. The overall diagnostic yield of the skin surface biopsy was 86% and that of skin scraping was 74%. The sensitivity of the skin surface biopsy and scraping was 86% and 74% respectively with positive predictive value of 100% for both. The yield of skin surface biopsy was better or equal to skin scraping in most of the fungal pathologies. The skin surface biopsy method is a useful method for the diagnosis of superficial fungal infections involving the scalp, face, trunk, groins and limbs.

A clinician, with experience in the method, can frequently diagnose fungal infection by direct examination of a specimen treated with KOH. We thus, conclude that skin surface biopsy and scraping are complementary diagnostic tests for superficial fungal infections, with the former being more sensitive of the two and showing a better diagnostic yield. We also found skin surface biopsy to be more useful in children and apprehensive patients who were afraid of the scalpel blade used in scraping. Skin surface biopsy can be easily used for diagnosis of fungal infections in resource limited settings where rapid and low cost diagnosis is required.

Conflict of interest : Nil

REFERENCES :

1. Rezabek, George H., Friedman AD. Superficial fungal infections of the skin. Drugs. 1992;43 (5): 674-682.
2. Stevens, Dennis L, et al. Practice guidelines for the diagnosis and management of skin and soft-tissue infections. Clinical infectious diseases. 2005;41(10): 1373-1406.
3. Goldschmidt, Kligman. Exfoliative cytology of human horny layer. Method of cell removal and microscopic techniques. Arch. B Derm. 1967;96:572
4. Marks R, Dawber RPR. Skin surface biopsy: an improved technique for the examination of the horny layer. British journal of dermatology. 1971; 84:117.
5. Whiting DA ,Bisset EA. The investigation of superficial fungal infections by skin surface biopsy. British journal of dermatology. 1974;91 : 57-65.
6. Marks R, Ramanarain RD, Bhogal B, Moore NT. The erythrasma microorganism in situ : Studies using the skin surface biopsy technique. Journal clin.path.1972; 25:799-803.
7. Nejad KR, Salkhordeh N, Sarrafian g et al. Non invasive skin surface biopsy : An easy technique to detect dermodex folliculorum. Research in pharmaceutical sciences.2012;7:5.
8. Fischl RA.An adhesive for primary closure of skin incisions: A preliminaryreport. Plast. reconstr. surg. 1962; 30: 607-610.
9. Mishra M, Mishra S, Singh PC, et al. Clinico-mycological profile of superficial mycosis. Indian J Dermatology, Venereology, Leprology. 1998;64:283-5.
10. Nawal P, Patel S, Patel M et al. A study of superficial mycosis in tertiary care hospital NJIRM 2012; 3(1): 95-99.
11. Patel P, Mulla S, Patel D, Shrimali GA. Study of superficial mycosis in south Gujarat region. National journal of community medicine.2010;1(2).
12. Hitendra B et al. A study of superficial mycoses with clinical mycological profile in tertiary care hospital in Ahmedabad, Gujarat. National Jr of medical research.2012;160-4.
13. Das, Shukla, Goyal R, Bhattacharya SN. Laboratory−based epidemiological study of superficial fungal infections. The Journal of Dermatology. 2007; 34(4): 248-253.
14. Sarika, Gupta, et al. Prevalence of dermatophytic infection and determining sensitivity of diagnostic procedures. Int J Pharm Pharm sci. 6(3): 35-38
15. Aggarwal A, Arora U, Khanna S. Clinical and mycological study of superficial mycoses in Amritsar. Indian J dermatology 2002; 47(4): 218 –20.
16. Grover WCS, Roy CP. Clinico–mycological profile of superficial mycosis in a hospital in north-east India. Medical Journal Armed Forces India 2003; 59(2):114- 6.
17. Bindu V, Pavithran K. Clinico - mycological study of dermatophytosis in Calicut. Indian J Dermatology Venereology Leprology 2002;68:259-61.
18. Tan H H. Superficial fungal infections seen at the national skin centre. Singapore.. Jpn J Med. Mycol, 2005; 46: 77-80.
19. Miller MA, Hodgson Y. Sensitivity and specificity of potassium hydroxide smears of skin scrapings for the diagnosis of tinea pedis. Arch. of dermatology. 1993; 129(4):510–511.
20. Ecemis, Talat, et al. The necessity of culture for the diagnosis of tinea pedis. The American journal of the medical sciences. 2006; 331(2): 88-90.
21. Levitt, Oren J, et al. The sensitivity and specificity of potassium hydroxide smear and fungal culture relative to clinical assessment in the evaluation of tinea pedis: a pooled analysis. Dermatology Research and Practice. 2010.
22. Keddie FM, Shadomy S :Aetiological significance of pityrosporum orbiculare in tinea versicolor. Saburaudia 3:21-25, 1963.
23. Katz HI, Prawer SE, Hien NT, et al. Skin surface touch print for diagnosing fungal infections. American family physician. 1985; 31(4): 189–194.
24. Pierard GE, Franchimont CP, Dowlati A. Skin surface biopsy in clinical and experimental dermatology. Revue Europeenne de dermatologieet de MST. 1992; 4: 445–466.
25. Lachapelle JM, Gouverneur JC, Boulet M, Tennstedt D. A modified technique of skin surface biopsy. Its interest for the investigation of athlete's foot. British journal of dermatology.1977; 97(1) : pp. 49–52.