ORIGINAL RESEARCH PAPER
Volume-6 | Issue-9 | September-2017 | ISSN No 2277 - 8179 | IF : 4.176 | IC Value : 78.46
INTERNATIONAL JOURNAL OF SCIENTIFIC RESEARCH

STUDY ON ANATOMICAL VARIATIONS OF SACRAL HIATUS AND ITS CLINICAL RELEVANCE IN CAUDAL EPIDURAL BLOCK

Anatomy

Chandraphilip X Professor, Department of Anatomy, Mahatma Gandhi Medical College and Research Institute, SBV University, Puducherry, India.

Prabavathy G Assistant professor, Department of Anatomy, Mahatma Gandhi Medical College and Research Institute, SBV University, Puducherry, India, 9003833409. Corresponding author

Jayanthi S Tutor, Department of Anatomy, Mahatma Gandhi Medical College and Research Institute, SBV University, Puducherry, India.

ABSTRACT

Introduction: Understanding the Anatomical variations of Sacral hiatus using bony land marks impoves the reliability of caudal epidural block. Caudal block is indicated whenever the area of surgery involves lower lumbar and sacral nerve roots.. Hence the present study was made in an attempt to define different parameters to locate the sacral hiatus precisely.

Material and Methods: The study was carried out by using 60 complete & undamaged dry sacrum which were obtained from the department of Anatomy, Mahatma Gandhi Medical College & Research Institute, Puducherry. Various parameters of sacral hiatus were measured using a Vernier caliper with 0.1mm accuracy. The various shapes of sacral hiatus was also observed.` `

Results: Majority of the bones had a U shaped sacral hiatus (63%), followed by V shaped (30.5%), irregular shape (5.5%) and 1% sacral hiatus agenesis. Position of the apex was most commonly seen at the level of S4 vertebra and the base of sacral hiatus was most seen at the level of S5 vertebra. The other parameters were recorded and tabulated.

KEYWORDS

Caudal epidural block, sacral cornua, sacral hiatus.

Introduction:

Sacrum is a large triangular bone wedged between the two hip bones and contributes to the formation of pelvic girdle. Raised interrupted crest in the median plane which bears four spinous tubercles is called median sacral crest. An inverted 'U' shaped gap below the fourth spinous tubercle is called sacral hiatus. It is due to failure of laminae of fifth sacral vertebra to meet in the median plane. The free and projecting part on either side of the sacral hiatus at inferior part of the fifth sacral vertebra is called sacral cornua [1].

Sacral hiatus is used as a landmark to give caudal epidural analgesia [2], epidural anaesthesia in obstretics [3], and Orthopaedic practice for transpedicular, lateral mass screw placement [4]. The reliability and success of caudal epidural anaesthesia depends upon anatomical variations of sacral hiatus as observed by various authors [4,5,6]. The surface landmark for sacral hiatus lies about 2 inches above the tip of the coccyx, beneath the skin of natal cleft [7]. The sacral hiatus is covered by skin, subcutaneous fatty layer and superficial dorsal sacrococcygeal ligament which has to be pierced to reach the sacral canal [8]. The dural sac ends at the level of the second piece of the sacrum. The sacral canal below this level contains extradural fat, vertebral venous plexus, lower sacral nerve roots and the filum terminale [8, 9]. If the laminas of the higher sacral vertebra are not fused, then there will be a high sacral hiatus. If there is non fusion of laminae of all the sacral vertebra, there will be midline gap [4]. In spina bifida occulta, the posterior elements of upper sacral vertebra fail to fuse (10, 11). These kind of anatomical variations will lead to painful conditions of the back and some clinical procedure failures [12]. So understanding the anatomical variations of sacral hiatus using bony land marks may improve the reliability of caudal epidural block [13]. The equilateral triangle between the apex of sacral hiatus and superolateral crest or posterior superior iliac spines is certainly of use in determing the location of sacral hiatus during caudal epidural block [14].

Materials and methods:

Sixty complete & undamaged dry sacrum of unknown age and sex from the Department of Anatomy, Mahathma Gandhi Medical College and Research Institute, Puducherry, were studied. Damaged, malformed, and sacrum with signs of previous fractures were excluded from the study. The various dimensions of the sacral hiatus were measured using a Vernier caliper with 0.1mm accuracy. The various parameters include:

1) Shape of the hiatus
2) Level of apex of hiatus
3) Level of base of hiatus
4) Length of hiatus- measured from apex to midpoint of the base
5) Depth at the apex
6) Transverse width of sacral hiatus at the base(Intercornual distance)
7) Distance between the apex of the sacral hiatus and second sacral spinous process.
8) Distance between two superolateral crests.
9) Distance between right superolateral crest and apex
10) Distance between left superolateral crest and apex.

Continuous variables are expressed in terms of mean and standard deviation.

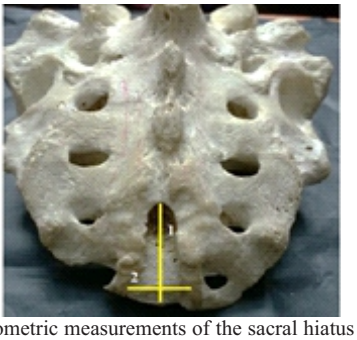

Fig 1: Morphometric measurements of the sacral hiatus 1. Height of the sacral hiatus 2. Width of the sacral hiatus at the level of sacral cornua

Results:

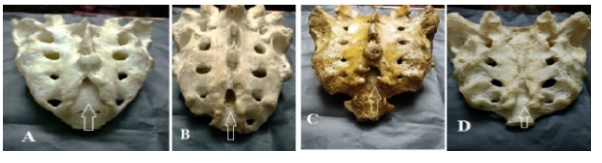

Fig 2 Shape of Sacral hiatus A) Inverted V shaped B) Inverted U shaped C) Irregular shaped D) sacral hiatus agenesis.

Shape of the sacral hiatus – Among the observed cases the most

commonly encountered shape of sacral hiatus is inverted 'U' shape (63%), inverted 'V' shape (30.5%), irregular shape (5.5%) and 1% sacral hiatus agenesis.

Level of apex of hiatus – Position of the apex showed considerable variations ranging from S2-S4 vertebra, but most commonly seen at the level of S4 vertebra (80%), in 15% at the level of S5 vertebra, in 4% at the level of S3 vertebra and 1% at the level of S2 vertebra.

Level of base of Hiatus – Position of the base of sacral hiatus was seen at the level of S5 vertebra in 90% of cases and S4 vertebra in 10 % of cases.

Length of Hiatus- showed variations ranging from 0.8-4.8cm and the average height was 2.4cm.

Depth at the apex- ranging from 0.6-1cm and the average was 0.6cm.
Transverse width of sacral hiatus at the base- ranging from 0.9-1.8cms and the average was 1.5cm.

Distance between two superolateral crest - ranging from 5.2-6.4 and the average was 6.4.

Distance between right superolateral crest and apex - ranging from 5.6-6.8 and the average was 6.8

Distance between left superolateral crest and apex - ranging from 5.6-7.3 and the average was 6.7cm.

Distance between S2 vertebra & apex: Ranging from 3.5-4.6 and the average was 4.3 cm.

The measurements of all these various other parameters are tabulated as follows (Table 1)

Table 1: Measurements of various parameters of sacral hiatus

S. No	Parameters	Range (cm)	Mean (cm)	Standard deviation
1	Length of the Hiatus	0.8-4.8	2.4	±1.147
2	Depth at apex	0.6-1	0.6	±0.416
3	Width at base	0.9-1.8	1.5	±0.482
4	Distance between two superolateral crest	5.2-6.4	6.4	±0.442
5	Distance between right superolateral crest & apex	5.6-6.8	6.8	±1.468
6	Distance between left superolateral crest & apex	5.6-7.3	6.7	±1.768
7	Distance between S2 vertebra & apex	3.5-4.6	4.3	±0.854

Discussion

The precise knowledge of different anatomical variations related to the sacral hiatus increase the success rate of the caudal epidural anaesthesia. Tsui BC et al [15] reported 25% failure rate in caudal epidural block in 1999. The common cause of failure was various anatomical variations in sacral hiatus. This route is frequently used in different therapeutic as well as diagnostic procedures in orthopaedics and anaesthesiology.

Shape of the sacral hiatus: The most commonly encountered shape of sacral hiatus is inverted 'U' shape. The percentage of distribution of shape of the sacral hiatus differs with other authors like Vishal K [12] and Nagar SK [18].

Position of the apex: The level of apex of sacral hiatus shows considerable variation which ranges from S2 to S5. In the present study, the commonest position of the apex is at S4 vertebra, which is same as described in the literature by authors like Senoglu etal [13] and Nagar SK [18].

Position of the base: The location of the base of sacral hiatus also shows variation which ranges from the lower end of S4 vertebra to the coccyx. In our study it is most commonly at the level of S5 vertebra. The findings of our study are more or less in agreement with findings of other authors namely Vishal K [12], Mohamed S [17] and Nagar SK [18].

Height of the apex: In the present study the mean height of the apex is 2.4 cm. Mrudula et al [19] recorded the height at 2.46cm. Agarwal et al [6] quoted the length as 4.3cm, Patil [16] as 3.41cm and Lakshmi et al [20] as 2.75cm.

Depth at the apex: The depth of sacral canal at the apex of is important because it helps in decision of accurate needle usage in caudal epidural block. In the present study mean depth at apex was 0.6 cm which was similar to the study done by Mrudula et al [19]. Aggarwal et al [6] quoted the depth as 0.3cm, Patil [16] S as 0.42cm and Mohamed S [17] as 0.48 cm.

Width at the base: In the present study the mean width at the base was 1.5 cm. Aggarwal et al [6] quoted the width as 1.19cm, Lakshmi et al [20] as 1.48 cm, Patil [16] as 1.37 cm and Mrudula et al [19] as 1.02cm.
Distance between two suprolateral crest: In the present study the mean distance between two superolateral crest is 6.4 cm. Senoglu et al [13] quoted the distance as 6.65 cm and Mrudula et al [19] as 5.65cm.
Distance between right superolateral crest & apex: In the present study the mean distance between right superolateral crest & apex is 6.8 cm. Senoglu et al [13] quoted the distance as 6.71 cm, Patil [16] as 6.19cm and Lakshmi et al [20] as 7.60cm.

Distance between left superolateral crest & apex: In the present study the mean distance between the left superolateral crest & apex is 6.7 cm. Senoglu et al [13] quoted the distance as 6.75 cm, and Mrudula et al [19] as 5.46 cm.

Distance between S2 vertebra & apex: In the present study the mean distance between S2 vertebra & apex is 4.3cm. Senoglu et al [13] quoted the distance as 3.54 cm, Patil [18] as 3.28 cm, Agarwal et al [6] as 7.25 cm and Mohamed S [17] as 4.1cm.

Conclusion:

Development of sacrum resembles the ossification of a typical vertebra. The secondary centres of ossification appear after puberty and all the sacral vertebra start fusing with each other. Any defect in the formation of primary centres will lead to incomplete formation of the sacral canal and incomplete ossification of the laminae [1]. In 7.7% of cases the Caudal epidural block fails due to the absence of sacral hiatus [4]. The different variation of shape and size of sacral hiatus should always kept in mind while giving caudal epidural anaesthesia and analgesia. As the apex of sacral hiatus is difficult to palpate the present study was done to locate the sacral hiatus precisely. Exact location of sacral hiatus in caudal epidural block determines its success rate.

References:

1) Susan S et al., Gray's Anatomy. The Anatomical basis of clinical practice, 39 Ed, Churchill Livingstone, London, 2005; p 749-50.
2) Letterman GS, Trotter M. Variations of male sacrum; their significance in caudal analgesia. Surg Gynaecol Obst, 1944; 78(5): 551-555.
3) Edward W.B. & Hingston R.A. Continuous caudal anesthesia in obstetrics. Am. J. Surt., 57; 459-64, 1942.
4) Sekiguchi M, Yabuki S & Kikuchi S. An anatomical study of the sacral hiatus; a basis for successful caudal epidural block pain. Clin.j, 20(1); 51-4, 2004.
5) Trotter M. & Lanier P.F. Hiatus canalis sacralis in American whites and Negroes. Hum, Biol, 17; 368-81, 1945.
6) Aggarwal A, Harjeet, Sahni D. Morphometry of sacral hiatus and its clinical relevance in caudal epidural block. Surgical and Radiological Anatomy. 31(10):739-800, 2009.
7) Moore K.L. & Dalley, A.F. Clinically oriented Anatomy. Lippincott Williams & Wilkins, 1995.
8) Soames, R. W. Skeletal system. In: Williams, P. L.; Bannister, L.H.; Gray's Anatomy. 40th Ed. Edinburgh Churchill Livingstone, 2008. Pp.528-31, 1430-31.
9) Waldman S.D. Caudal epidural nerve block: prone position. In. Atlas of interventional pain management. 2nd edition. Saunders, 2004. Pp.380-92.
10) Mehmet S, Johongir MM, Ali D. Evaluation of congenital lumbosacral malformations and Neurological findings in patients with low back pain, Turkish neurosurgery, 19(2):145-8, 2009.
11) Naveen NS, Muralimanju, Vishal K, Malagi AM. Craniorachischisis totalis. Journal of Neurosciences in rural practice, 1(1):54-5, 2010.
12) Vishal Kumar, Soubhagya, Bhagath kumar, Thejodhar, Sacral hiatus in relation to low backache pain in south Indian population. Bratisl Lek Listy 2009;110 (7): 436-441.
13) Senoglu N, Senoglu, M, Gumusalan Y, Yuksel KZ, Zencirci B. Landmarks of the sacral hiatus for caudal epidural block; An anatomical study . Br. J. Anaesth, 95(5); 692-5, 2005.
14) Patell MM, Gupta BD, Singel TC. Sexing of sacrum by sacral index & Kimura's base wing index, JIAFM; 27:0971-3, 2005.
15) Tsui BC, Tarkkila P, Gupta S, Kearney R. Confirmation of caudal needle placement using nerve stimulation. Anaesthesiology.1999 (2); 91:374-78.
16) Patil Dhananjay S, Jadav Hrishikesh R, Binodkumar, Patel Vipul D, Anatomical study of sacral hiatus for caudal epidural block. National journal of medical research 2(3), 2012.
17) Mohamed SM, Omayma, EI Raouf, Hosam. Morphometric study of Sacral hiatus in adult human Egyptian Sacra; Their significance in caudal epidural anesthesia. Saudi journal of Anaesthesia 2012; 6(4): 350-7.
18) Nagar SK. A study of sacral hiatus in dry human sacrum. J.Anat.Soc.India, 53(2): 18-21. 2004.
19) Mrudula C, Naveena S. Morphometry of Sacral hiatus and its clinical relevance. International journal of advance research, 1(7) 29-34, 2013.
20) Lakshmi AT, Azra J. Surgically relevant Morphometry of Sacral hiatus. Anatomica Karnataka 7 (1) 52-6, 2013.