VOLUME-6 | ISSUE-4 | APRIL - 2017 • ISSN No 2277 - 8179 | IF : 4.176 | IC Value : 78.46

"STUDY TO EVALUATE THE OUTCOME OF THE DISTAL FEMUR FRACTURES TREATED WITH LOCKING COMPRESSION PLATE USING MODIFIED SWASHBUCKLER APPROACH"

Orthopaedics

KEYWORDS: Distal femur fractures ; Modified swashbuckler approach; Locking compression plate; Neer's criteria

Kishore Raichandani	Professor and Head, Department of Orthopaedics, Dr. S. N. Medical College, Jodhpur
Sanjay Garhwal	PG Student Third year Department of Orthopaedics, Dr. S. N. Medical College, Jodhpur
Raunak Surana	PG Student Third year Department of Orthopaedics, Dr. S. N. Medical College, Jodhpur
Abhinav Bhardwaj	Senior Resident Department of Orthopaedics, Dr. S. N. Medical College, Jodhpur
Ashok Singhvi	Senior Specialist Department of Orthopaedics, Dr. S. N. Medical College, Jodhpur
Surbhi Raichandani	MBBS Intern Department of Orthopaedics, Dr. S. N. Medical College, Jodhpur

ABSTRACT

INTRODUCTION

The pattern of distal femur fractures is changing from simple extra-articular to intra- articular type. In high energy trauma, the problem of restoring the function in a destroyed knee joint persists. Modified swashbuckler approach provide excellent exposure of inter-condylar fractures which give easy reduction of condylar fractures and better functional outcomes.

MATERIAL AND METHODS

Between 2014 to 2016, we treated 40 patients of distal femur fractures with locking compression plate using modified swashbuckler approach. All patients were followed up for a minimum period of 12 months and evaluated using Neer s criteria.

RESULTS

34 patients (85%) showed radiological union within 16 weeks. 20% cases had post-operative complications which include superficial infection. At end of 12 months 75% cases had good or excellent results and 50% patients returned to their pre injury functional level.

CONCLUSION

Modified swashbuckler approach provide excellent exposure of intra-articular fractures and locking compression plate provide stable fixation through multiple points of fixed plate –to- screw contact.

INTRODUCTION

The incidence of distal femur fractures in indian population are increasing due to more road traffic accidents. There is two common mechanism of distal femur fractures. One most common is high velocity road traffic accidents and second is fall which common in osteoporotic elderly patients.

In high energy trauma , the problem of restoring the function in a destroyed knee joint persists. Complex knee ligament injuries frequently occur additionally to extensive cartilage injuries. In elderly patients , extreme osteoporosis represents a particular problem for anchoring the implant.

Varities of implants are used for fixation of distal femur fractures are fixed angle devices, usually in the form of dynamic condylar screw(DCS)1 system, is associated with complications like post-operative loss of reduction (varus collapse) and mal-alignment. Nailing(retrograde)2 in these fractures is associated with inaccurate articular reduction, mal-alignment , non- union , apart from knee stiffness.

Locking compression plate(LCP)3,4 provide multiple points of fixed plate to screw contact, which generates greater stability which reduces the tendency for varus collapse. Locking screws provide stronger fixation of the plate which creates a toggle free, fixed angle construct.

Various surgical approaches are present in literature to achieve an adequate exposure of the distal femoral fracture including, lateral/medial para-patellar approach5,6 ,swashbuckler approach7, tibial tubercal osteotomy8,9, combined medial and lateral approach10 . We used modified swashbuckler approach for distal femur fractures fixation with locking compression plate without primary bone grafting.

MATERIAL AND METHODS

In this study 40 patients with distal femur fractures were treated at tertiary care centre between july 2014 to july 2016 included in this prospective study. The method used for fracture fixation was open reduction and internal fixation with locking compression plate by swashbuckler approach. The duration of follow up ranged from 12 months to 24 months.

INCLUSION CRITERIA

1. Those patients who were above the age of 20 years and had fresh fracture lower end femur(AO classification A, B, C) ,Both closed and open (Gustilo grade 1&2) fractures were considered.

All patients were initially managed according to advanced trauma life support guidelines. The fractured limb was splinted with the application of skin traction. Patients with open injuries received immediate wound debridement and intravenous antibiotics started. After routine preoperative investigations patients were taken up for surgery. All the patients were operated within 7 days of injury.

Radiological assessment done by anteroposterior and lateral views of the injured limb including complete knee joint and distal femur with proximal leg. The AO/OTA classification was used to classify the fractures.

Operative procedure

All the patients were operated in the supine position on a radiolucent table. The modified swashbuckler approach6 (anterolateral) were used in the study. Eversion of the patella done and the limb is fully flexed which provide excellent exposure of condyles. Intra articular facture reduced first and hold with multiple k wires and reduction confirmed by using c-arm, then plate was applied on the lateral surface of the femur and multiple screws were inserted in the condyles through plate and then metaphyseal fragment fixed with condyles with the help of plate and screws .Knee mobilization exercises were started on second post operative day.

RESULTS

In our study 40 distal femur fractures were treated . All cases were fresh, 30 patients were males and 10 patients were females. The median age was 45.8 years ranging from 21 to 68 years. 75 % of the fractures were caused by the road traffic accidents and 25% were due to fall. 16 patients were with fracture on right side and 24 on the left side. Of the 40 lower end femur fractures , 8 were Mullers type A3; 4 were Mullers type B1; 12 were Mullers type C1; 8 were Mulles type C2; and remaining 8 were Mullers type C3.

16 patients had associated injuries. Of them , 2 patients had comminuted fracture of bilateral tibia. 2 patients had ipsi-lateral tibia fracture and 2 patients had fractures of the acetabulum along with contralateral tibia. 2 patients had contra-leteral tibia fracture. 4 patients had fracture distal end radius and 4 patients had fracture of patella ipsilateral side.

All patients were operated within 7 days of the injury. Average time duration of surgery was 94 minutes with shortest duration was 75 minutes and longest was 120 minutes. The size of plate was selected based on the type of fracture. 4 to 6 holed plate were used most commonly. Of the 40 patients ,34 patients(85%) showed radiological union within 16 weeks . 2 patients went for delayed union. Weight bearing allowed within 14 weeks in 70% patients. Infection was encounterd in 8 cases. They were early infections treated with saline wash, debridement and higher antibiotics. Average flexion in the study was 114 degree with more than 65% patients having knee range of motion more than 120 degree.

Average knee extensor lag in this study was 5.85 degree. Out of 40 patients , 6 had shortening, 4 of them of 15 mm and 2 had shortening of 10 mm. In this study , 10 patients had varus mal alignment, 8 patients had valgus mal-alignment less than 5 mm. In the study , 20 patients had no deterioration in work capacity .In the study , 20% patients developed infection which was superficial and controlled by serial debridement and higher antibiotics. In the study, NEER criteria3 was used for functional outcome. Out of 40 patients, 22 patients were achieved excellent results and 2 patients achieved poor results.

TABLE 1 COMPLICATIONS

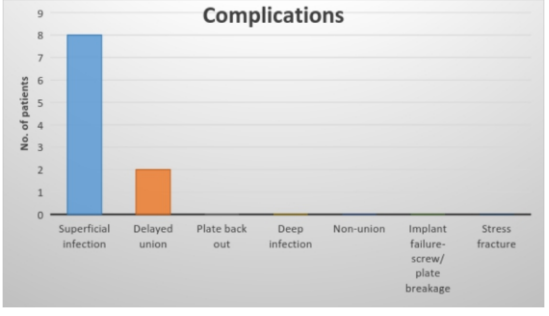

DISCUSSION

Distal femur fractures are challenging injuries for the orthopaedic surgeons. These injuries require extensive surgical management and aggressive knee mobilization because there is more chances of postoperative knee stiffness, mal-union, non-union, mal-alignment, secondary osteoarthritis.

There are many surgical approaches for exposure of the distal femur fractures which give good exposure of fractures. Lateral approach5,6 give limited exposure of the medial condyle and have complications like delayed wound healing, quadriceps scarring. With the use of modified "swashbuckler" approach7 we can get excellent exposure of condylar fractures, intra articular step- off because now a days, the pattern of distal femur fractures is changing from simple extra-articular to intra-articular type. Starr et al 9described a modified anterior "swashbuckler" approach7 to the distal femur.

Locking compression plate3 provides multiple points of fixed plate-to-screw contact, generating greater stability than is provided by a single lateral construct, which potentially reduces the tendency for varus collapse. The locking screws may also provide stronger fixation of the plate in the proximal fragment by eliminating any potential for toggle and sequential screw loosening. This could have particular advantage in the osteoporotic bones. Plate with locking screws function as internal fixators and have a biological advantage over conventional plates. The plate is not compressed against a cortex and therefore periosteal blood supply is preserved. Locking compression plate gives a stable fixation for distal femur fractures including severe osteoporosis, severe comminution. Locking plate provides sufficient torsional and axial stability.

Our study comprised of 40 patients with Distal end Femur Fractures who were treated by Locking Compression plate. Overall final outcome was assessed in terms of regaining the lost knee function using NEER'S Score11.

Comparing our results with standard studies, In a study by Schutz M, Muller M et al12. Internal fixation using the LISS was performed at an average of 5 days (range: 0-29 days) after the injury. 48 fractures were operated on within the first 24 hours. Revision operations were required for 2 cases of implant breakage. 4 cases of implant loosening and 7 debridments to deal with infections. The study showed clearly that when working with LISS, primary cancellous bone grafting was not necessary. The total follow up rate was 93%. 5% non union was observed. Our results are comparable to the study with similar rates of infection although no cases of implant breakages and non-union were seen. Since open reduction was done in all cases.

Kregor et al13 reported 93% union within 12 weeks without secondary bone grafting . While in our study union time (18 weeks) little longer than this study this may be with the fact that all our cases were treated with open reduction. Weight and Collinge14 observed 5% non-union in their study while in this study no case of non-union observed , 2 cases of delayed union observed in the open fractures so reason for delayed union could be open fractures. In a study by Zlowodzki et al15 observed deep infection in 2.1% cases while in this study no case of deep infection were observed , 8 (20%) cases had superficial infection which was higher than other studies, because these patients had compound fracture and relatively higher incidence of associated fractures. These cases were managed by serial debridement and higher antibiotics.

Yeap, E.J., and Deepak, A.S 16.conducted a retrospective review on eleven patients who were treated for Type A and C distal femoral fractures (based on AO classification) between January 2004 and December 2004. All fractures were fixed with titanium distal femoral locking compression plate. The patient's ages ranged from 15 to 85 with a mean of 44. Clinical assessment was conducted at least 6 months post-operatively using the Schatzker score system. Results showed that four patients had excellent results, four good, two fair and one failure. Anuj Agrawal et al17 observed mean knee flexion 120 degree in AO type C3 fractures with modified swashbuckler approach which is comparable to this study 114 degree of our study. Modified swashbuckler approach provides excellent exposure of condylar fractures and better functional outcome.

CONCLUSION

LCP gives the surgeon access to the entire range of options for internal fixation, from compression screw osteosynthesis with the principle of absolute stability to osteosynthesis with relative stability (bridge plating).

Our study shows a good to excellent functional outcome of distal femur fractures, fixed with a single lateral locking plate, using a modified swashbuckler approach.

REFERENCES

1. Zimmerman AJ. Intra-articular fractures of distal femur. OCNA, 10,pg.75-80, 1979/39

VOLUME-6 | ISSUE-4 | APRIL - 2017 • ISSN No 2277 - 8179 | IF : 4.176 | IC Value : 78.46

2. Iannacone WM, Bennett FS, Delong WG. Initial experience with the treatment of supracondylar femoral fractures using the supracondylar nail: A preliminary report. J Orthop Trauma, 8(4): Aug 1994
3. Ahmad M, Nanda R, Bajwa AS, Candal-Couto J, Green S, Hui AC. Biomechanical testing of locking compression plates: is distance between bone and implant significant? JBJS,88-B(III),401
4. Egol Kenneth A MD, Kubiak Erik N MD, Fulkerson Eric MD, Kummer Frederick J phD,Koval Kenneth J MD. Biomechanics of Lockied plates and screws
5. Krettek C, Schandelmaier P, Miclau T, Bertram R, Holmes W, Tscherne H. Trans-articular joint reconstruction and indirect plate osteosynthesis for complex distal supracondylar femoral fractures. Injury,1997;28(suppl 1): A31-41.[PubMed:10897285]
6. Schatzkar J. Fractures of distal femur revisited. Clin Orthop Related Res.1998;347:43-56
7. Starr AJ, Jones AL, Reinert CM. The swashbuckler ; A modified anterior approach for fractures of distal femur . J Orthop Trauma. 1999;13:138-40.[PubMed:10052790]
8. Olerud S. Operative treatment of supracondylar –condylar fractures of the femur. Technique and results in fifteen cases. J Bone Joint Surg Am.1972;54:1015-32
9. Khalil AE,Ayoub MA. Highly unstable complex C3- type distal femur fractures : Can double plating via a modified Olerud extensile approach be a standby solution? J Orthop Traumatol. 2012;13:179-88
10. Lin D, Chen C, Lian K , Zhai W. Treatment of type C3.3 distal femoral fractures with double plating fixation via U- shaped incision. Zhonggou Xiu Fu Chong Jian Wai Ke Za Zhi. 2014;24:683-6.
11. Neer CS, Grantham SA, Shelton ML. Supracondylar fractures of adult femur. J Bone Joint Surg Am 1967;49(4):591-613.
12. Schutz M, Muller M, Regazzoni P, Hontzsch D, Krettek C, Van der werken C, et al Use of less invasive stabilization system(LISS) in patients with distal femoral (AO33) fractures: a prospective multicentre study. Arch Orthop Trauma Surg 2005;125(2):102-8.
13. Kregor PJ, Stannard JA, Zlowodzki M, Cole PA. Treatment of distal femur fractures using the less invasive stabilization system: surgical experience and early clinical results in 103 fractures. J Orthop Trauma 2004;18(8):509-20.
14. Weight M, Collinge C. Early results of the less invasive stabilization system for mechanically unstable fractures of the distal femur(AO/OTA types A2, A3, C2, and C3). J Orthop Trauma 2004;18:503-8
15. Zlowodzki M, Bhandari M, Marek DJ, Cole PA, Kregor PJ. Operative treatment of acute distal femur fractures; systemic review of 2 comparative studies and 45 case series (1989-2005). J Orthop Trauma 2006;20:366-71.
16. Yeap EJ, Deepak AS. Distal femoral locking compression plate fixation in distal femoral fractures: early results. Malasian Orthop J 2007;1(1):12-7.
17. Anuj Agrawal et al. Indian J Orthop. 2017 jan-feb; 51(1):18-27