ORIGINAL RESEARCH PAPER

Volume-7 | Issue-10 | October-2018 | PRINT ISSN No 2277 - 8179

INTERNATIONAL JOURNAL OF SCIENTIFIC RESEARCH

SUCCEESSFUL MANAGEMENT OF UTERINE AV MALFORMATION WITH BILATERAL UTERINE ARTERY EMBOLIZATION---A CASE REPORT

Gynaecology

Dr. V. Sumathy Director(Retired), Institute of Social Obstetrics & Govt. KG Hospital, Chennai

Dr. Shilpa reddy * Consultant, Obstetrics & Gyanecology, Chennai. *Corresponding Author

S.Padmanaban Research Scientist B HRRC ICMR, Chennai.

ABSTRACT

Uterine arteriovenous malformation (AVM) is defined as abnormal and nonfunctional connections between the uterine arteries and veins. Although the patients typically present with vaginal bleeding, some patients may experience life-threatening massive bleeding in some circumstances. The treatment of choice depends on the symptoms, age, desire for future fertility, and localization and size of the lesion; however, embolization of the uterine artery is the first choice in symptomatic AVM in patients at reproductive age with expectations of future fertility. We report a case of acquired AVM (after D/C) with an extensive lesion, which was successfully treated with bilateral uterine artery embolization (UAE).

KEYWORDS

1. INTRODUCTION

Uterine arteriovenous malformation (AVM) is defined as abnormal and nonfunctional connections between the uterine arteries and veins. These can be either congenital or acquired lesions (traumatic) lesions. Congenital AVMs are extremely rare conditions, whereas the incidence rate of acquired AVMs is currently increasing [1–3]. Acquired AVMs are often associated with previous uterine surgery (dilation and curettage (D/C)), therapeutic abortion, cervix or endometrial cancer, trophoblastic diseases, and direct uterine trauma and occur more frequently in women at reproductive age [4]. Typical symptom is vaginal bleeding; however, some patients may present with life-threatening massive bleeding.

We report a case of acquired AVM (after D/C) with an extensive lesion, which was successfully treated with UAE.

2. Case

A 34-year old patient, gravida 3, para 1, live 1 abortion 1, underwent Dilatation and curettage at another hospitalat seven weeks of gestational age due to heavy bleeding PV for one week and ultrasound finding of RPOC.1Following the D&C the patient had spotting PV for about 5-6 days which was followed by heavy bleeding PV associated with clots for about 2 weeks .The patient was admitted to our casuality for this complaint: Her past obstetric history revealed one induced abortion for which suction evacuation done for missed abortion at 7 weeks of gestational age.She underwent one full term Elective LSCS at 38 weeks of gestational age that resulted in a healthy live term boy baby weighing 2.8 kg. There had been no intrapartum /postpartum complications during that pregnancy.The present pregnancy was confirmed by a urine pregnancy test at 45 days of amenorrhoea.On admission to the casuality her vitals were stable.Pelvic examination revealed a bulky uterus and the cervical os was closed.Therewas minimal bleeding through the os.Her admission HB was 5 gm% in view of which she was given blood transfusion.

An USG of the pelvis showed the anterior myometrium to be inhomogenous with both arterial and venous vascularity.The endometrial thickness at the fundus was 6 mm.There was minimal fluid collection in the endometrial cavity. The adnexa bilaterally appeared normal.

The lower segment of the uterus was distended with multiple flow voids suggestive of sn Arteriovenous malformation..An MRI was done to improve the diagnostic precision and it showed a heterogenous anterior uterine wall with a T2 hypointense area and there was loos of endomyometrial differentiation at the junctional zone signifying an Arteriovenous malformation (figure 1)

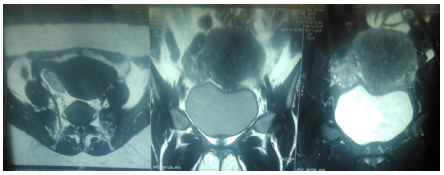

FIGURE 1 coronal Section Of The Pelvis Demonstrating T2 Hypointense Area With Multiple Flow Voids Signifying An Av Malformation

A consultation with an interventional radiologist was performed and the patient was scheduled for UAE. Bilateral Uterine artery embolization was performed using gel foam (figure 2)

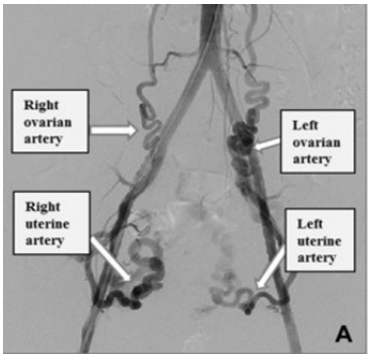

FIGURE 2 – Preembolisatiodistribution Of Right And Left Uterine Artery ,right And Left Ovarian Artery

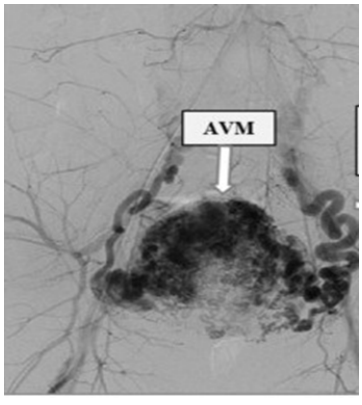

FIGURE 3--- Illustration Of Av Malformation With Feeding Vessels From Both Uterine Arteries

No complications occurred after the procedure. The patient was discharged 5 days after the procedure; Control Doppler USG performed one month later and revealed no blood flow in the lesion and showed a significant shrinkage in size .The patient is currently under follow up and is doing well

DISCUSSION

Uterine AVMs have an important place in gynecology practice due to risk of massive bleeding that could be life threatening in some patients. These can be either congenital or acquired (traumatic) lesions. Acquired malformations may be due to previous uterine trauma (prior pelvic operation and curettage), pathologic pregnancy-related

conditions, infections, and the treatment of gestational trophoblastic disease. Congenital AVMs are considered to arise from arrested vascular embryologic development resulting in anomalous differentiation in the capillaries and abnormal communication, between arteries and veins [1). Moreover, congenital AVMs can have multiple vascular connections and may invade surrounding structures. It is important to diagnose uterine AVM correctly and to start appropriate treatment promptly, because uterine AVM often causes life-threatening massive and persistent vaginal bleeding.

Peitsidis and colleagues reported a large review of all reported cases of acquired AVM after D&C (Peitsidiset al., 2011). In total there were 91 studies totaling 103 patients (1954 – 2011). Among these, 95 women reported having a curettage procedure prior to onset of their symptoms. The mean age of diagnosis was 30 years with 96% being premenopausal.

Acquired uterine AVMs a rare but a potentially serious disorder which typically occurs in reproductive aged women following spontaneous or therapeutic abortion. How trauma from curettage enhances this process is unknown but it may involve a reactive immune response when the endometrium is agitated. Increased myometrial vascular endothelial growth factor, angiogenesis and revascularizа- tion have been observed in women who received hysteroscopy for the treatment of Asherman's syndrome (Chen et al., 2013). It has been pro- posed that endometrial agitation can incite a local immune response, and activate inflammatory cytokines leading to transient changes of the endo-myometrial biologySevere acute bleeding is the most common presentation often requiring hysterectomy.

The present case developed uterine AVM in a short time secondary to past uterine trauma (Dilatation and curettage)In today's practice, AVM is easily diagnosed using color Doppler ultrasonography [2). But, in differential diagnosis, retained products of conception (RPOC) and gestational trophoblastic diseases (GTD) should be kept in mind because these cases may also give a hypervascular appearance with turbulent flow. BHCG levels may be helpful in diagnosis. However, placental site trophoblastic tumor (PSTT) does not produce high levels of hCG and instead produces human placental lactogen (hPL) [3)

The treatment changes depending on the age, desire for future fertility, localization, and size of the lesion. The mainstay for management of uterine AVM has been hysterectomy or the embolization of uterine arteries. However, the uterine artery embolization (UAE) remains the first choice of treatment in women at reproductive age having expectation of future fertility (4). Whether this procedure is safe for women desiring future fertility is controversial; however, women who become pregnant after UAE are at risk of malpresentation, caesarean delivery, preterm birth, and postpartum hemorrhage (5)

UAE for AVM was first reported in 1982 by Forssmanet al. (1982). The mechanism of UAE for the treatment of AVM may be similar to its effects on uterine fibroids. Burbank proposed that the stasis of the blood flow caused by UAE induces clot formation within the uterus. Fibrinolysis occurs in normal myometrial vasculature followed by reperfusion. Fibroids, which lack fibrinolytic pathways, cannot reperfuse and there- fore die (Burbank, 2004). AVM, which are neovascular masses may also lack proper fibrinolytic pathways leading to ongoing clot, stasis and eventual regression.

CONCLUSION

AVMs are rare and dangerous clinical entities; their management is complicated and necessitates a high level of suspicion. Usually, these lesions are present in young women, with a previous history of spontaneous abortions. It must be kept in mind that patients may develop AVM following evacuation of uterus for pregnancy loss and the possibility of AVM must be considered in differential diagnosis.

REFERENCES

1. T. Ghi, S. Giunchi, C. Rossi et al., "Three-dimensional power Doppler sonography in the diagnosis of arteriovenous malformation of the uterus," Journal of Ultrasound in Medicine, vol. 24, no. 5, pp. 727–731, 2005.
2. A. Gillespie and B. Hancock, "Placental site trophoblastic tumour," in Gestational Trophoblastic Disease, B. Hancock, M. Seckl, R. Berkowitz, and L. Cole, Eds., 3rd edition, pp. 420–429, International Society for the Study of Trophoblastic Diseases, 2009.
3. S. Soeda, H. Kyozuka, S. Suzuki, S. Yasuda, Y. Nomura, and K. Fujimori, "Uterine artery embolization for uterine arteriovenous malformation is associated with placental abnormalities in the subsequent pregnancy: two cases report," Fukushima Journal of Medical Science, vol. 60, no. 1, pp. 86–90, 2014.
4. J. Goldberg, L. Pereira, and V. Berghella, "Pregnancy after uterine artery embolization," Obstetrics and Gynecology, vol. 100, no. 5, pp. 869–872, 2002.
5. T. Van den Bosch, D. Van Schoubroeck, C. Lu, J. De Brabanter, S. Van Huffel, and D. Timmerman, "Color Doppler and gray-scale ultrasound evaluation of the postpartum uterus," Ultrasound in Obstetrics and Gynecology, vol. 20, no. 6, pp. 586–591, 2002.