ORIGINAL RESEARCH PAPER

Volume-7 | Issue-10 | October-2018 | PRINT ISSN No 2277 - 8179

INTERNATIONAL JOURNAL OF SCIENTIFIC RESEARCH

SUCCESSFUL MANAGEMENT OF A CORNUAL PREGNANCY WITH UTERINE ARTERY EMBOLIZATION

Gynaecology

Dr.V.Sumathy Director(Retired), Institute of Social Obstetrics & Govt. KG Hospital, Chennai

Dr. Shilpa Reddy* Consultant, Obstetrics & Gyanecology, Chennai.*Corresponding Author

S. Padmanaban Research Scientist B HRRC ICMR, Chennai.

ABSTRACT

Interstitial/Cornual ectopic pregnancy is a rare condition of pregnancy and may be very dangerous if not identified and treated urgently. We report a case of successful treatment of an interstitial pregnancy using selective uterine artery embolization. A 27-year-old woman with interstitial pregnancy was treated by uterine artery embolization after failure of systemic methotrexate treatment. Her serum beta-human chorionic gonadotropin (β-hCG) was undetectable 10 weeks after the therapeutic embolization and transvaginal sonography 3 months after embolization showed normal endometrium and cornu. The patient achieved a normal pregnancy one year after embolization.

KEYWORDS

Pregnancy, Ectopic; Uterus, Angiography; Uterus, Interventional Procedures

INTRODUCTION

Interstitial pregnancy is defined as any gestation that develops in the uterine portion of the fallopian tubes lateral to the round ligament. Interstitial pregnancies account for 2-4% of all ectopic pregnancies and have been reported to have an associated 2% to 2.5% maternal mortality rate (1).

The traditional treatment for interstitial pregnancy using surgical cornual resection may cause infertility or uterine rupture in subsequent pregnancies. Recently, the early identification of intact interstitial pregnancy has been made possible in many cases with high resolution transvaginal ultrasound as well as more sensitive assays for beta-human chorionic gonadotropin (β-hCG). The treatment includes: hysteroscopictranscervicalcurrettage, local and systemic methotrexate (MTX) therapy and prostaglandin or potassium chloride injection of the ectopic mass under sonographic guidance (2).

We describe a case of successful treatment of interstitial pregnancy using uterine artery embolization, after failure of methotrexate treatment.

CASE REPORT

A 24-year-old woman, gravida 2, para 1,live1 was referred to the gynecology department at our institution with a history of 10 weeks amenorrhea,right sided abdominal pain and slight vaginal bleeding of 5 daysduration.She had confirmed her pregnancy by a home urine pregnancy test at 45 days of amenorrhea but hadn't registered her pregnancy yet.

Her menses had been regular, every 28-30 days. The patient had no history of pelvic inflammatory disease, intrauterine device use, abdominal surgery, or treatment for induction of ovulation. Her obstetrical history was significant for a normal delivery.Upon examination in the delivery room the patient's vital signs were stable and the general physical examination was unremarkable.

P/A ;Soft no organomegaly
No localised tenderness.
P/V- Uterus was anteverted,bulky
cervical os closed

There was mild tenderness felt in the right fornix
Transvaginal sonogram;demonstrated the presence of a gestational sac (5.5×5 cm in diameter) with irregular decidual reaction at the right cornual end which raised suspicion for an interstitial pregnancy (Fig 1).

FIG1(A)
FIG. 1

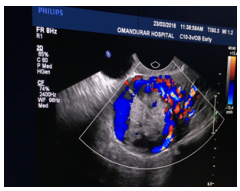

FIG 1(B)

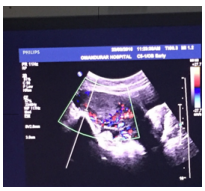

In view of haemodynamic stability and unruptured ectopic gestation the patient was subjected to medical management with methotrexate on alternate days along with leucovorin .

Repeat scan after 3 doses of Inj Methotrexate showed no decrease in the either the size of the gestational sac or the degree of vascularity.

DAY - 1	INJ METHOTREXATE 50 MG IM
DAY 2	T .LEUCOVORIN
	Patient under careful observation
	-Patient was stable
DAY 3	INJ METHOTREXATE 50 MG IM
DAY 4	T.LEUCOVORINB HCG - 29432
DAY 5	INJ METHOTREXATE
DAY 6	LEUCOVORN Serum B hcg - 27121 miu/ml
DAY 7	INJ METHOTREXATE 50 MG IM
DAY 8	T.LEUCOVORIN B HCG- 23951
DAY 12	Serum B HCG –19422

MRI PELVIS

Fig 3 a-Sagittal section fig 4 a-Coronal section
Hyperechoic lesion of size 5*4 cm with multiple flow voids in the region of right cornua suggestive of cornual pregnancy

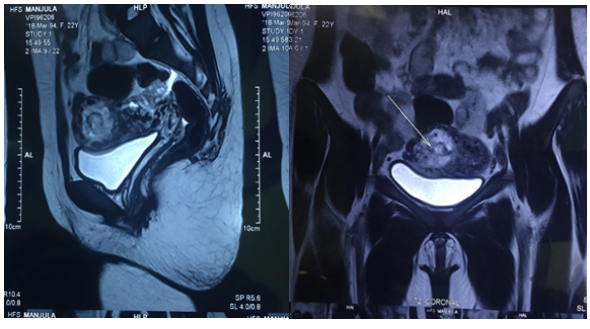

If the MTX therapy is successful, the β-hCG level is expected to drop immediately. However, the serum β-hCG levels were in an increasing trend despite methotrexate treatment. We decided to attempt surgical treatment. However, the patient wanted to avoid surgical intervention. We decided to proceed with uterine artery embolization.

In the angiography room, under local anesthesia, a 5-Fr catheter was advanced through the sheath introducer inserted from the right common femoral artery and was positioned in the right internal iliac artery. Next, a 2.8-Fr microcatheter was coaxially advanced into the right uterine artery from the 5-Fr catheter with use of a microguidewire; selective uterine arteriography was performed and showed increased vascularity in the cornualregion(Fig 3) The microcatheter was then further advanced into the ascending portion of uterine artery. Embolization was achieved using PVA particles of 500-710 µm until a standing column of contrast was obtained; this signified the occlusion of the ascending portion of the

uterine artery with a preserved cervicovaginal branch. The left internal iliac artery was selected, and the same technique was used to embolize the left uterine artery; embolic material was used with gelfoam.

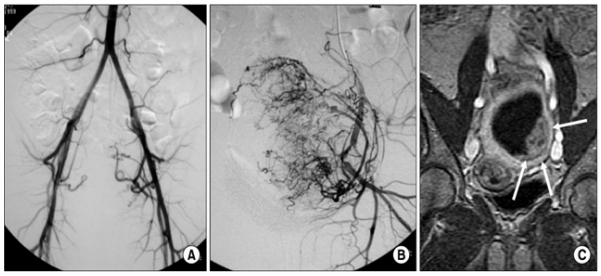

FIG 3

The serum β-hCG level decreased to 21,149 mIU/mL on the second day and 2,627 mIU/mL on the fifth day after the procedure. The patient had no complications such as pain, fever or infection. The patient was discharged in good condition 2 weeks after the procedure. The serum β-hCG level decreased to 223 mIU/mL 11 days later and was undetectable 10 weeks after the procedure.

Ultrasonography examination demonstrated a collapsed gestational sac with a normal endometrial stripe three months after the procedure. The patient had an unremarkable gynecologic examination. Spontaneous menstruation occurred 12 weeks after the procedure. One year afterembolizaton, the patient was pregnant. Transabdominal ultrasonography demonstrated an intrauterine gestation sac with a fetal heart beat.

DISCUSSION

Interstitial pregnancy is a rare form of ectopic pregnancy and has a maternal mortality rate as high as 2% to 3%, which is twice that of other tubal gestations (1).

The exact pathogenesis of this type of gestation is unknown; however, it is thought to be associated with abnormal transportation of the fertilized ovum within the fallopian tube. Similar to other ectopic pregnancies, risk factors include: a history of pelvic inflammatory disease, intrauterine device and previous tubal surgery. In particular, patients with ipsilateral salpingectomy or cornualreanastomosis appear to have specific risk for interstitial pregnancies (3).

Cornual resection by laparotomy or via laparoscopy have been used for treatment of interstitial pregnancies may cause problems of reduced fertility by blocking the cornu or subsequent pregnancy related uterine rupture resulting from weakening the uterine wall. Vascular supply of the interstitial area is particularly rich and the gestational sac of interstitial pregnancy is in a highly vascular area, near the anastomosis of the uterine and ovarian vessels. A surgical procedure, in the interstitial area, may result in a catastrophic hemorrhage. For this reason, other surgical treatments such as: laparoscopy guided transcervical curettage, laparoscopic cornuostomy, hysteroscopic gestational sac removal as well as medical treatments such as: local or systemic methotrexate therapy, prostaglandin or potassium chloride injection of the ectopic mass under sonographic or laparoscopic guidance have been used for treatment (4, 5). MTX therapy has become a popular approach for treatment of ectopic pregnancy; however, drug toxicity (dermatitis, alopecia areata, vomiting), hemorrhage necessitating emergency surgery and potential risk of rupture of ectopic pregnancy are serious associated complications.

Uterine artery embolization is a procedure becoming increasingly popular in obstetrics or gynecologic used for bleeding, uterine myoma and in uterine vascular malformations. It can be used as an alternative method for surgical treatment or in association with surgery to prevent major bleeding.

Recently Ophir et al. (6) and Deruelle et al. (7) have described successful treatment of interstitial ectopic pregnancy by selective uterine artery embolization without any serious complications. The uterine cornu area is a highly vascular region near the anastomosis of the uterine and ovarian vessels; however, the majority of the vascular supply in the cornu area is from the uterine artery. Therefore, the block of blood flow in the uterine artery may decrease vascularization of a pregnancy, leading to trophoblastic degeneration affecting placental function and fetal growth. In our case, we used PVA particles at the lesional side for a more compact vascular block, and used gelfoam, which is a temporary occlusion of vessels for two to six weeks, at the contralateral side for blocking only the retrograde collateral blood supply. These previously reported cases, as well as ours, demonstrate that selective uterine artery embolization could be a safe and effective treatment for the conservative management of interstitial ectopic pregnancy.

The effect of the embolization on menses and subsequent pregnancies remains unclear; however, there have been many cases reported of successful pregnancy after uterine fibroid embolization (8-10); Deruelle et al. (9) reported a subsequent pregnancy after uterine artery embolization in a patient with an interstitial ectopic pregnancy. In addition, Tropeano et al. (10) reported that the use of uterine fibroid embolization in women younger than 40 had no definite change on the ovarian reserve. In our case, eight months after the, uterine artery embolization (UAE) a subsequent pregnancy was achieved; thus the successful outcome of our case suggests that this procedure may preserve fertility in cases with early detection of unruptured interstitial pregnancy.

The other possible complications after UAE are pain, groin hematoma, uterine necrosis and pelvic infection such as tuboovarian abscess and endometritis; our case, had no complications after the procedure.

In conclusion, selective uterine artery embolization for interstitial ectopic pregnancy is a safe and effective alternative to surgical treatment and may preserve future fertility.

REFERENCES

1. Rock JA, Damario MA. Ectopic pregnancy. In: Rock JA, Thompson JD, editors. TeLinde's operative gynecology. 8th ed. Philadelphia: Lippincott-Raven; 1997. pp. 505–520.
2. Oelsner G, Admon D, Shalev E, Shalev Y, Kukia E, Mashiach S. A new approach for the treatment of interstitial pregnancy. FertilSteril. 1993;59:924–925.
3. Advincula AP, Senapati S. Interstitial pregnancy. FertilSteril. 2004;82:1660–1661.
4. Zhang X, Liu X, Fan H. Interstitial pregnancy and transcervical curettage. Obstet Gynecol. 2004;104:1193–1195.
5. Katz DL, Barrett JP, Sanfilippo JS, Badway DM. Combined hysteroscopy and laparoscopy in treatment of interstitial pregnancy. Am J Obstet Gynecol. 2003; 188:1113–1114.
6. Ophir E, Singer-Jordan J, Oettinger M, Odeh M, Tendler R, Feldman Y, et al. Uterine artery embolization for management of interstitial twin ectopic pregnancy: case report. Hum Reprod. 2004;19:1774–1777.
7. Deruelle P, Lucot JP, Lions C, Robert Y. Management of interstitial pregnancy using selective uterine artery embolization. Obstet Gynecol. 2005;106:1165–1167.
8. Walker WJ, Pelage JP. Uterine artery embolisation for symptomatic fibroids: clinical results in 400 women with imaging follow up. BJOG. 2002;109:1262–1272.
9. DeruelleP, Closset E. Management of interstitial pregnancy using selective uterine artery embolization. Obstet Gynecol. 2006;107:427–428.
10. Tropeano G, Di Stasi C, Litwicka K, Romano D, Draisci G, Mancuso S. Uterine artery embolization for fibroids does not have adverse effects on ovarian reserve in regularly clycling women younger than 40 years. FertilSteril. 2004;81:1055–1061