ORIGINAL RESEARCH PAPER

Volume-7 | Issue-2 | February-2018 | PRINT ISSN No 2277 - 8179

INTERNATIONAL JOURNAL OF SCIENTIFIC RESEARCH

SUPRASCAPULAR NERVE NEUROPATHY SECONDARY TO SPINOGLENOID NOTCH GANGLION CYST: A RARE PRESENTATION

Orthopaedics

Nirav Soni* Junior Resident, Dept. of Orthopaedics, SMIMER, Surat *Corresponding Author

Shalin Shah Junior Resident, Dept. of Orthopaedics, SMIMER, Surat

Raj Parmar Junior Resident, Dept. of Orthopaedics, SMIMER, Surat

Nikhil Vachharajani Professor, Dept. of Orthopaedics, SMIMER, Surat

ABSTRACT

Suprascapular Nerve Neuropathy Secondary to Spinoglenoid Notch Ganglion Cyst is a rare presentation in shoulder pathology. We present a 35 year old male patient who presented with shoulder pain and weakness since 5 months. Examination revealed unilateral infraspinatus muscle atrophy in the back.

Magnetic resonance imaging showed ganglionic cyst in the spinoglenoid notch without labral tear which it is usually associated with, a rare presentation. The Patient failed conservative management with physiotherapy and underwent open surgery for cyst excision. The patient experienced resolution of symptoms within 6 months of surgery. With appropriate treatment, suprascapular nerve neuropathy secondary to ganglion cyst impingement is a treatable condition with potentially good results

KEYWORDS

Case:



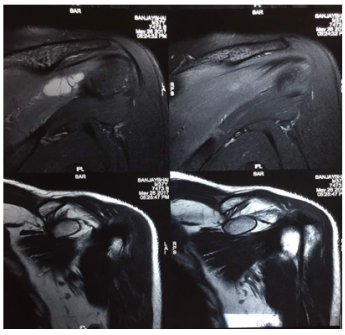

Fig. 1 Obvious atrophy of infraspinatus muscles on the weaker side

A 37 year old man who presented to SMIMER hospital orthopaedic department with Complaint of Left shoulder weakness and pain since around 6 months. The patient complained of diffuse pain over poster lateral aspect of shoulder. Patient had no history of any significant trauma.

Clinical examination revealed obvious atrophy of infraspinatus muscles on the weaker side with around muscle strength of 3/ 5 on external rotation against resistance.

No visible wasting of supraspinatus muscle
Examination revealed adequate functioning of Supraspinatus muscle

INVESTIGATION: MRI showed evidence of spinoglenoid cystic swelling. However there was no associated labral tear. MRI findings showed a T2 intense signal in the spinoglenoid region suggestive of spinoglenoid notch cyst.[6]

INTERVENTION & OUTCOME: The patient underwent planned surgery and exposure of the involved area followed by identification of the cyst at spinoglenoid notch whose excision was done. No recurrence of the cystic lesion was noted on follow-up 12 months postoperatively. Shoulder external rotation strength was graded as 5 of 5.

Introduction:

Shoulder pain and dysfunction: Common causes include local conditions such as Rotator cuff tears, Impingement syndromes, Tendonitis, Bursitis, Adhesive capsulitis, Acromioclavicular joint osteoarthritis, as well as cervical pathology such as Cervical disc disease and spondylosis. [12]

Suprascapular nerve neuropathy has increasingly been found to be a cause of shoulder pain[2,3] and dysfunction, especially with the advent of magnetic resonance imaging (MRI) and its use in evaluating shoulder pathology.[6] It used to be missed previously because of all shoulder pain, only 1-2% is caused by entrapment With appropriate treatment, it has been shown that this is a treatable condition with potentially good results.[2,3] This is a rare diagnosis, frequently missed clinically and is usually associated with labral tears which is absent here[4]

Suprascapular nerve is a motor nerve that arises from the upper trunk of the brachial plexus formed by the C5 and C6 roots, occasionally also receives a contribution from the C4 root. The nerve passes laterally across the posterior cervical triangle to reach the scapular notch. The nerve travels in close proximity to the posterior border of the clavicle. It innervates supraspinatus, infraspinatus muscles.[13,14,9]

Suprascapular ligament Arises from medial base of coracoid and overlies suprascapular notch suprascapular artery runs above, suprascapular nerve runs below

Spinoglenoid ligament Arises near spinoglenoid notch and overlies distal suprascapular nerve

Suprascapular Notch entrapment	Spinoglenoid notch entrapment
Proximal compression of suprascapular nerve in the suprascapular notch	Distal compression of suprascapular nerve
Leads to weakness of both supraspinatus and infraspinatus	Affects infraspinatus only
Physical exam Pain with palpation of suprascapular notch Weakness of supraspinatus Weakness seen with shoulder abduction to 90 degree, 30 degrees forward flexion, and with internal rotation (Jobe test positive) Weakness of infraspinatus Weakness to external rotation with elbow at side atrophy along the posterior scapula	Physical exam Infraspinatus weakness weakness to external rotation with elbow at side Infraspinatus atrophy along the posterior scapula supraspinatus strength is normal

MRI as an investigation is gold standard in diagnosing as well as confirming amongst the differential.

Discussion:

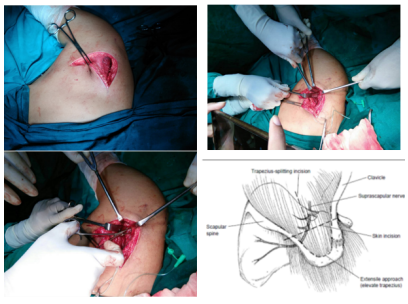

Decompression of the suprascapular nerve at the suprascapular notch is best achieved through a trapezius-splitting approach. Prone Position is used. Operation was performed using trapezius splitting transverse incision posterior approach described by AA Romeo et al. [11]

1. A transverse skin incision parallel to the scapular spine was used
2. The trapezius is divided in line with its fibers for a distance of 5 cm, with additional relaxation of the fibers achieved by abducting the arm. The trapezius was then elevated off the scapular spine for an extensile exposure.
3. The supraspinatus muscle is retracted posteriorly to provide access to the suprascapular notch.
4. The suprascapular notch is identified, retracted with a small right-angle clamp to protect the suprascapular nerve. The transverse scapular ligament is transected after gentle retraction of the overlying suprascapular artery and vein. The cyst was identified and excised en-bloc
5. The suprascapular nerve still tethered within the boundaries of the suprascapular notch, additional resection of the medial aspect of the suprascapular notch was performed
6. The detached trapezius was then sutured to bone. The split trapezius fibers were reapproximated with absorbable suture. Closure was done in layers.

Histopathological Examination report confirmed MRI finding of Ganglionic cyst.

Conclusion

The patient underwent planned surgery and exposure of the involved area followed by identification of the cyst at spinoglenoid notch with excision was done. Therefore we concluded that the protrusion of ganglionic cyst into spinoglenoid notch causing compression over suprascapular nerve, which might be the cause of pain and weakness. Consequently the shoulder pain was relieved without any complications and the cyst was histologically diagnosed as a ganglionic cyst. This case demonstrated that ganglion at spinoglenoid notch was the cause of suprascapular entrapment syndrome. Ganglions usually cause isolated infraspinatus atrophy, whereas a combined atrophy of the supra- and infraspinatus muscles is more common in cases in which the nerve is compressed by the ligament. Open excision gives good result and the spinous process approach provides good exposure in an isolated case of suprascapular neuropathy without labral tear if the cosmetic appearance of the following scar is forgone.

References:

1. Yao K, Yew WP. Suprascapular nerve injury: A cause to consider in shoulder pain and dysfunction. Journal of back and musculoskeletal rehabilitation. 2017 Jan 1;30(1):39-44.
2. Callahan JD, Scully TB, Shapiro SA, Worth RM. Suprascapular nerve entrapment: a series of 27 cases. Journal of neurosurgery. 1991 Jun;74(6):893-6.
3. Hadley MN, Sonntag VK, Pittman HW. Suprascapular nerve entrapment. A summary of seven cases. Pain. 1987 Jul 1;30(1):134.
4. Piatt BE, Hawkins RJ, Fritz RC, Ho CP, Wolf E, Schickendantz M. Clinical evaluation and treatment of spinoglenoid notch ganglion cysts. Journal of shoulder and elbow surgery. 2002 Dec 31;11(6):600-4.
5. Post M, Grinblat E. Suprascapular nerve entrapment: diagnosis and results of treatment. Journal of shoulder and elbow surgery. 1993 Jul 1;2(4):190-7.
6. Fritz RC, Helms CA, Steinbach LS, Genant HK. Suprascapular nerve entrapment: evaluation with MR imaging. Radiology. 1992 Feb;182(2):437-44.
7. Lichtenberg S, Magosch P, Habermeyer P. Compression of the suprascapular nerve by a ganglion cyst of the spinoglenoid notch: the arthroscopic solution. Knee Surgery, Sports Traumatology, Arthroscopy. 2004 Jan 1;12(1):72-9.
8. Shupeck M, Onofrio BM. An anterior approach for decompression of the suprascapular nerve. Journal of neurosurgery. 1990 Jul;73(1):53-6.
9. Rockwood CA. The shoulder. Elsevier Health Sciences; 2009.
10. Kim JR, Wang SI. Suprascapular nerve entrapment caused by an intraosseous ganglion of the scapula: A case report. Medicine. 2017 Jun 1;96(24):e7167.
11. Romeo AA, Rotenberg DD, Bach Jr BR. Suprascapular neuropathy. Journal of the American Academy of Orthopaedic Surgeons. 1999 Nov 1;7(6):358-67.
12. Kopell HP, Thompson WA. Pain and the frozen shoulder. Surgery, gynecology & obstetrics. 1959 Jul;109(1):92-6.
13. Mallon WJ, Bronec PR, Spinner RJ, Levin LS: Suprascapular neuropathy after distal clavicle excision. ClinOrthop 1996;329:207-211.
14. Post M, Mayer J: Suprascapular nerve entrapment: Diagnosis and treatment. Clin Orthop 1987;223:126-136.