ORIGINAL RESEARCH PAPER

Volume-8 | Issue-5 | May-2019 | PRINT ISSN No 2277 - 8179

INTERNATIONAL JOURNAL OF SCIENTIFIC RESEARCH

SURGICAL MANAGEMENT OF A HETEROTOPIC CAESAREAN SECTION SCAR ECTOPIC

Gynaecology

Deanne Vagg	Department of Gynaecology, Royal Women's Hospital, Parkville, Melbourne, Victoria, Australia
Ricardo Palma-Dias*	Department of Ultrasound, Royal Women's Hospital, Parkville, Melbourne, Victoria *Corresponding Author
Lima Arsala	Department of Gynaecology, Royal Women's Hospital, Parkville, Melbourne, Victoria, Australia
Althea Askern	Department of Gynaecology, Royal Women's Hospital, Parkville, Melbourne, Victoria, Australia
Ruth Cameron-Jeffs	Department of Gynaecology, Royal Women's Hospital, Parkville, Melbourne, Victoria, Australia
Edward O'Mahony	Department of Ultrasound, Royal Women's Hospital, Parkville, Melbourne, Victoria
Salwan Al-Salihi	Department of Gynaecology, Royal Women's Hospital, Parkville, Melbourne, Victoria, Australia

ABSTRACT

Current trends of advanced maternal age, increased uptake of assisted reproductive technologies (ART), and rising caesarean section rates have resulted in higher incidences of heterotopic pregnancy, specifically caesarean section pregnancy (CSP). Despite the rarity of the diagnosis, when encountered in clinical practice, it presents a diagnostic and management dilemma. We report a rare case of a spontaneous dichorionic-diamniotic (DCDA) pregnancy, with a heterotopic CSP, and one intrauterine pregnancy at 7 weeks gestation. The CSP was treated with ultrasound guided potassium chloride (KCl) injection with the view of continuing with the intrauterine pregnancy. Despite achieving asystole in the CSP, follow-up ultrasound 10 days post procedure revealed an enlarging CSP trophoblastic ring with surrounding haematoma. The risk of uterine rupture was deemed too high at this stage to avoid further operative management, and a laparoscopic excision of the caesarean scar ectopic was undertaken, with surgical termination of the live intrauterine pregnancy using suction dilatation and curettage.

KEYWORDS

Heterotopic pregnancy, caesarean scar ectopic, transvaginal ultrasound, ectopic pregnancy

Introduction

Heterotopic pregnancy describes a concurrent intrauterine and extrauterine ectopic pregnancy[1]. It is a rare diagnosis, with an incidence estimated to be 1 in 30,000 spontaneous pregnancies[2]. In pregnancies conceived using assisted reproductive therapies, the incidence increases to 1 in 3900[3]. Furthermore, CSP is also uncommon, occurring in less than 1 in 2000 pregnancies in women with previous caesarean delivery[4,5].

There is limited evidence to guide management of heterotopic pregnancy. Medical treatment involves using localised or systemic methotrexate, while surgical encompasses procedures to remove the pregnancy tissue such as uterine wedge resection or hysterectomy. A recent study by Ramkrishna et al[6] has shown that the use of intra sac KCl and methotrexate is a successful intervention for management of non-tubal ectopic pregnancies, especially in those women wishing to preserve fertility. Clearly, medical management is appropriate only in clinically stable cases[7]. Surgical management is otherwise required[7].

Case Description

A 35 year old, gravida 2, para 1 women presented to hospital with vaginal bleeding and pelvic pain at 6 weeks gestation. This pregnancy was planned and spontaneously conceived. Her past obstetric history was of an emergency caesarean section at a term gestation two years prior. She was clinically well and underwent a transabdominal and transvaginal ultrasound that diagnosed a probable early dichorionic-diamniotic (DCDA) pregnancy.

Repeat ultrasound at 7 weeks gestation demonstrated a live heterotopic DCDA pregnancy, with one gestational sac developing in the caesarean scar, and the other pregnancy was developing within the uterine cavity.

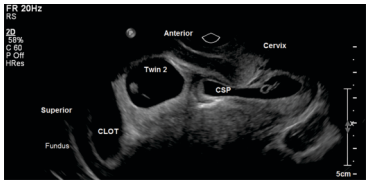

Figure 1 Sagittal view of the cervix and uterus demonstrating fundal clot, twin 2 intrauterine pregnancy and the Caesarean scar pregnancy.



Figure 2 Sagittal view of the cervix and lower uterus demonstrating, cervical canal and CSP distending anterior uterine serosa at the level of the Caesarean scar. The volume of the CSP had increased subsequent to the KCl injection procedure.

Initial management options that were considered included termination of the entire pregnancy with intra-sac and systemic methotrexate, termination of the CSP using ultrasound guided intra-sac KCl, with expectant management of the IUP, or expectant management with inpatient observation and ultrasound guidance. The unpredictable nature of this pregnancy, with risks of severe haemorrhage, morbidity

and mortality, was conveyed to the patient, however she initially preferred to preserve the intrauterine pregnancy and decided to proceed with intra-sac KCl to the CSP.

Figure 2 shows the pre-intervention ultrasound. Using a 20-gauge needle, 2mL (30mmol/mL) intra-sac KCl was injected into the CSP using a trans-placental entry. Asystole of the CSP was observed.

Repeat trans-vaginal ultrasound ten days post selective reduction of the CSP revealed that the trophoblastic ring of the CSP had enlarged in size, with the trophoblast covered by serosa only and no visible embryo. The large portion of the haematoma described previously, was seen to be bypassing the CSP and reaching the internal os. Twin 2 remained live, now at a growth consistent with 9 weeks plus 1 day. Given the ongoing expansion of the CSP trophoblast and the potential risk of future uterine rupture with growth of the intrauterine pregnancy, the patient was counselled to proceed with surgical treatment.

On the seventeenth day of the patient's admission, the fourteenth day post elective KCl injection operative laparoscopy was performed to excise the CSP. After precise and delicate surgical entry onto the utero-vesical space and reflection of the bladder peritonium, diathermy was used to create surgical plane proximal to the bulging CSP and a wedge resection was made to remove the CSP using toothed graspers and suction. The defect was then closed in layers using delayed absorbable sutures. No excision of myometrium was required. A cervical dilatation and suction curettage was performed under laparoscopic vision to remove the IUP. Blood loss was moderate due to the vascularity of the gravid uterus however the patient remained stable post operatively and did not require a red cell transfusion. She was discharged home 3 days later and over the following 5 weeks her beta HCG was tracked down to zero.

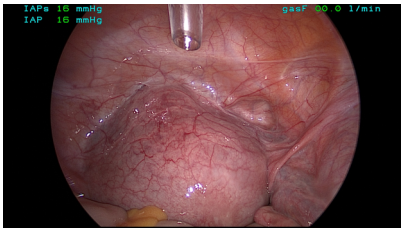

Figure 4 Uterovesical pouch concealing the CSP.

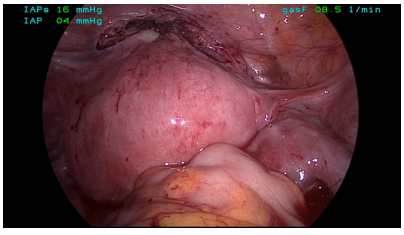

Figure 5 surgical dissections exploring the CSP.

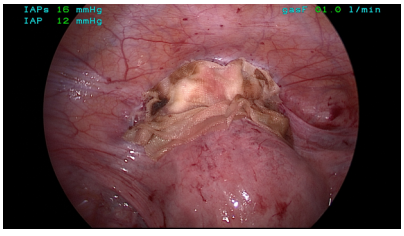

Figure 6 following the surgical removal of the CSP with applied absorbable adhesive barrier.

Discussion

CSP in heterotopic pregnancy is a rare diagnosis. The number of previous caesarean section deliveries is not correlated to the likelihood in developing CSP according to Kirk et al[15]. There is a lack of evidence to recommend an ideal management approach and this makes clinical decision making difficult and non-uniform. These cases are clearly challenging to clinicians and distressing for patients. Therefore, multidisciplinary input particularly from experts in ultrasound and advanced gynaecological surgery is essential to effective and safe management of these complex cases.

Multidisciplinary input from senior clinicians, including sub-speciality experts in laparoscopic surgery and gynaecological ultrasound were involved in this patients care, with frequent and in depth clinical meetings occurring in which this case was discussed and options for management explored. The decision ultimately to proceed with surgical management was challenging, as we respected our patient's desires to conserve the intrauterine pregnancy and had explored all conservative management options. Due to the persistent expansion of the ectopic sac, it was felt that on balance, surgical intervention was required to prevent uterine rupture and the resultant significant maternal morbidity.

A review of the literature demonstrates less than 30 published cases of CSP and concurrent intrauterine pregnancy. Salomon et al[8] described the first case of a heterotopic caesarean scar pregnancy successfully treated with KCl in the first trimester, with the patient having a 36 week emergency caesarean section for premature rupture of membranes. There are two reported cases in the literature describing successful intrauterine pregnancy outcome after surgical management of the CSP. Demirel et al[9] described a case of a heterotopic caesarean scar pregnancy managed with laparoscopic removal of the ectopic mass. They opted for surgical removal of the placental tissue and repair of the myometrium in light of the risks of weakening the lower uterine segment with use of medical management when coexisting with an intrauterine pregnancy[9]. The intrauterine pregnancy continued without complication, with a healthy baby born at 38 weeks gestation via caesarean section[9]. The other reported case in the literature also describes successful outcomes for the intrauterine pregnancy after surgical excision of the CSP with utilisation of laparotomy as their surgical method of choice[10]. Gupta et al [16] in a case report described suction aspiration as the therapeutic choice in their patient who wanted to a successful pregnancy outcome and was also keen to preserve her fertility.

Accordingly, management of heterotopic pregnancy can be medical or surgical. Minimally invasive approaches, such as ultrasound guided intra-sac injection of methotrexate have been shown to be associated with high rates of pregnancy termination, without rupture, which may be especially useful in women wishing to preserve fertility[6]. However this management option is not always appropriate for use in cases of heterotopic pregnancy due to the adverse effects on the intrauterine pregnancy. Cases of heterotopic pregnancies with implantation in the caesarean scar are rare, with most heterotopic ectopic pregnancies occurring in the tube. In the more common scenario of the heterotopic pregnancy involving a tubal ectopic, surgical management via salpingectomy is most favourable, as surgical termination of the extrauterine pregnancy can occur, while preserving the intrauterine pregnancy[13]. Yet from the reports discussed here, consideration of other modalities are beneficial when the extrauterine pregnancies are in unusual locations not easily amenable to surgical intervention, and which may predispose to uterine rupture, such as at the caesarean scar.
Conservative management of CSP is also an option for consideration in certain isolated cases, however it is often not a clinically preferred option due to the risks of uterine rupture. A recent study by Timor-Tritsch et al[14] determined that both placental implantation in CSP and early (second-trimester) placenta accreta share common histopathological features, likely representing different stages in the continuum leading to morbidly adherent placenta in the third trimester. These conditions all implant over the previous caesarean scar and can result in serious obstetric complications[14].

Most heterotopic pregnancies are diagnosed at 5 to 8 weeks gestation, however there are reported cases of diagnosis as late as 35 weeks gestation[11]. Delayed diagnosis and management of heterotopic pregnancies can be associated with significant maternal morbidity and mortality, and endanger the intrauterine pregnancy. Commonly, the imaging modality of choice for diagnosis of heterotopic pregnancy is transvaginal ultrasonography. Recent literature has concluded that early transvaginal ultrasound performed by an experienced clinician, is associated with a sensitivity of 92.4% and a specificity of 100% for detection of heterotopic pregnancy[12].

This case contributes to the literature regarding the management of CSP as a heterotopic pregnancy. Ultrasound guided intra-sac KCl may be considered for selective reduction of a CSP when preservation of a coexisting intrauterine pregnancy is desired. However this case demonstrates the need to offer surgical management for those who have failed non-surgical management. Early diagnosis of heterotopic pregnancy is essential to improve the possibility of preserving the intrauterine pregnancy and reduce maternal morbidity and mortality,

and transvaginal ultrasound adds to diagnostic accuracy. Clearly, with increasing prevalence of advanced maternal age, increased uptake of ART and rising caesarean section rates, clinicians may encounter more cases of heterotopic and CSP. Diagnosis and management of these complex cases should be individualised with appropriate counselling and careful assessment of the patient and a multidisciplinary approach.

Authors' Note

The patient's consent was obtained for publication of this case report.

Declaration of Conflicting Interests

The author(s) declared no potential conflicts on interest with respect to the research, authorship and/or publication of this article.

Funding

The author(s) received no financial support for this research, authorship, and/or publication of this article.

REFERENCES

1. Govindarajan MJ and Rajan R. Heterotopic pregnancy in natural conception. Journal of Human Reproductive Sciences. 2008; 1(1):37–38.
2. Glassner MJ, Aron E, Eskin BA. Ovulation induced with clomiphene and the rise of heterotopic pregnancies: A report of two cases. J Reprod Med. 1990; 35:175-8
3. Farnaghi S, Kothari A. Heterotopic pregnancy: a report of two cases. Australasian Journal of Ultrasound in Medicine. 2015; 16(1):30-36.
4. Jurkovic D, Hillaby K, Woelfer B, Lawrence A, Salim R and Elson CJ. First-trimester diagnosis and management of pregnancies implanted into the lower uterine segment Cesarean section scar. Ultrasound Obstet Gynecol 2003; 21, 220–227.
5. Seow KM, Cheng WC, Chuang J, Lee C, Tsai YL and Hwang JL. Methotrexate for Caesarian scar pregnancy after in vitro fertilization and embryo transfer. A case report. J Reprod Med 2000; 45, 754–757.
6. Ramkrishna J, Kan GR, Reidy KL, Ang WC, Palma-Dias R. Comparison of management regimens following ultrasound diagnosis of nontubal ectopic pregnancies: a retrospective cohort study. BJOG 2017; https://doi.org/10.1111/1471-0528.14752
7. Fatema, N, Al Badi MM, Rahman M, Elawdy MM. Heterotopic pregnancy with natural conception; a rare event that is still being misdiagnosed: a case report. Clinical Case Reports. 2016; 4(3): 272-275.
8. Salomon LJ, Fernandez H, Chauveaud A, Doumerc S and Frydman R. Successful management of a heterotopic caesarean scar pregnancy: potassium chloride injection with preservation of the intrauterine gestation: case report. Hum Reprod 2003; 18, 189–191.
9. Demirel LC, Bodur H, Selam B, Lembet A, Ergin T. Laparoscopic management of heterotopic cesarean scar pregnancy with preservation of intrauterine gestation and delivery at term: case report. Fertil Steril. 2009; 91 (4): 1293
10. Armbrust R, Kratschell R, Henrich W, David M. Operative therapy for heterotopic scar pregnancy and successful birth of the intrauterine foetus - case report and review of the literature. Geburtshilfe Frauenheilkd. 2015;75(4): 384–8.
11. Talbot K, Simpson R, Price N, Jackson SR. Heterotopic pregnancy. J Obstet Gynaecol. 2011; 31:7-12.
12. Li XH, Ouyang Y, Lu GX. Value of transvaginal sonography in diagnosing heterotopic pregnancy after in-vitro fertilization with embryo transfer. Ultrasound Obset Gynecol. 2013;41: 563-569.
13. Wang C, Chen C, Wang H, Chiueh H, Soong Y. Successful management of heterotopic caesarean section scar pregnancy combined with intrauterine pregnancy after in vitro fertilisation-embryo transfer. Fertil Steril. 2007;88:13-16.
14. Timor-Tritsch I. E, Khatib N, Monteagudo A, Ramos J, Berg R, and Kovács, S. Cesarean Scar Pregnancies. Journal of Ultrasound in Medicine, 2015; 34: 601-610.
15. Kirk E, Condous G, Bourne T. e non-surgical management of ectopic pregnancy. Ultrasound Obstet Gynecol 2006; 27(1): 91-100. Review.
16. Gupta R, Vaikousi E, Whitlow B (2010). Heterotopic caesarean section scar pregnancy. Journal of Obstetrics and Gynaecology, 30:6, 626-627, DOL:10.3109/01443615.2010.491565.