ORIGINAL RESEARCH PAPER
Volume-8 | Issue-9 | September - 2019 | PRINT ISSN No. 2277 - 8179 | DOI : 10.36106/ijsr
INTERNATIONAL JOURNAL OF SCIENTIFIC RESEARCH

SURGICAL MANAGEMENT OF DENTIGEROUS CYST OF MAXILLARY REGION IN A NON-SYNDROMIC PATIENT – A CASE REPORT

Dental Science

Dr Divya Subramanyam* Assistant Professor, Department of pedodontics, Asan Memorial Dental College and Hospital Chennai -600118 *Corresponding Author

ABSTRACT

Aim: The aim of this article is to report a case of maxillary dentigerous cysts in a non-syndromic patient and its Surgical management. Background: Dentigerous cyst is the most common type of inflammatory cysts of the jaw, which presents as swellings of jaws and midface. It is frequently associated with an impacted teeth.Clinical complications such as dental displacement, ectopic eruption, dental impaction, adjacent tooth root resorption, cortical expansion with facial asymmetry, paresthesia, pathological fracture, and even malignant transformation may occur. Most common treatment for dentigerous cyst is intraoral enucleation; however, extraoral removal is required in rare cases. Case Description: In this case report, we report a case of dentigerous cyst at maxillary region, in a 11-year-old female patient which was treated surgically by enucleation of the cyst. Clinical Significance: Since cysts can attain considerable size with minimal or no symptoms, early detection and removal of the cysts is important to reduce morbidity.

KEYWORDS

Dentigerous cyst, Enucleation, Maxilla, Permanent tooth, Case report

INTRODUCTION:

Dentigerous cyst is the most common developmental odontogenic cysts of the jaws, approximately 20-24% of all the epithelium-lined jaw cysts which develops around the fully-formed crown of an unerupted tooth.[1] It frequently occurs in individuals between 20 to 40 years of age. Dentigerous cysts usually remain asymptomatic and are usually diagnosed incidentally during the routine radiological examination. Rarely, these cysts get secondarily infected and patient presents with symptoms such as swelling and pain.[2] Radiographically, the cyst appears as ovoid well-demarcated unilocular radiolucency with a sclerotic border.[3] Histologically, it is composed of a thin connective tissue wall with a thin layer of stratified squamous epithelium lining. The exact pathogenesis of dentigerous cyst is not known, but most authors believe that dentigerous cyst is of a developmental origin from tooth follicles of unerupted teeth.[4] This case report shows a case of dentigerous cyst at maxillary region, in a 11-year-old female patient.

Case Report:

An 11-year-old female reported to the clinic, with chief complaint of a painless swelling in the left side of the upper jaw for a duration of 8 months. At the time of his presenting, the patient had no systemic disease. There was no history of trauma to the maxillary anterior region. Intraoral clinical examination revealed a firm, diffused, non-tender swelling extending from maxillary left permanent canine to maxillary left first premolar region extending into the left maxillary buccal vestibule. The premolars were unerupted. The overlying mucosa was firm in consistency, tender on palpation. The overlying mucosa was red with signs of inflammation, without any discharge. (Figure 1) On radiographic examination, it showed a thin sclerotic border surrounding the well-defined unilocular radiolucent area that was associated with the root of a maxillary left central incisor and permanent maxillary left lateral incisor. The contents of the swelling were aspirated and sent for investigations; the result of which was consistent with the diagnosis of a cystic lesion. After clinical and radiological examination, a provisional diagnosis of dentigerous cyst was made. Study was ethically conducted in accordance with Declaration of Helsinki.Prior to surgery, routine blood and urine examination were carried out; the results were within normal limits. Surgical enucleation of the cyst was the treatment of choice. The treatment consisted of extraction of the root stump of maxillary left deciduous canine, along with total enucleation of the dentigerous cyst. (Figure 2) The surgery was done using local anesthesia (Dentocaine 2% Pharma Health Care Product, Mumbai) and under antibiotic cover. The cyst was attached to the cementoenamel junction of maxillary left permanent lateral incisor. The cyst cavity was sterilized with sterile iodoform gauze to achieve hemostasis and to prevent hematoma formation and sutures were placed with 3-0 BBS suture (Figure 3). The patient was recalled after two weeks and the sutures were removed after two weeks. The specimen was sent for histopathological examination. The histological examination showed a thin fibrous cystic wall lined by a 2 to 3 layer thick nonkeratinized stratified squamous epithelium, with islands of odontogenic epithelium. The connective tissue showed a slight inflammatory cell infiltrate, which confirmed the diagnosis of dentigerous cyst. The patient was asked to return for clinical and radiographic follow-up once a month and careful monitoring is required. After 3 months, the patient was absolutely normal and there was no recurrence of the cyst.

Figure 1- Pre operative Occlusal photograph



Figure 2- Enucleation of the cyst

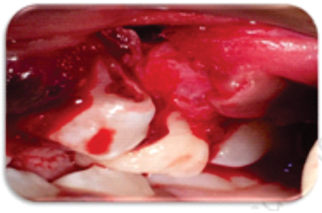

Figure 3- Post Operative photograph



DISCUSSION:

About 9% of dentigerous and 1% of radicular cysts occur in the first decade of life (Shear), while according to Donath, about 4% of dentigerous and less than 1% of radicular cysts appear in this life period.[5] The etiology of supernumerary teeth is unknown. Some authors in the literature has shown that cyst develop from a third tooth bud arising from the dental lamina near the permanent tooth bud or probably from splitting of the permanent tooth bud itself.[6] These lesions can also be found in children and adolescents and show a male predilection. In the present case report, the dentigerous cyst was associated with the maxillary right second premolar and left canine in a 10-year-old male child.

The exact histology of the dentigerous cyst is unknown. Dentigerous cyst develops around the crown of an unerupted tooth by accumulation

of fluid either between the reduced enamel epithelium and enamel or in between the layers of the enamel organ.[7] This fluid accumulation occurs as a result of the pressure exerted by an erupting tooth on an impacted follicle, which obstructs the venous outflow and thereby induces rapid transudation of serum across the capillary wall. A possible origin is related to an inflammatory process, resulting in proliferation of the reduced enamel epithelium that affects the developing tooth.[8] The correlation between dentigerous cysts, trauma in the deciduous teeth and crowns of the successor teeth has been reported.[9] In this case, the impact force of trauma of the primary incisor could have led to odontogenesis disturbances on the successor permanent tooth.[10] The substantial majority of dentigerous cysts involve the mandibular third molar and the maxillary permanent canine, followed by the mandibular premolars, maxillary third molars and rarely the maxillary premolars.[11] Studies have shown that the incidence rate of dentigerous cysts involving the maxillary premolar was 2.7% as compared to 45.7% involving the mandibular third molar.
The treatment of dentigerous cyst is by marsupialization or enucleation. Enucleation is a method that endeavour to relieve intracystic pressure through the creation of an accessory cavity.[12] This technique was selected as it is more conservative for the treatment of large cysts, considering the proximity of the cyst wall to the developing permanent tooth bud, especially in pediatric dentistry.

Clinical Significance:
Since cysts can attain considerable size with minimal or no symptoms, early detection and removal of the cysts is important to reduce morbidity.

Acknowledgement: Authors would like to thank parents and colleagues for their guidance and support.

Declaration of patient consent:
The authors certify that they have obtained all appropriate patient consent forms. In the form, the patient has given his consent for his images and other clinical information to be reported in the journal. The patient understand that name and initials will not be published and due efforts will be made to conceal identity, but anonymity cannot be guaranteed.

REFERENCES:

1. Kalaskar R R, Tiku A, Damle S G. Dentigerous cysts of anterior maxilla in a young child: A case report. J Indian Soc Pedod Prev Dent 2007; 25:187-90
2. Aziz SR, Pulse C, Dourmas MA, Roser SM. Inferior alveolar nerve paresthesia associated with a mandibular dentigerous cyst. J Oral Maxillofac Surg 2002; 60:457-9.
3. Buyukkurt MC, Aras MH, Caglaroglu M. Extraoral removal of a transmigrant mandibular canine associated with a detigerous cyst. Quintessence Int 2008; 39:767-70.
4. Jasvir Kaur, Neeraj Mahajan, Amanpreet Singh, Deepika Kapoor. Dentigerous cyst: a case report in a 5-year-old child. International Journal of Contemporary Medical Research 2016;3(8):2461-2462.
5. Regezi JA. Cyst and cystlike lesions. In: Regezi JA, Sciubba J, Pogrel MA, editors. Atlas of Oral and Maxillofacial Pahtology.
6. Lustmann J, Bodner L. Dentigerous cysts associated with supernumerary teeth. Int J Oral Maxillofac Surg 1988; 17:100-2.
7. Neville BW, Damm DD, Allen CM, Bonquot JE, Odontogenic cysts and tumors. Oral and Maxillofacial pathology. 2 nd ed. Philadelphia. P.A.: W.B. Saunders; 2005. p. 591-2.
8. Benn A, Altini M. Dentigerous cyst of inflammatory origin: A clinicopathological study. Oral Surg Oral Med Oral Pathol Oral Radiol Endod. 1996; 81: 203-209. 18.
9. Naclério H, Simões WA, Zindel D, Chilvarquer I, Aparecida TA. Dentigerous cyst associated with an upper permanent central incisor: case report and literature review. J Clin Pediatr Dent. 2003; 26: 187-192.
10. Bodner L, Woldenberg Y, Bar-Ziv J. Radiographic features of large cysts lesions of the jaws in children. Pediatr Radiol 2003; 33:3-6.
11. Toller PA. Origin and growth of cysts of the jaws. Ann R Coll Surg Engl 1967; 40:306-36.
12. Motamedi MH, Talesh KT. Management of extensive dentigerous cyst. Br Dent J 2005; 198:203-6.