ORIGINAL RESEARCH PAPER

Volume-8 | Issue-1 | January-2019 | PRINT ISSN No 2277 - 8179

INTERNATIONAL JOURNAL OF SCIENTIFIC RESEARCH

# SURGICAL TREATMENT OF DISTAL END CLAVICLE TYPE 2 FRACTURE USING COMBINATION OF LOCKING ANATOMICAL PLATE WITH K WIRES- SHORT TERM OUTCOME ANALYSIS

Orthopaedics

**Dr Himanshu D Shah** Assistant Professor, Orthopaedics, Government Medical College, Vadodara, Gujarat.-390019.

## ABSTRACT

**Background:** Lateral end clavicle fractures contribute to 25% of all clavicle fractures. Type II fractures are potentially unstable injuries. These fractures are associated with complications if not fixed anatomically and rigidly.

**Method:** we used combination of k wires with locking anatomical plate for fixation of lateral end of clavicle which provided excellent intraoperative stability.

**Results:** excellent functional outcome was noted in our study without any significant complications. All patients had union of fractures without significant complications during minimum follow up period of one year.

**Conclusion:** Combining locking plate with k wire provides more rigid fixation required for type II lateral end clavicle union without secondary procedures in our study.

## KEYWORDS

### INTRODUCTION:

Fractures of clavicle are common injuries accounting for around 3% of all fractures with estimated incidence of 29 per one lakh population (1, 2). Out of all clavicle fractures, 25% of fractures are of lateral end of clavicle (2). Neer has classified lateral end clavicle fractures into three types with type one being stable and undisplaced fractures, type 2 is unstable fractures with coracoclavicular ligament damage and type 3 contributes to unstable fractures with intra articular extension into acromio clavicular joint (3). High rate of non-union, approximately 30%, is noted in the literature in conservatively treated fractures (3, 4, 5). With many surgical options like k wires, tension band wiring, hook plate used till now, there is no gold standard treatment recommendation for this type of injury (6). The operative modalities are not without complications like implant failure, pin migration, non-union, and revision surgery (2). In this study, we have analysed outcome of the fixation of the type 2 lateral end clavicle fractures using combination of k wires and locked anatomical plate.

### MATERIAL AND METHOD:

Fourteen patients with closed unilateral type 2 lateral end clavicle fractures were admitted in the hospital during January 2017 to October 2017. All patients were subjected to surgical management after routine preoperative analysis. All patients were operated in supine beach chair position with pillow in interscapular region. Incision was kept on superior surface of distal end clavicle for adequate exposure. After soft tissue dissection, fracture fragments were cleared of hematoma. Anatomical reduction was performed using reduction forceps. The fracture site was fixed by two k wires inserted from acromion to distal fragment across fracture site with bicortical insertion into proximal fragment. Appropriate length anatomical locking plate designed for distal clavicle fracture was kept as per geometry and provisionally fixed with k wires. The plate was fixed to distal end using locking cortical screws of 2.7mm. Proximal fragment was fixed using 3.5mm locking cortical screws. Each screws length was checked under IITV. The stability of the fracture was assessed by hooking the proximal fragment by bone hook. Surgical wound was closed in layers. All patients were allowed active shoulder mobilization as per pain tolerance after 2 weeks. After suture removal, all patients were followed up to every 4 weeks at least for 1 year follow up for radiological and functional outcome.

### RESULTS:

Out of fourteen patients, ten were males and four were females. Eleven patients had history of road traffic accident and three patients had history of fall on outstretched home by self. Two patients had abrasions over fracture site so admission surgery interval was five days for those two patients to allow healing of abrasion. Rest all patients were operated at an average of two days of admission surgery interval. Average age of presentation in our study was 30.5 years. Nine patients had fracture on left side whereas rest patients had fracture on right side. The average operating time was 83 minutes. There was no significant complication noted in any patient. The average hospital stay duration was 3.5 days. The mean VAS score was 7 on the first postoperative day which reduced to one at 2weeks postoperatively. There were no cases of non-union or secondary procedure in any patients. The mean union time was 14 weeks. The mean DASH score at the end of one year follow up was 4.2. The average Constant Murley score was 93 at one year follow up. The functional outcome was excellent in ten patients and good in four patients. One patient reported k wire backout at 1 month postoperative period but the fracture fixation remained stable and eventually fracture united. All patients' k wire were removed under local anaesthesia after 3 months postoperatively. Twelve out of fourteen patients noted palpable implant but no incidence of exposed plate was noted. One case of superficial infection noted which was healed by oral antibiotics for ten days. All patients' k wire sites were healed within 7-10 days of k wire removal.

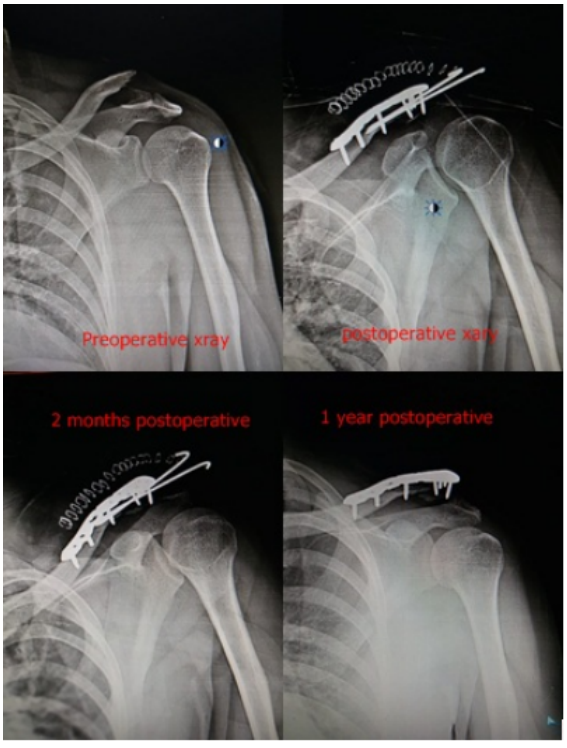


### DISCUSSION:

Clavicle fracture is one of the most common long bone fractures in adult population. Out of all clavicle fractures, lateral end of clavicle represent 25%. As the distal fragment is small and deforming forces are high, there are high chances of implant failure with non-union. The deforming forces are due to the pull of muscles along with the presence

of the coracoclavicular ligament and the weight of the arm. So stable anatomical fixation is required to regain normal shoulder function especially in type II lateral clavicle fractures.

There are many modalities of treatment in treatment of lateral end clavicle fractures. These include k wire, tension band wiring, hook plating and locking anatomical plate. We have used combination of anatomical plate with k wire fixation to achieve more stable anatomical fixation. Precontoured locking anatomical plates allow multiple locking cortical screws in different directions. So it provides greater stability of fracture and allows union in anatomical position. K wire provides additional stability at fracture site till initial phases of union. Using this plating technique, there are less complications reported like fixation failures, iatrogenic rotator cuff injury, subacromial impingement.

Kalamaras et al concluded that locking lateral end clavicle plate gave superior results (7). High union rates, less complications and excellent functional outcome have been reported by Anderson et al using the locking plating for lateral end clavicle fractures (2, 7). In this study, we also have achieved excellent outcome at minimum of one year follow up without any significant complications.

Samba dam Et al reported that for bony union to occur both the fracture ends must be kept opposed. To counter the distractive forces, two surgical principles can be done together. Both the fragments can be fixed internally and to fix the acromion along with them to give rigid fixation in such unstable type II fractures (6). The same principles were applied in our study. Removal of k wires after 3 months prevented arthritis of A C joint.

Early fracture fixation has less complication than late fracture fixation as reported by Klein et al. We also operated patients as early as was feasible (2, 7).

In 2007, Canadian orthopaedic trauma society has concluded that excellent results can be obtained by locking plate fixation for lateral end clavicle fractures (2).

In conclusion, locking anatomical plate is excellent fracture fixation method for lateral end clavicle.

In combination with k wires, which gives initial splintage effect to the fracture, locking anatomical plate can be used as gold standard fixation method without any significant complication as in our study.

## REFERENCES


1. Soha Sajid et al. locking plates for displaced fractures of the lateral end of clavicle: potential pitfalls. Int J Shoulder Surg. 2012 oct-dec; 6(4): 126-129.
2. Raju Vaishya et al. Outcome of distal end clavicle fractures treated with locking plates. Chinese Journal of Traumatology. 2017 (20): 45-48.
3. Laxman R. Et al. Modified tension Band For displaced type 2 lateral end clavicle fractures. Int Orthopaedics (SICOT) 2012; 36: 1417-22.
4. Richard s. Page, Deepak Bhatia. Noncomminuted lateral end clavicle fractures associated with coracoclavicular ligament disruption: technical consideration for optimal anatomic fixation and stability. Int J Shoulder Surg. 2014; 8(3): 86-89.
5. Peter Kenyon et al. Open reduction and fixation of displaced lateral clavicle fractures using the Minimally Invasive Acromioclavicular Joint Reconstruction technique: a case series review. Shoulder and Elbow 2015; 7(1): 13-17.
6. Sambandam B. Et al. Fracture of Distal end clavicle: a review. Journal of Clinical Orthopaedics andTrauma. 2014 (5):65-73.
7. Kapil Mani KC et al. Precontoured clavicular locking plate with broad lateral end: a newly designed plate for lateral third clavicle fractures. Malaysian Orthopaedic Journal 2018; 12 (1): 15-20.