ORIGINAL RESEARCH PAPER

Volume-8 | Issue-1 | January-2019 | PRINT ISSN No 2277 - 8179

INTERNATIONAL JOURNAL OF SCIENTIFIC RESEARCH

SYNOVIAL CHONDROMATOSIS OF ANKLE AND IT'S ARTHROSCOPIC MANAGEMENT: A CASE REPORT AND REVIEW OF LITERATURE

Orthopaedics

Saurabh Dutt* MS, Senior Resident, Sports Injury Centre, Vardhmann Mahaveer Medical College, New Delhi *Corresponding Author

Deepak joshi MS, Associate Professor And Specialist, Sports Injury Centre Vardhmaan Mahaveer Medical College, New Delhi

Vinod Kumar MS, DNB, MNAMS Director Professor, Maulana Azad Medical College, New Delhi

ABSTRACT

Background – Synovial chondromatosis is a disease characterized by cartilaginous metaplasia originating from synovial membrane of joints, bursae or sheaths of the tendons. It is mostly seen in knee and hip joints and is rarely seen in the ankle joint. Traditionally, treatment has been open surgery with excision of loose bodies and synovectomy. We present a case report of arthroscopic treatment of synovial chondromatosis of the ankle.

Presentation of the case – A 27 years old male patient was evaluated for persistent pain and swelling of his left ankle joint which increased post exertion. The patient was third year resident in the surgery department and his work included prolonged standing that exacerbated his condition. Based on clinical and radiological findings, he was diagnosed with synovial chondromatosis of the ankle causing impingement in the ankle joint. Arthroscopic removal of the loose bodies and synovectomy was done. Biopsy of the specimen confirmed the diagnosis of synovial chondromatosis. There was uneventful recovery and patient reports no pain or limitation of movements at 3 months of follow up.

Discussion – Synovial chondromatosis of ankle can be managed either through open or arthroscopic surgery. Arthroscopic surgery has potential benefits like better visualization of the joint, access to areas difficult to reach via open approach, lesser morbidity, early rehabilitation and quicker recovery.

Conclusion – Arthroscopic management of synovial chondromatosis is a reliable and successful procedure.

KEYWORDS

Synovial chondromatosis, Ankle, Arthroscopic management.

Introduction – Synovial chondromatosis is a synovial proliferative disease involving cartilaginous or osteocartilaginous metaplasia that occurs within the synovial membrane of joints, bursae or tendon sheaths.[1] Although the etiology is unknown; trauma, infection, repeated stress and embryonic remnants have been proposed to play a role.[2] Synovial chondromatosis is most common in males in third to fourth decade of the life. Most commonly involved joints are knee and hip with smaller joints being involved rarely.[1,3-4] Synovial chondromatosis of ankle is exceedingly rare. Patients present with pain and swelling around ankle with limitation of movements. Clinical examination reveals effusion, crepitus and diffuse tenderness.

The disease is classified into three phases according to Milgram[5]: the early phase characterized with synovial chondrometaplasia but no loose bodies, the transitional phase with active synovial disease and loose bodies and the late phase with loose bodies and no synovial disease.

Traditionally, synovial chondromatosis of ankle has been managed with open excision of loose bodies and synovectomy.[6-7] With better understanding of the anatomy and better instrumentation, arthroscopic treatment of ankle pathologies is gaining wider acceptance. It has many potential benefits like better visualization of the joint, lesser morbidity, early rehabilitation and quick recovery.[8]

In this case report, we presented a case of anteriorly localized synovial chondromatosis of left ankle managed arthroscopically and discussed the potential merits of arthroscopic management. Prior informed consent was obtained from the patient to utilize the data of the case for research purposes.

Case Presentation

A 28 years old male working as a resident in the surgery department presented to us with pain and swelling in his left ankle since 1 year. His job involved standing for long durations. He had progressive pain and mild limitation of movements at the ankle over the period of one year. He had no history of trauma, infection, any systemic inflammatory disease or any family history of bone and joint disorder. On physical examination, his left ankle revealed mild tenderness on anterior aspect on palpation along with palpable loose bodies. The pain increased on dorsiflexion of the ankle. The ankle showed no signs of instability. On radiological analysis, multiple nodules with calcification were located on anterior aspect of the left ankle. Magnetic resonance imaging (MRI) revealed calcified well circumscribed nodules in the anterior aspect of the left ankle (Fig 1-2). The laboratory tests were found to be within normal limits. The patient was diagnosed as a case of synovial chondromatosis of the ankle causing secondary impingement and was planned for arthroscopic evaluation and loose body removal along with synovectomy.



Figure 1 – MRI of the ankle – sagittal view

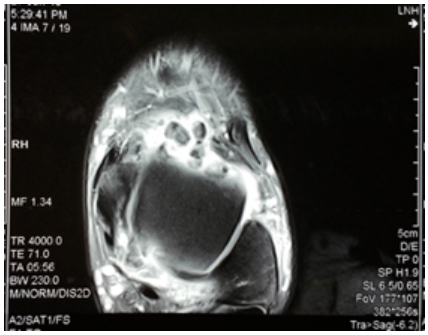

Figure 2 – MRI of the ankle axial view showing cartilaginous nodules

The patient was given spinal anaesthesia and a tourniquet was applied. Standard anteromedial and anterolateral arthroscopic portals were made to access the ankle joint. On arthroscopic evaluation, multiple loose bodies (Fig 3) and hypertrophic synovium (Fig 4) were found. The cartilage over the talus and tibial side of the joint was found to be normal.

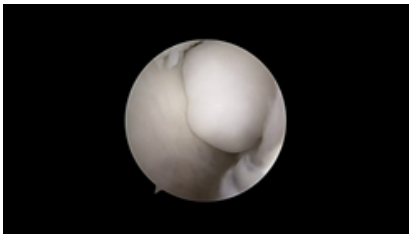

Figure 3A – arthroscopic view of ankle with loose bodies

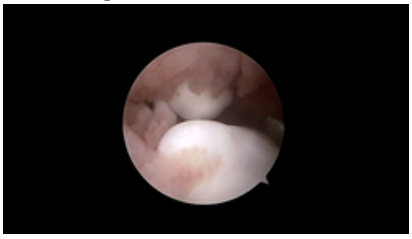

Figure 3B – arthroscopic view of ankle with loose bodies

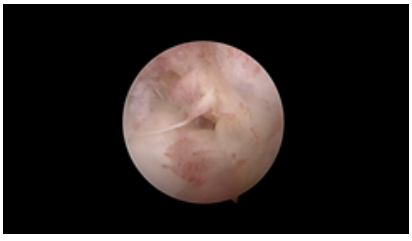

Figure 4 – Synovitis inside the joint

Arthroscopic loose body excision and partial synovectomy was performed (Fig 5-6). The portals were closed primarily without drain. A compression bandage was applied. Active and passive movements were allowed from the first post operative day. Patient was allowed partial weight bearing and by two weeks he was allowed full weight bearing ambulation. Histopathological examination confirmed the diagnosis of synovial chondromatosis with cartilaginous nodule proliferation. (Fig 7)

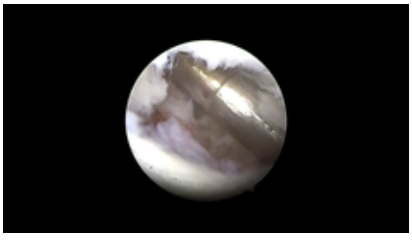

Figure 5 – Arthroscopic synovectomy being done

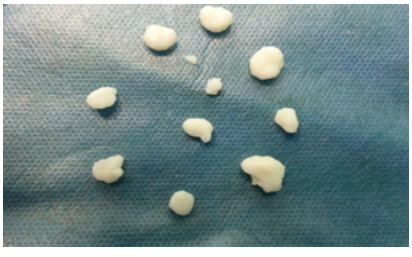

Figure 6 – Macroscopic images of the loose bodies retrieved from the ankle joint

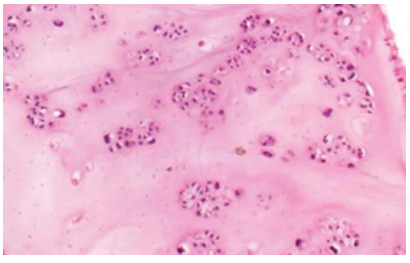

Figure 7 – Histological examination reveals cartilaginous nodules

The patient's plantar flexion and dorsiflexion improved in the post operative period. Patient reported no complications in the follow up period up to 1 year and had no recurrence clinically and radiologically.

Literature review and Discussion

Synovial chondromatosis is a condition associated with metaplastic changes in synovial lining of joint, tendon or bursa which results in multiple cartilaginous nodules in the joint.[1] The disease most commonly occurs in males within age group of 20-40 years. Most common symptoms are pain and swelling along with limitations of the range of motion across the joint. Knee is the most commonly involved joint followed by hip and other joints.[3-4] The calcified nodules can be detected on anteroposterior and lateral xray images. MRI helps in early identification of the disease. Differential diagnosis include osteocartilaginous loose bodies (post traumatic), periosteal chondroma and tenosynovial giant cell tumour.[13]

Synovial chondromatosis of ankle is an exceedingly rare entity with very few published reports in literature. Isolated cases of ankle synovial chondromatosis have been reported by Pathak[9], Ozyurek[10] and Ozmeric[11]. These cases were treated with either open or arthroscopic excision. Galat reported the largest case series of patients with foot and ankle synovial chondromatosis in 2008[7]. In this study 8 patients underwent synovectomy and excision of the loose bodies. Over a follow up of 9 years, 4 patients remained asymptomatic without any recurrence. One patient had midfoot arthrodesis following degenerative changes. 3 patients underwent below knee amputation, one for multiple recurrences and two for malignant transformation to low grade chondrosarcoma. This report suggests that ankle synovial chondromatosis has a potential of leading to degenerative changes in the joint and also malignant transformation. Hence, the condition should be promptly diagnosed and treated with synovectomy and loose bodies removal.

Traditionally, synovial chondromatosis of ankle has been treated with open surgery.[6-7] Arthroscopic excision and synovectomy is now getting acceptance[12]. Arthroscopic treatment has potential advantages like better access to the joint, lesser morbidity, early rehabilitation and recovery[8]. However, there is possibility of limited synovectomy or residual loose bodies with arthroscopic surgery. Loose bodies removal and synovectomy is becoming the standard arthroscopic treatment for management of ankle synovial chondromatosis[12].

Conclusion

To conclude, ankle synovial chondromatosis is a rare phenomena and its arthroscopic treatment is a successful and reliable procedure. It has potential benefits over open surgery. We present this case report owing to its rarity and clinical importance.

Conflict of Interest Declaration - The authors report no conflict of interest. Authors have no financial aid to declare.

REFERENCES

1. Wiedemann N.A., Friederichs J., Richter U. Secondary synovial chondromatosis of the ankle joint. Orthopade. 2011;40:807–811.
2. Davis R.I., Hamilton A., Biggart J.D. Primary synovial chondromatosis: a clinicopathologic review and assessment of malignant potential. Hum Pathol. 1998;29:683–688.
3. Bojanic I., Bergovec M., Smoljanovic T. Combined anterior and posterior arthroscopic portals for loose body removal and synovectomy for synovial chondromatosis. Foot Ankle Int. 2009;30:1120–1123.
4. Murphey M.D., Vidal J.A., Fanburg-Smith J.C. Imaging of synovial chondromatosis with radiologic–pathologic correlation. Radiographics. 2007;27:1465–1488.
5. Milgram J.W. Synovial osteochondromatosis: a histopathological study of thirty cases. J Bone Joint Surg Am. 1977;59:792–801.
6. Iossifidis A., Sutaria P.D., Pinto T. Synovial chondromatosis of the ankle. The Foot. 1995;5:44–46.
7. Galat D.D., Ackerman D.B., Spoon D. Synovial chondromatosis of the foot and ankle. Foot Ankle Int. 2008;29:312–317.
8. Doral M.N., Uzumcugil A., Bozkurt M. Arthroscopic treatment of synovial chondromatosis of the ankle. J Foot Ankle Surg. 2007;46:192–195.
9. Pathak S, Joseph C, Aravinda M, Sonar S, Vinodh K, Rajan D. A case of primary intra-articular and extra articular synovial chondromatosis of ankle and foot. Int J Orthoped Surg 2006; 4(1)
10. Ozyurek S, Atik A, Sivrioglu AK, Ege T. Primary synovial osteochondromatosis of the ankle. BMJ Case Rep 2013; doi:10.1136/bcr-2013-009046
11. Ozmeric A, Aydogan NH, Kocadal O, Kara T, Pepe M, Gozel S. Arthroscopic treatment of synovial chondromatosis in the ankle joint. Int J Surg Case Rep 2014 Oct;5(12): 1010 -1013.
12. Bojanic I., Bergovec M., Smoljanovic T. Combined anterior and posterior arthroscopic portals for loose body removal and synovectomy for synovial chondromatosis. Foot Ankle Int. 2009;30:1120–1123.
13. Fetsch J.F., Vinh T.N., Remotti F. Tenosynovial (extraarticular) chondromatosis: an analysis of 37 cases of an underrecognized clinicopathologic entity with a strong predilection for the hands and feet and a high local recurrence rate. Am J Surg Pathol. 2003;27:1260–1268.