Volume : 5 | Issue : 12 | December-2016 • ISSN No 2277 - 8179 | IF : 3.508 | IC Value : 78.46

Original Research Paper

Tacrolimus versus Cyclosporine- Comparative Evaluation as First line drug in Vernal keratoconjunctivitis.

Ophthalmology

KEYWORDS: VKC,TOSS, TSSS

Dr Rashmi kumari	Senior resident,RIO,IGIMS Patna
Dr Bhawesh Chandra Saha	Senior resident AIIMS Patna
Dr Bibhuti Prasanna Sinha	Additional Professor,HOD,RIO,IGIMS ,Patna
Dr Nilesh Mohan	Associate Professor,RIO,IGIMS,Patna

ABSTRACT

To evaluate and compare the efficacy, side effects and recurrence rate of vernal kerato conjunctivitis (VKC) with 0.03% tacrolimus and 0.05% cyclosporin,a prospective randomised double blinded comparative study was conducted at a tertiary eye center. 46 Patients of VKC between March 2015- August 2015 were randomly divided into two groups and treated for 6weeks with either Tacrolimus(0.03%) eye ointment BD or Cyclosporine (0.05%) eyedrops QID.The main outcome measures were scoring and comparison of Total subjective symptom scores (TSSS) and Total objective ocular sign scores (TOSS) within and between the Groups at each follow up. 32 patients with comparable baseline characters were analysed. With treatment both TSSS and TOSS decreased consistently in both groups without any adverse effects but an increase in scores was noticed within two weeks after drug withdrawl.Conclusion; Both drugs are equally effective and safe in VKC but with short lasting effect .

Introduction: –

Vernal keratoconjunctivitis (VKC), a chronic sight-threatening inflammatory eye disease of children and adolescents, usually occurs before 10 years of age with a male-female ratio about 2:1.[1] The disease generally lasts 2-10 years and ordinarily resolves by puberty. It is observed predominantly in warm climate such as in countries surrounding the Mediterranean, in West and central African nations, in the Middle-East and in Japan.[1]

The signs and symptoms of VKC usually occur from April to August, although some patients have a perennial form of the disease. Three forms of the disease are observed, i.e. limbal, tarsal and mixed VKC.[2] Symptoms of VKC include intense itching, tearing, mucous secretions and severe photophobia.[3,4] Conjunctival signs comprise hyperemia, papillary hypertrophy, giant papillae, discharge, and Horner-Trantas dots (accumulation of gelatinous inflammatory infiltrates around the limbus).[3,4]

A significant history of atopy is found in three-quarters of VKC patients and a family history of atopy is observed in about two-thirds patients.

The precise immunopathogenic mechanism is unknown but is thought to be more complex than a simple type 1 hypersensitivity reaction. Since negative skin test is not infrequently observed among these cases, VKC cannot be regarded as a disease solely due to hypersensitivity type-1.[5] Histopathologically, VKC is characterized by conjunctival infiltrations with eosinophils, degranulated mast cells, basophils, plasma cells, lymphocytes, and macrophages. T cell culture from conjunctival scraping of VKC patients yielded mainly Th2-type clones.[6,7] Th2- derived cytokines such as IL-4, IL-5, IL-13, growth factors and enzymes are found in the conjunctiva of VKC patients. Increased production of Th2 cytokines in VKC may contribute, in part, to tissue remodelling and papillary formation on tarsal conjunctiva and this pathophysiology has paved the use of certain recent drugs (immunomodulators) like cyclosporine and tacrolimus while the conventional therapy includes topical steroids, NSAIDS, vasoconstrictors, antihistamines, mast cell stabilizers. They inhibit activation of T cells, and also inhibit IgE-dependent histamine release from mast cells and basophils.[6,7] Both drugs act on their target cells via cyclophyllin receptors.Tacrolimus (FK-506) is a macrolide antibiotic that has potent immunomodulatory properties. It acts primarily on T-lymphocytes by inhibiting production of cytokines, particularly IL-2, IL-3, IL-5, TNF-α and IFN-γ.[8]

The most effective treatment for VKC have been topical corticosteroids, but it carries considerable risk of complications like cataract, glaucoma and secondary infections which may even lead to permanent visual impairment.[9] Thus there is need for an alternative, effective, safe drug that can decrease the morbidity from this potentially blinding disease.

Both cyclosporine A and tacrolimus have achieved breakthrough results in the treatment of severe allergic eye diseases, and are considered to be well tolerated with negligible side-effects according to many recent studies.[10-14].

Cyclosporine eye drops were found to be effective in treating severe VKC. However, burning with 2% cyclosporine was unacceptable to several patients and led to low compliance.

Tacrolimus ointment has shown satisfactory results in treatment of recalcitrant VKC. Adverse effect from 0.1% tacrolimus ointment in some study report only transient stinging effect. Systemic absorption of FK-506 from conjunctival surface was found to be minimal.

So the aim of our study was to evaluate the efficacy and safety of these two immunomodulators as first line drug in VKC and also to compare their relative effectiveness at lowest available concentration.

Material and methods:

A prospective randomised double blinded comparative clinical study was designed .Ethical clearance was taken from the hospital ethics committee. Diagnosis of VKC was made clinically according to the presence of classical signs and symptoms . Clinical Scoring System of Bleik et al (table1) was used to grade the signs and symptoms. The guardians of verbal children or adolescent with active disease that is total subjective symptom score, TSSS>6 & total objective sign score ,TOSS > 4 presenting in the out patients department(OOD) between march 2015-august 2015 were explained about the study. Those who agreed for the regular follow ups were included after taking proper written informed consent.

Presence of co-existing ocular diseases such as glaucoma, uveitis, corneal disease, ocular infection, systemic diseases other than co-existing allergic rhinitis, asthma and atopic dermatitis and any reported hypersensitivity to FK-506 or cyclosporine formed the basis

Volume : 5 | Issue : 12 | December-2016 • ISSN No 2277 - 8179 | IF : 3.508 | IC Value : 78.46

for exclusion from the trial.

Complete general, physical and ophthalmologic examinations were done. Patients were advised to discontinue all topical and oral allergic drugs,if any, for 2-weeks after which they were examined and their baseline symptoms (TSSS) as well as signs(TOSS) were recorded on the basis of table1 and then were randomly assigned to one of the two study groups.

Table 1- clinical scoring system (Bleik et al)[15]

Grading of Symptoms(Bleik et al) Itching, tearing, photophobia, discharge and foreign body sensation	
0	indicating no symptoms
1+	mild symptoms of discomfort which were just noticeable
2+	moderate discomfort noticed most of the day but did not interfere with daily routine activities
3+	severe symptoms interfering with daily routine activities
Grading of Signs Conjunctival hyperemia	
0	no evidence of bulbar hyperemia
1+	mild bulbar hyperemia
2+	moderate bulbar hyperemia.
3+	severe bulbar hyperemia
Palpebral conjunctival papillae	
0	no papillary hypertrophy of the palpebral conjunctiva
1+	mild papillary hypertrophy
2+	moderate papillary hypertrophy (hazy view of the deep tarsal vessels).
3+	severe papillary hypertrophy (deep tarsal vessels not visible in more than 50% of the surface).
Punctate keratitis	
0	no evidence of punctate keratitis
1+	one quadrant of punctate keratitis
2+	two quadrants of punctate keratitis
3+	three or more quadrants of punctate keratitis
Trantas'dots	
0	no evidence of dots..
1 +	1 to 2 dots
2 +	3 to 4 dots
3 +	more than 4 dots
Limbal infiltration	
0	no evidence of limbal infiltrates
1 +	less than 90^0 of limbal infiltrates
2 +	less than 180^0 of limbal infiltrate but more than 90^0.
3 +	more than 180^0 of limbal infiltrate.

Group A received Tacrolimus ointment (0.03%) BD,a placebo eye drop QID and Group B recieved Cyclosporine e/d (0.05%) QID along with placebo eye ointment BD along with cold compression for 6 weeks.Follow up was done fort nightly for 8weeks (6 weeks with treatment and 2 weeks after completion of treatment).

The main outcome was measured in terms of Total subjective symptom scores(TSSS) and total objective ocular sign score (TOSS) before and after treatment at each visit. Secondary outcomes included scoring of transient side effects of medications and recurrence of symptoms and signs 2 weeks after treatment completion.

Transient ocular discomfort from drugs such as burning, blurring, stinging, ocular pain, periorbital edema, periorbital rash and headache were evaluated within 30 minutes after administration of the medications and were graded from 0-3 depending upon increasing severity.

All data were analysed with the statistical package for social sciences(SPSS). Continuous variables are presented as mean ± standard deviations (SD's) and the categorical variables as percentages.Student's t-tests were used to determine the significance of the differences between means in the variables that were normally distributed. The Wilcoxon signed-rank tests were used for paired samples when the data were not normally distributed. Comparison of TSSS,TOSS and side effect scores between and within group at different time points (at entry, weeks 2, 4, 6and 8) was performed by ANOVA with repeated measure analysis and with Bonferroni corrections. The p-value <0.05 were considered to be statistically significant.

Results

A total of 46 patients were enrolled into this study,35(19 from group A and 16 from group B) completed the follow up.Demographic history revealed that most of the patients lost to follow up were from remote area of bihar and majority of them attended 1 or two follow ups randomly and hence were excluded while evaluating the results.Only 2 out of 46 patients never turned back.Hence 32 patients,16 from each group, with complete follow up were analysed.Out of the 32 patients ,28 were male with a mean age of 8.06 (±1.94) years in Group A and 7.12 (±1.66)years in Group B, the difference between the two being statistically insignificant (p=0.33)(Table 2).Average duration of disease was7.41(±7.49) months and tarsal VKC was the most common form of presentation (n = 24) followed by mixed type VKC and limbal variant (Table 2) in both groups.

Twenty eight patients were on some form of treatment for VKC before enrollment (topical steroid and olopatadine - 20 patients, ketorolac and olopatadine -8 patients). Four patients were newly diagnosed case of VKC that had not been treated previously with any drug at entry.

The five major complaints recorded by patients were itching(32 patients, 100%), discharge(28 patients, 87%), tearing (30 patients, 93.75%),photophobia (9 patients, 28.12%) and foreign body sensation 11 patients, 34.37%). Associated allergic diseases noted were allergic rhinitis (31%), asthma (6%) and atopic dermatitis(3%). Base line Total subjective symptom score (TSSS) in the Group A was 7.06 (±2.59) and in Group B was 7.75 (±2.90) the difference being clinically insignificant,p= 0.6.Baseline Total ocular sign score(TOSS)in both the groups were 4.88 (±1.5) and 4.5 (±1.15) respectively, p= 0.8,(Table 2).

Table2. Demographic characteristics and disease severity

	Tacrolimus group (n=16)	**Cyclosporine group (n=16)**	**p value**	**Total (n=32)**
Male	15	13		28
Female	1	3		4
Mean Age (± SD) Range(years)	8.06 (±1.94) 5 -12	7.12 (±1.66) 5 - 11	P= 0.30	7.62(±1.82) 5 – 12
Duration of disease(months). Range	8.25 (±8.80) 1- 36	6.56(±5.94) 1-24		7.41(±7.49) 1-36
Associated atopic conditions -Allergic rhinitis -Asthma -Atopic dermatitis	6 2 0	4 0 1		10(31.25%) 2 (6.25%) 1 (3.125%)
Type of VKC Tarsal Limbal Mixed	11 3 2	13 0 3		24(75%) 3 (9.37%) 5 (15.62%)

Total subjective symptom score (TSSS)	7.06 (±2.59)	7.75 (±2.90)	p= 0.6	
Total ocular sign score(TOSS)	4.88 (±1.5)	4.5 (±1.15)	p= 0.8	

There was reduction in TSSS in both the groups from 2weeks onwards which was statistically significant at 4weeks ($p<0.05$) when compared to baseline values and was maintained till the completion of the course (6weeks).But the difference between the two groups ($p=0.54$) was not significant (Table 3,Figure1).

Table3 ;Total subjective symptom scores at different visits (TSSS) * t test for difference of mean, confidence interval**

VARIABLE	TACROLIMUS GROUP (n=16)	CYCLOSPORINE GROUP (n=16)	p value*
	MEAN (95% C I**)	MEAN (95% C I**)	
BASELINE	**7.06** (5.68- 8.44)	**7.75** (6.19- 9.36)	*p= 0.48*
2ND WEEKS	4.68(3.78 - 5.59)	3.875 (3.29 - 4.45)	*p = 0.1181*
4TH WEEKS	2.75(2.38 - 3.11) ***p=0.004***	2.56 (2.01-3.11) ***p=0.004***	*p = 0.548*
6TH WEEKS	1.31(0.99 - 1.63) ***p=0.001***	1.18 (0.83 -1.53) ***p=0.001***	*p= 0.578*
8TH WEEKS	3.87 (3.33 -4.42) ***p=0.03***	3.75(2.98 -4.51) ***p=0.03***	*p =0.779*

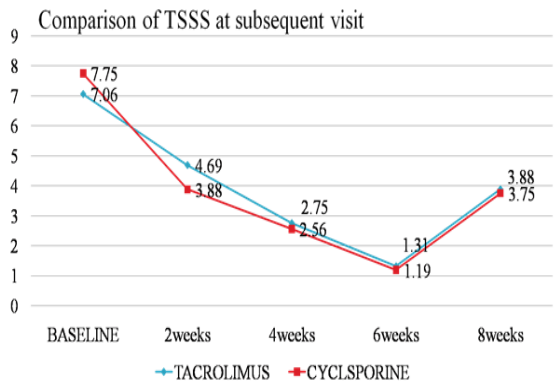

Fig 1. Graphical plot of total subjective symptom score at different follow up

The total objective sign score ,TOSS showed consistent decrease in subsequent visit in both the Groups and it was statistically significant,when compared to baseline,at week 6th week in both the groups ($p < 0.01$)(Table 4,figure 2).No difference in TOSS between the two treatment groups was observed at any time points.

TABLE 4; TOTAL OBJECTIVE SIGN SCORE (TOSS) AT DIFFERENT VISITS * t test for difference of mean ** confidence interval

VARIABLE	TACROLIMUS GROUP (n=16)	CYCLOSPORINE GROUP (n=16)	p value*
	MEAN (95% C I**)	MEAN (95% C I**)	
BASLINE	4.875(4.07 -5.67)	4.5 (3.88- 5.11)	*p= 0.43*
2ND WEEKS	4.18(3.60 -4.78) ***p 0.91***	4.0 (3.56 - 4.43) ***p 0.91***	*p 0.59*
4TH WEEKS	3.375 (2.73 -4.01) ***p=0.134***	3.06 (2.53-3.59) ***p=0.134***	*p 0.43*
6TH WEEKS	*2.875(2.40 -3.34)* ***p= 0.03***	*2.5(1.95 – 3.05)* ***p=0.03***	*p 0.28*
8TH WEEKS	3.25(2.75- 3.74) ***p= 0.121***	3.0(2.3 -3.67) ***p=0.121***	*p 0.53*

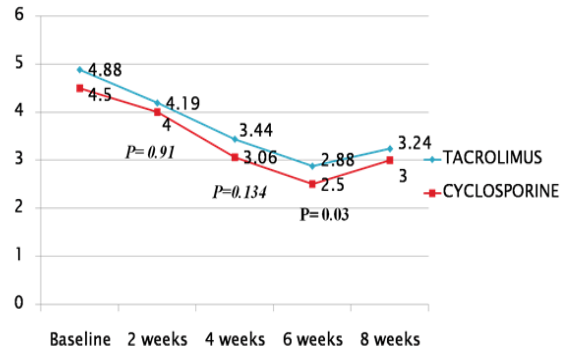

Fig 4. Graphical plot of total objective sign score at different follow up

Conjunctival hyperemia was significantly decreased in both the groups at 4th and 6th week. But no significant difference in papillae (size or number) was detected even at 6th week of treatment in either group. At 8th week (after 2 weeks of discontinuing treatment) increase in TSSS and TOSS was observed in both the groups though it was not statistically significant as compared to baseline.(Table 3 and Table 4).No significant side effect, ocular or systemic ,were noted in either group except mild stinging in one patient in Group B (Table 5)

Table 5 - ADVERSE EFFECTS

	Tacrolimus (n=16)		Cyclosporine(n=16)	
	Grade	no(%)	Grade	no(%)
Burning		0		0
Stigning		0	1	1(6.25)
Ocular pain		0		0
Periobital rash		0		0
Periorbital odema		0		0
headache		0		0

Discussion

In this study, both topical treatment of 0.03% FK-506 ophthalmic ointment and 0.05% cyclosporine eye drops caused significant decrease in TSSS from 4th weeks onwards. A similar prospective, double-masked, randomized comparative study was conducted by Labcharoenwongs et al in which twenty-four VKC patients received 0.1% tacrolimus eye ointment twice-daily for 8 weeks, and the other 24 received cyclosporine A 2% eye drops for the same duration.[16] This study reported that tacrolimus brought about an improvement of the signs and symptoms of VKC similar to that of cyclosporine A . In addition, this study concluded that cyclosporine A treatment was related to a burning sensation and pain on application, compared with a transient burning sensation which was detected in patients with tacrolimus treatment.Objective ocular signs were found to be more improved with tacrolimus treatment, even though this was not statistically significant. Our study didn't show any significant difference between the efficacy of the two drugs .At the same time there was no ocular side effects in either group. More over the beneficial effect of tacrolimus on signs especially on papillary size as mentioned in the above study and many other studies as well was not present in our study.This difference can be attributed to the lower concentration of drugs(0.03%) as compared to 0.1% used in most of the other study.

Topical cyclosporine of various concentrations has been investigated for VKC treatment with varying results. In a 2-week, double-masked,placebo-controlled trial by Pucci et al,topical cyclosporine 2% resulted in an approximately 40% reduction in subjective and objective scores by the end of the randomization period.[10] Same concentration of cyclosporine eye drop was tried in a large number of children with VKC from Rwanda, Africa.[13] In that study, cyclosporine 2% eye drop was shown to be as effective as topical

Volume : 5 | Issue : 12 | December-2016 • ISSN No 2277 - 8179 | IF : 3.508 | IC Value : 78.46

dexamethasone during the 4-week study period. In a longer open trial by Spadavecchi et al utilizing a lower concentration of cyclosporine (1.25% and 1%) for 4 months, a higher degree of benefit in subjective and objective was observed.[17] Difference in efficacy of cyclosporine in various publications could be due to difference in methods for cyclosporine preparation and to difference in disease severity.Our study too showed effectiveness of cyclosporine significant enough at 4weeks,probably because of lower concentration of drug used (0.05%) At the same time cyclosporine is notorious for stinging sensation but we didn't get such complaints in our study due to lower concentration of drugs used that on the other hand might be responsible for the relapse of symptoms within 2 weeks of stopping treatment.No literature at present mentions about the course of the disease after stopping treatment with respect to concentration and duration which needs to be further investigated to exactly quantify the duration of treatment for most effective outcome taking care off the side effects of these immune modulators on long term use. The limitations of our study is a small sample size, short course of treatment.Also since 19 out of 54 patients(35%) were lost to follow up,not much can be commented on the side effects of the drugs with confidence as stinging could

Conclusion

Our study suggests that both tacrolimus and cyclosporine have potentials to be used as first line drugs that too with equal efficacy as there was significant decrease in TSSS and TOSS at 6th weeks but the effect of drugs is short lasting so the duration of treatment needs to be investigated further with respect to drug concentration to maintain the phase of remission.

References

1 Collum MT. Vernal keratoconjunctivitis. Acta OphthalmolScand. 1999;228 (Suppl):14-6

2 Neumann E, Gutmann MJ, Blumenkrantz N, Michaelson IC. A review of four hundred cases of vernal keratoconjunctivitis. Am J Ophthalmol. 1959;47:166-72.

3. Bielory L. Allergic and immunologic disorder of the eye. Part II: Ocular allergy. J Allergy ClinImmunol. 2000;106:1019-32.

4. Leonardi A. Vernal keratoconjunctivitis: pathogenesis and treatment. ProgRetin Eye Res. 2002;21:319-39..

5. Staphl JL, Barney NP. Ocular allergic disease. Curr Opin Allergy ClinImmunol. 2004;4:455-9.

6. Bonini S. Atopic keratoconjunctivitis. Allergy. 2004;59:(Suppl. 78):71-3.

7. Cook EB. Tear cytokines in acute and chronic ocular allergic inflammation. Curr Opin Allergy Clin Immunol. 2004;4:441-5.

8.. Schreiber SL, Crabtree GR. The mechanism of action of cyclosporine A and FK 506. Immunol Today. 1992;13:136-42

9. Tabbara KF. Ocular complications of vernal keratoconjunctivitis.Can J Ophthalmol. 1999;34:88-92.

10. Pucci N, Novembre E, Cianferoni A, Lombardi E, Bernardini R, Caputo R, et al. Efficacy and safety of cyclosporine eye drops in vernal keratoconjunctivitis. Ann Allergy Asthma Immunol. 2002;89:298-303.

11. Gupta V, Sahu PK. Topical cyclosporin A in the management of vernal keratoconjunctivitis. Eye. 2001;15:39-41.

12. Vichyanond P, Tantimongkolsuk C, Dumrongkichaiporn P,Jirapongsananuruk O, Visitsunthorn N, Kosrirukvongs P. Vernal kerotoconjunctivitis; result of a novel therapy with 0.1% topical ophthalmic FK 506 ointment. J Allergy ClinImmunol. 2004;113:355-8.

13. De Smedt S, Nkurikiye J, Fonteyne Y, Tuft S, De Bacquer D, Gilbert C, Kestelyn P.Topical ciclosporin in the treatment of vernal keratoconjunctivitis in Rwanda, Central Africa: a prospective, randomised, double-masked, controlled clinical trial. Br J Ophthalmol. 2012;96:323-8.

14. Joseph MA, Kaufman HE, Insler M.Topical tacrolimus ointment for treatment of refractory anterior segment inflammatory disorders.Cornea. 2005;24:417-20.

15.. Bleik JH, Tabbara KF. Topical cyclosporine in vernal keratoconjunctivitis. Ophthalmology. 1991; 98: 1679-84.

16.. Labcharoenwongs P, Jirapongsananuruk O, Visitsunthorn N, et al. A doublemasked comparison of 0.1% tacrolimus ointment and 2% cyclosporine eye drops in the treatment of vernal keratoconjunctivitis in children. Asian Pac J Allergy Immunol 2012; 30:177–184

17. Spadavecchia L, Fanelli P, Tesse R, Brunetti L, Cardinale F,Bellizzi M, et al. Efficacy of 1.25% and 1% topical cyclosporine in the treatment of severe vernal keratoconjunctivitis in childhood. Pediatrc Allergy Immunol. 2006;17:527-32.