ORIGINAL RESEARCH PAPER

Volume-7 | Issue-4 | April-2018 | PRINT ISSN No 2277 - 8179

INTERNATIONAL JOURNAL OF SCIENTIFIC RESEARCH

TESTICULAR SEMINOMA: USG, DOPPLER, ELASTOGRAPHY IMAGING WITH PATHOLOGICAL CORRELATION- A CASE REPORT

Radiodiagnosis

Dr.Monika Pote* Resident, Dept. of Radio-diagnosis, Jawaharlal Nehru Medical College, Sawangi (Meghe), Wardha, Maharashtra, India - 442001. *Corresponding Author

Dr.Suresh Phatak Professor and Head of department, Dept. of Radio-diagnosis, Jawaharlal Nehru Medical College, Sawangi (Meghe), Wardha, Maharashtra, India - 442001

ABSTRACT

A 45 year old man was admitted in our hospital for left testicular swelling since last six months, without other symptoms. Sonoelastography is a new modality which is used in evaluation of soft tissue masses in breast, thyroid, prostate and liver. USG, Doppler and elastography findings of testicular tumor are discussed.

KEYWORDS

testicular tumor, elastography, strain ratio, seminoma

INTRODUCTION:

Testicular germ cell tumors account for around 1-2% of all malignancies in males up to the age of 65 years but they are the most common nonhematologic malignancy in males 15-49 years old.Approximately 50% of germ cell tumours are seminomas. Seminomas have the most favorable prognosis of all testicular malignancies and have a high rate of successful treatment with radiation therapy and chemotherapy. [1]

CASE REPORT:

A 45 year-old man was admitted in our hospital for left testicular swelling and mild discomfort since last 6 months. Clinical examination revealed enlarged and hard left testis without local inflammatory signs. No inguinal or abdominal lymphadenopathy was palpable. Ultrasonography revealed a well defined irregular hypoechoic mass with heterogeneous echo texture measuring approx 49x29mm in size. No retroperitoneal or inguinal lymphadenopathy was seen. This mass showed no involvement of tunica albugenia and was hyper vascular on Doppler. On elastography the lesion showed mostly stiff tissue (dark blue) within the tumor and strain ratio of 5.56. Patient was operated and diagnosed as seminoma on histopathology for which a left testicular high orchidectomy was performed.

DISCUSSION:

Tsukuba scoring system: Itoh et al in 2006 gave an elastographic score for diagnosis of malignant masses on sonoelastography.A score of 1 indicated even strain for the entire hypoechoic lesion (i.e., the entire lesion was evenly shaded in green). A score of 2 means strain in most of the hypoechoic lesion, with some areas of no strain (i.e., the hypoechoic lesion had a mosaic pattern of green and blue), A score of 3 implies that strain at the periphery of the hypoechoic lesion, with sparing of the center of the lesion (i.e., the peripheral part of lesion was green, and the central part was blue). A score of 4 shows no strain in the entire hypoechoic lesion (i.e., the entire lesion was blue, but its surrounding area was not included. A score of 5 indicated no strain in the entire hypoechoic lesion or in the surrounding area (i.e., both the entire hypoechoic lesion and its surrounding area were blue). BGR represents typical artifactual three layered aspect (blue-green-red) encountered with cystic lesions. In strain patterns, score 1, 2 and 3 emp¬hasized benign features whereas masses with scores of 4 and 5 were considered as malignant. [2]

Strain Ratio Measurement: A semi quantitative method of lesion assessment, termed as strain ratio (SR) measurement, has also been developed. Calculation of the SR value is based on determining the average strain measured in a lesion and comparing it to the average strain of a similar area of fatty tissue in the adjacent breast tissue. Using proprietary software, the average strain of the lesion is determined by selecting a region of interest (ROI) encompassing the lesion; the value of strain ratio increases as a function of the relative stiffness of the target lesion. As the Strain Ratio increases, the likelihood of invasive breast cancer is also higher. [3] Strain ratios of normal testes ranged from 0.27 to 0.38, with a mean strain of 0.33 and a standard deviation of 0.03[4]. Elastography may be a promising tool at diagnosing testicular tumor. [5]

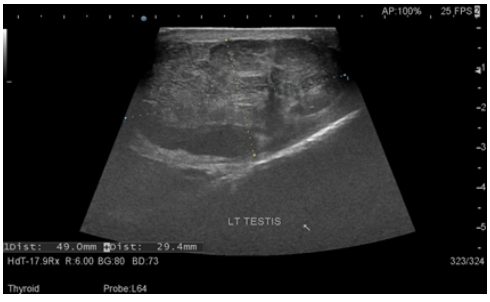

Image 1. Ill defined hypoechoic lesion measuring approx 49x29mm seen in the left testis showing herterogenous echotexture.

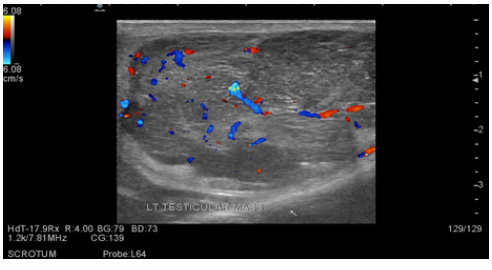

Image2. On USG doppler, hypervascularity is noted in the lesion.

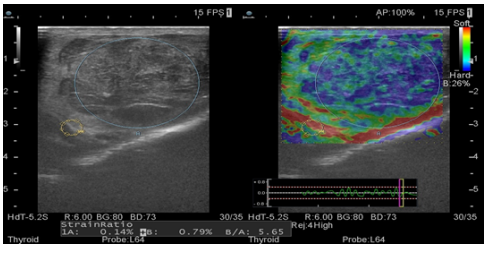

Image 3. On elastography, it shows predominently stiff tissue (dark blue color) and strain ratio of 5.65



Image 4. Post operative specimen showing the testicular tumor

REFERENCES

1. Khan O, Protheroe A. Testis cancer. Postgraduate medical journal. 2007 1;83(984):624-32.

2. Itoh A, Ueno E, Tohno E, Kamma H, Takahashi H, Shiina T, et al. Breast disease: Clinical application of US elastography for diagnosis. Radiology. 2006; 239:341-50.
3. Zhi H, Xiao XY, Yang HY, et al. Semi-quantitating stiffness of breast Solid lesions in ultrasonic elastography. Acad Radiol. 2008; 15(11):1347-1353
4. Mohamed Samir Shaaban , Saeed A. Blgozah , Mohamed N. Salama Normal testicular tissue elasticity bySonoelastography in correlation with age The Egyptian Journal of Radiology and Nuclear Medicine (2016) 47, 593–597
5. Marsaud A, Durand M, Raffaelli C, etal, elastography shows promise in testicular cancer detection Prog Urol 2015 ;25(2):75-82.