ORIGINAL RESEARCH PAPER

Volume-8 | Issue-6 | June-2019 | PRINT ISSN No. 2277 - 8179

INTERNATIONAL JOURNAL OF SCIENTIFIC RESEARCH

THE IMPORTANCE OF OCULAR FUNDUS EXAMINATION IN THE EVALUATION OF HEADACHE CASES

Ophthalmology

Dr. N. Jeyanthi Associate Professor, Department Of Ophthalmology, Kurnool Medical College, Kurnool. AP.

Dr. S. Vishnu Priya* Post Graduate, Department Of Ophthalmology, Kurnool Medical College, Kurnool, A. P. State *Corresponding Author

ABSTRACT

Background: Determine the frequency of and predictive factors for abnormal fundus findings in headache patients and importance of fundus examination as a routine and mandatory in headache patients.

Methods: A total of 600 patients attending Regional Eye Hospital, Kurnool during the period March 2017 to March 2019 were included and examined which include visual acuity testing using Snellen's chart, anterior segment examination using slit lamp biomicroscope,fundus examination using direct ophthalmoscope and fundus camera after complete dilatation of pupil with tropicamide eye drops.

Results : Among 600 patients attending regional eye hospital with the complaint of headache, most common age group is between 41 to 50 years constituting 29%, females are more commonly involved. Papilloedema is seen in 15 cases.

Conclusion : Examination of ocular fundus is one aspect of physical examination to screen omnious cause such as papilloedema.This suggests that diagnostically relevant ocular fundus findings may be present in majority of patients with headache especially in an emergency department when compared to routine OPD.

KEYWORDS

headache, fundoscopy, papilloedema, optic disc edema, acclererated hypertension.

INTRODUCTION

Of all the painful states which afflicts humans, headache is undoubtedly the most frequent. Headache may be mild or severe, organic or functional or psychogenic symptoms of serious illness like brain tumour and other cerebral disease or something between these two extremes. Headache may arise from intracranial, pericranial or extracranial conditions occur independent of any specific disease or a constant symptom of a particular disease. Though headache frequently occurs in organic disease majority are benign and organic disease must be ruled out in each patient.Chronic long standing headache which is the only symptom is usually less dangerous than an acute headache in whom never had before[4].

Examination of the ocular fundus is a critical aspect of the neurological examination. For example, in patients with headache the ocular fundus examination is needed to uncover "red flags" suggestive of secondary etiologies[1],[2]. However, ocular fundus examination is infrequently and poorly performed in clinical practice and not accurately interpreted by nonophthalmologists[1].

Fundoscopy provides the only means for direct inspection of arteries, veins or central nervous system in the intact, living patient, conditions. Eg

1) Papilloedema – reflects raised intra cranial tension – medical emergency. Treatment of its cause prevents irreversible neuronal damage and somatic death. Visible retinal venous pulsations exclude raised intracranial tension, a vital datum in assessing any patient with headache or head trauma.

2) accelerated hypertension - In severe hypertension a retinal hemorrhage is usually noted.

3) AV crossing changes confirms chronic hypertension.

MATERIAL AND METHODS

This study was conducted on 600 patients presenting to our department with the complaints of headache during the period March 2017 to March 2019. Patients <10 years and pregnant women were excluded in this study. The patients were either referred from emergency department or those attending to regional eye hospital, Kurnool with the complaints of headache were enrolled in the study. The patients were examined for vision using snellen's chart, anterior segment examination using slit lamp biomicroscope. After dilatation of pupil with tropicamide eye drops, posterior segment evaluation was done using direct ophthalmoscope. Then fundus camera was used to examine the retina and photographs were taken. Blood pressures were recorded for all the patients.

RESULTS

Table 1 : Age distribution

Age	No of patients	Percentage
11-20	85	14.16%
21-30	116	19.33%
31-40	125	20.83%
41-50	174	29%
>50	100	16.66%
Total	600	100%

Table 2 : Sex distribution

Sex	No of patients	Percentage
Male	296	49.33%
Female	304	50.66%
Total	600	100%

Table 3 : changes in the fundus

Fundus changes	No of patients	Percentage
Papilloedema	15	34.09%
Optic disc edema	12	27.27%
Optic atrophy	5	11.36%
Grade III/IV hypertensive retinopathy	7	15.90%
Idiopathic intracranial hypertension	5	11.36%
Total	44	100%

DISCUSSION

Fundus examination is a feasible method to detect devastating patient outcome in especially in acute on chronic headache cases.

Few cases normal neuroimaging studies of patients with abnormal fundus emphasizes the important role of ophthalmoscopic examination in evaluation of patients with headache to identify pathological headaches.

Optic disc edema frequently indicates increased intra cranial tension in patients with headache. Optic disc edema is seen in patients with anterior ischemic optic neuropathy.

Headache in younger age, obese, females commonly reflect idiopathic intracranial hypertension and also particularly meningiomas that frequently affect the anterior visual pathways.

An increase number of abnormal fundus findings in younger headache patient stresses the independent relevance of ocular fundus examination in evaluation of headache patients.

Older patients, secondary headache, isolated retinal haemorrhages – secondary to hypertension.

Optic disc pallor or optic atrophy in headache patients reflects the chronically raised intracranial tension with end stage papilloedema or chronic anterior visual pathway compression from an intracranial mass lesion.

Higher mean arterial pressure was predictive of abnormal fundus findings particularly in grade III to grade IV hypertensive retinopathy in headache patients and stresses that headache is one of the most common presenting symptom of hypertensive emergency.

Previously malignant hypertensive retinopathy occured frequently in younger patients and end organ damage occured with severely increased BP(180/120mm Hg). Hence presence of headache may be helpful in determining which hypertensive patients to screen for ophthalmic end organ damage an important and isolated sign of malignant hypertension.

The ocular fundus examination is particularly relevant for younger patients often presumed to have primary headaches.

CONCLUSION

The importance of ocular fundus examination in a simple headache the ophthalmologist may be the first one to diagnose life threatening and serious neurological conditions[5]. This stresses the importance of routine fundus examination.

Benign intracranial hypertension is a common cause of papilloedema in young, overweight females with headache.

Detecting disc edema early with ocular fundus and other neuroimaging studies with early treatment prevented them from ending up with irreversible vision loss[3] and optic atrophy.

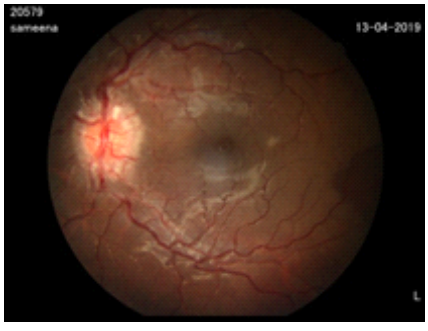

Figure 1 : fundus showing papilloedema changes.

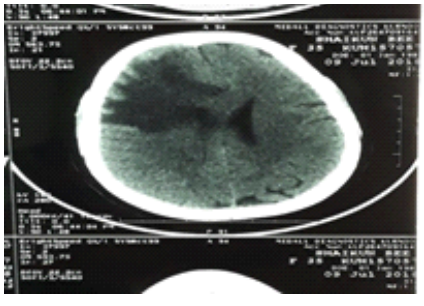

Figure 2 : CT scan brain showing midline dense meningiomatous lesion with extensive perifocal edema in frontal region with compression of frontal horns.

REFERENCES

1. Bruce BB, Lamirel C, Biousse V, et al. Feasibility of nonmydriatic ocular fundus photography in the emergency department: phase I of the FOTO-ED study. AcadEmerg Med 2011;18:928–933
2. Bruce BB, Lamirel C, Wright DW, et al. Nonmydriatic ocular fundus photography in the emergency department. N Engl J Med 2011;364:387–389
3. Ambika S, Arjundas D, Noronha V, Anshuman. Clinical profile, evaluation, management and visual outcome of idiopathic intracranial hypertension in a neuro-ophthalmology clinic of a tertiary referral ophthalmic center in India. Ann Indian AcadNeurol 2010;13:37-41
4. Text book of neuro ophthalmology by aravind eye hospitals, 3rd edition reprint 2003.
5. Shrirao N, Gandhi RA. Work up of neuro-ophthalmological cases – Examination – Investigations. J ClinOphthalmol Res 2013;1:37-44