ORIGINAL RESEARCH PAPER

Volume-8 | Issue-3 | March-2019 | PRINT ISSN No 2277 - 8179

INTERNATIONAL JOURNAL OF SCIENTIFIC RESEARCH

THE STUDY OF BOTOX INJECTION ON REFRACTORY CASES OF ANDROGENETIC ALOPECIA

Dermatology

Vidhya Livingston — Assistant Professor, Department of Cosmetology, Government Stanley Medical College and Hospital, Chennai, India

Hemamalini.R* — Assistant Professor, Department of Cosmetology, Government Stanley Medical College and Hospital, Chennai, India *Corresponding Author

Suganthi Parthasarathy — Senior Resident, Department of Cosmetology, Government Stanley Medical College and Hospital, Chennai, India

ABSTRACT

Background: Androgenetic alopecia (AGA) is a common form of alopecia with multifactorial etiology. Treatment for hair loss is widespread. Botulinum toxin (bx) may be a potential alternative for the treatment of hair loss by increasing microvasculature.

Aim: The aim was to investigate the efficacy of bx injection in the treatment of AGA.

Materials and Methods: A total of 3 male patients with AGA refractory to all possible modes of treatment, not taking treatment for past 6 months and willing to give consent were included in the study. In the scalp, 100 units were injected with 4U of bx in each site intramuscularly in the occipitofrontalis and temporalis. Patients were evaluated after 4 months.

Results: All the three patients showed good response after 4 months.

Conclusion: We found that botulinum toxin was effective for the management of AGA. However it requires large scale studies, though the cost factor plays a vital role.

KEYWORDS

Androgenetic Alopecia, Botulinum Toxin.

INTRODUCTION:

Androgenetic alopecia is one of the commonest reasons for dermatological consultation. Alopecia caused by androgens in genetically predisposed individuals is called as androgenetic alopecia. [1] Due to better understanding of the pathophysiology of AGA in recent times this has shown the way for effective treatment modalities. Even though the major treatment options continue to be topical minoxidil, systemic finasteride, prp and hair transplantations, newer modalities are under investigation. Botulinum toxin has been used for the treatment of wrinkles, hyperhidrosis and headache. In recent times, the future shows studies for the use of botox in androgenetic alopecia.

MATERIALS AND METHODS

Our study was conducted in a tertiary care centre in Tamilnadu. A total of 3 male patients aged 25 – 40 years with refractory AGA were included in the study. The diagnosis of AGA was based on clinical examination. Inclusion criteria for the study included male patients, Norwood – Hamilton grade 2 – 4, consent to be part of the study, no treatment taken for last 6 months and ready for regular follow- ups and photographs. Exclusion criteria was any localized infection around the injection site, any neuromuscular disease and concomitant drugs. Botulinum toxin 100U was diluted in 1ml normal saline. 4U was injected at different sites. Injections were intramuscular and sites selected were frontalis, occipitalis and temporalis muscles. Patients were assessed clinically and pretreatment photographs were taken. They were assessed after 4 months and repeat photographs were taken.

RESULTS

Result was assessed at the end of 4 months. Out of 3 patients, all the 3 patients had good response on photographic assessment. As per self – assessment also, all the three patients showed good response. No adverse effects were noted during the treatment.

Figure 1: PRE TREATMENT POST TREATMENT (After 4 months)

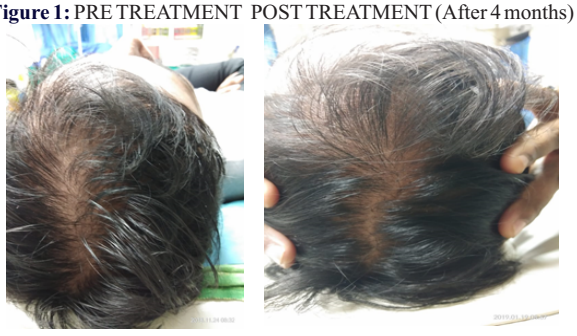

Figure 2: PRE TREATMENT **POST TREATMENT (After 4 months)**



Figure3: PRE TREATMENT **POST TREATMENT (After 4 months)**



DISCUSSION:

Androgenetic alopecia or pattern alopecia is the most prevalent disorder affecting both men and women. [2] While there are different grading systems available for AGA, the most accepted one is the Norwood – Hamilton classification. [3] The incidence of androgenetic alopecia is generally considered to be greater in males than females. It is a genetically determined disorder that develops gradually through the conversion of terminal hairs into indeterminate hairs and lastly into vellus hairs. [4] Patients have a reduction in the terminal to vellus hair ratio, normally about 4:1. The different factors that are involved in the pathogenesis are microinflammation, abnormal sensitivity to androgens and irregularities in the arrector pili muscles that leads to miniaturization of hair follicles.

AGA has been found to be the result of conversion of testosterone to

dihydrotestosterone. The conversion of testosterone to DHT is exacerbated in a low oxygen environment. Low oxygen environments are particularly prevalent in regions of poor blood supply. Hence it has been hypothesized that the use of botulinum toxin to relax tensioning muscles around the scalp can result in an improved blood supply. Muscle groups concerned include the frontalis, occipitalis and periauricular muscles.

The choice of treatment depends on various factors involving efficacy, practicability, risks and costs. Injection of botulinum toxin relaxes the muscle, which reduces pressure on the perforating vasculature, henceby increasing the blood supply and transcutaneous Po_2. This increased bloodflow can lead to reduction of accumulated DHT and reducing the signal for minituarization of hairfollicle. Because the conversion to DHT is enhanced in a low oxygen environment, oxygenated blood reduces this conversion and increases conversion to estradiol which favours high oxygen concentrations. [5] Estradiol activates a transformation in which this harmone has a significant impact on improving hair quality, and thereby decreasing hairloss. [6] Blood flow may therefore be a primary determinant in follicular health .This might be the same mechanism by which minoxidil affects androgenic alopecia.

Balding scalp is beleived to have relative microvascular insufficiency. Intramuscular injection of botox relaxes muscles and henceby increases the blood flow in balding scalp. The proposed mechanism for hair growth in androgenic alopecia after giving botox injection is that paralysis of scalp muscles enhances the blood flow to the scalp by reducing the tension on the scalp skin. Injecting botox into the peripheral muscle increases the decompression of vessels through muscle relaxation, thus causing an increase in oxygen to the frontal and coronal scalp [7]

Cost is a major concern in our country and this paves way for use of alternative treatments to fulfill the patient's desire. Hence it has its own limitations for the treatment of AGA. In offering treatment options, dermatologists should also always consider safety and efficacy of the drug . To enhance the results of the study of botox injection, it would be beneficial to trial the treatment on a larger patient base to present a wider range of results to analyse.

CONCLUSION

We found that botulinum toxin is a safe and effective therapy for AGA management, however larger studies and controlled trial to compare it with the existing FDA approved modalities need to be conducted. This demands further studies to gain more evidence before it is used extensively.

REFERENCES:

1. Sehgal, V. N., Kak, R., Aggarwal, A., Srivastava, G., & Rajput, P. (2007). Male pattern androgenetic alopecia in an Indian context: a perspective study. Journal of the European Academy of Dermatology and Venereology, 21(4), 473-479.
2. Sinclair, R., Torkamani, N., & Jones, L. (2015). Androgenetic alopecia: new insights into the pathogenesis and mechanism of hair loss. F1000Research, 4(F1000 Faculty Rev).
3. Norwood, O. T. (1975). Male pattern baldness: classification and incidence. Southern medical journal, 68(11), 1359-1365.
4. Lad, V., Suryawanshi, C., Sinhal, A., Landge, A., Wagh, V., & Jadhav, N. (2016). Androgenic Alopecia: Current Perspectives & Treatments.
5 Freund, B. J., & Schwartz, M. (2010). Treatment of male pattern baldness with botulinum toxin: a pilot study. Plastic and reconstructive surgery, 126(5), 246e-248e.
6. McElwee, K. J., & Shapiro, J. S. (2012). Promising therapies for treating and/or preventing androgenic alopecia. Skin Therapy Lett, 17(6), 1-4.
7. Trüeb, R. M. (2009). Oxidative stress in ageing of hair. International journal of trichology, 1(1), 6.