ORIGINAL RESEARCH PAPER

Volume-7 | Issue-10 | October-2018 | PRINT ISSN No 2277 - 8179

INTERNATIONAL JOURNAL OF SCIENTIFIC RESEARCH

# TO EVALUATE OUTCOME AND EFFICACY OF TYPE 1 KERATOPROSTHESIS

**Ophthalmology**

**Labdhi R Shah** — Third Year Resident, C.H Nagri Eye Hospital, Ahmedabad

**Shwetambari Singh*** — Assistant Professor, C.H Nagri Eye Hospital, Ahmedabad *Corresponding Author

**Harshit Shah** — Third Year Resident, L.G Hospital, Ahmedabad

## ABSTRACT

**PURPOSE:** To study the post operative outcome of type I Boston keratoprosthesis (KPro).

**MATERIALS AND METHODS:** Evaluation of two eyes of two patients who underwent Boston type I KPro implantation between September 2016 and September 2017 with a mean follow up of 12 month period.

**RESULTS:** In the median follow-up of 12 months visual outcomes were not satisfactory. The main indication for surgery was multiple failed grafts in both patients. Both patients demonstrated no significant improvement in vision; with pre-operative visual acuity of hand movements (HM), counting fingers. No complications like Glaucoma or Retroprosthetic membranes were found. On fundus evaluation both patients had Optic Atrophy which failed to improve vision.

**CONCLUSION:** There was no significant improvement of vision due to Optic Atrophy in both the patients. However, patients require close lifelong follow-up to manage any complications.

## KEYWORDS

## INTRODUCTION

Clinical research with keratoplasty over the previous century has demonstrated that patients with Stevens-Johnson disorder (SJS), Burns, Ocular Cicatricial Pemphigoid (OCP), and serious vascularization have a greatly poor prognosis. Likewise, patients with repeated graft failures additionally have poor probability of effective consequent corneal allo-grafting.2 Keratoprosthesis (KPro) offers an elective system to enhance vision in such patients. Boston keratoprosthesis is the most regularly utilized keratoprosthesis.3 It is a double plated PMMA gadget with a focal unbending optic that punctures the cornea. There are 2 variations of the gadget. Sort I, the more typical variation, is a neckline catch formed gadget with front plate (width 5.5– 7.0 mm), a focal optical stem, and a back plate (accessible in 8.5 mm distance across grown-up measure and 7.0 mm breadth pediatric size).3-6 The Boston II KPro is a through-the-top outline with a 2 mm front stub intended to enter through a tarsorrhaphy and is required to be utilized as a part of signs of extraordinary dry eyes, symblepharon, and other clinical sequelae related with the immune system and provocative inflammatory class that incorporates SJS and OCP.7 Our examination was intended to assess the visual results and degrees of consistency of Tyoe I BostonKPro. The snap-on threadless back plate encourages less demanding intraoperative get together and keeps any destroying of endothelium and Descemet's by the back plate screwing.

## MATERIALS AND METHODS

We attempted a review of 2 eyes of 2 patients (1 female and 1 male) who underwent Boston Type I threadless keratoprosthesis implantation at a tertiary care eye healing facility India by a solitary specialist with comparative careful method. Two operations, performed amongst September 2016 and September 2017 were considered. Preoperative evaluation included preoperative visual history, including the quantity of past medical procedures or corneal keratoplasties and examination. Patient's records were inspected to discover the status of crystalline lens, glaucoma, macular and optic nerve, and best corrected visual acuity (BCVA) when the cornea was clear. Whenever possible, visual acuity was recorded utilizing the Snellen's. Intraocular weight (IOP) was estimated utilizing Goldmann applanation tonometry. A visual examination was performed, and when the posterior segment couldn't be envisioned, B-scan ultrasonography was performed. Pivotal length estimations were gotten to settle on the diopteric intensity of the KPro. The patients and relatives were demonstrated photos delineating postoperative corrective results and a detailed consent was acquired utilizing KPro consent forms. Results were estimated as maintenance of the gadget, visual sharpness at multi week, best and last surveyed visual acuity and intraoperative and post agent entanglements. Careful system Standard careful procedure as portrayed by Dohlman and Barnes was followed. 8 Donor cornea in the every one of the cases was trephined in the outskirts with a 8.5 mm corneal trephine (which compared to the 8.5 mm size of the KPro backplate) and in the inside with a 3 mm dermatological trephine. The optical chamber of the KPro was gone through it. The back plate of the KPro was then snapped onto the stem with no turning development. A titanium locking ring is at last snapped set up behind the back plate to avert extricating of the back plate. The beneficiary cornea was trephined utilizing a 8.0 mm cornea trephine and the unite prosthesis blend was then exchanged to the patient's corneal opening and sutured with sixteen 10-0 monofilament nylon intruded on sutures. Both upper and lower puncta were closed up by cautery toward the finish of the technique. At long last, a delicate contact lens (Alcon Inc., Hunenberg, Switzerland), is set as a wrap focal point and left for uncertain length (supplanted if necessary) to forestall dryness and introduction harm to the corneal tissue around the KPro, which may prompt dissolve and necrosis.5 All patients got deep rooted prophylactic anti-biotics: moxifloxacin 0.5% (Vigamox, Alcon Inc., Hunenberg, Switzerland), Vancomycin eye drops (25mg/ml) qid, Prednisolone Acetate 1% (Predforte, Allergan, Inc., Irvine, CA, U.S.A.), and Systane Ultra (Alcon Inc., Hunenberg, Switzerland).

## RESULTS

In the median follow up of 12 months visual outcomes were not satisfactory due to presence of optic atrophy in both eyes which was found on postoperative follow up period. PreOperative Optic Atrophy could not be found out due to total corneal opacity. None of the patients created glaucoma, retroprosthetic film, sterile vitritis or endophthalmitis. Details of individual cases are discussed below in the table. Patients with repeated graft failures also have poor likelihood of successful subsequent corneal allo-grafting. Keratoprosthesis (KPro) offers an alternative technique to improve vision in such patients.8

| Case | Age | Pathology | Operated Eye | Number of Previous surgeries | Year of Previous surgeries | Pre Op BCVA | 1 Week BCVA | Last week BCVA | Follow Up Period | Complications |
|---|---|---|---|---|---|---|---|---|---|---|
| 1 | 55 Male | PBK Changes | Right | 2 in Right Eye | 2010, 2015 | Hm pl pr4+ in all four quadrants | Cfcf | Cfcf | 12 months | Optic atrophy was found |
| 2 | 63 Female | Corneal Opacity | Left | 2 in both eyes | 1990, 2000 in left eye | Cfcf | Cfcf | Cfcf | 12 months | Optic atrophy was found |

PBK=Pseudophakic Bullous Keratopathy, Pre Op= Pre Operative, BCVA = Best Corrected Visual Activity, hm= hand movement, pl= perception of light, pr= projection of rays, cfcf=counting fingers close to face.

**Pre op Slit Lamp Photograph of patient 1**

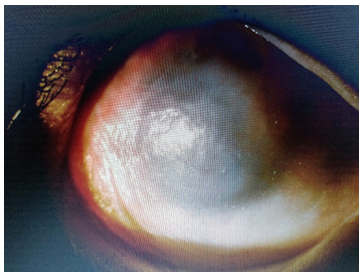

**Post Operative Photograph of patient 1**

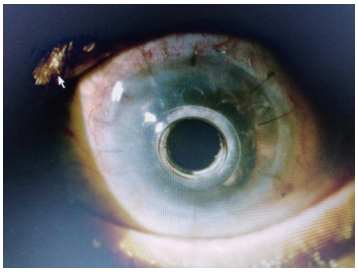

## DISCUSSION

The Boston KPro provides a viable alternative for patients in whom conventional penetrating keratoplasty is likely to fail.9 Design modifications and improvement in surgical and postoperative management have improved patient outcomes.5,10,11 All our patients underwent Boston type I aphakic threadless keratoprosthesis. Visual and retention outcomes are comparable to the ones reported elsewhere in the world.

The prognosis of keratoprosthesis KPro procedures depends on the preoperative diagnosis.

Absence of retroprosthetic membrane (RPM) in the all the 2 eyes seems to corroborate with the Chew et al's hypothesis that threadless design may reduce the formation of RPMs.14 Chew et al. hypothesized that the absence of mechanical torsional scraping of the donor corneal endothelium in the threadless design will prevent any liberation of fibroblasts and therefore decrease the likelihood of RPM formation. In addition, implantation of aphakic type I KPro in all the 4 eyes required anterior vitrectomy to be performed, which may have independently contributed to non-development of RPM. Future studies with longer follow-up may provide the relevant data to confirm this hypothesis.

Glaucoma is a frequent and severe complication after the keratoprosthesis, particularly in cicatrizing conditions, such as chemical burn, etc.12 None of our 2 eyes developed glaucoma after the implantation of Kpro

Ocular surface dryness is the single most important factor determining the retention rate of the Boston keratoprosthesis. Although bandage contact lens helps prevent desiccation of corneal surface and adds to the patients' comfort by protecting from any exposed sutures and from the shearing forces of lid movements on the upper KPro edge,5 patients with extreme dry eye should be planned for type II through-the-lid Kpro.

Increasing retention rates of KPro has lead to increasing acceptance and the gradual expansion of the indications. The procedure, which was reserved for patients with bilateral severe visual impairment and poor prognosis of keratoplasty, is now being considered in patients with a healthy fellow eye to improve the binocular status of those patients, either by expansion of the visual field or by recovering stereo vision.7

## REFERENCES


1. Khan B, Dudenhoefer EJ, Dohlman CH. Keratoprosthesis: an update. Curr Opin Ophthalmol 2001;12:282-7.
2. Dunlap K, Chak G, Aquavella JV, Myrowitz E, Utine CA, Akpek E. Short-term visual outcomes of Boston type 1 keratoprosthesis implantation. Ophthalmology 2010;117:687-92.
3. Ilhan-Sarac O, Akpek EK. Current concepts and techniques in keratoprosthesis. Curr Opin Ophthalmol 2005;16:246-50.
4. Dohlman CH, Harissi-Dagher M. The Boston Keratoprosthesis: A New Threadless Design. Digi J Opthalmol 2007;13:6.
5. Dohlman CH, Dudenhoefer EJ, Khan BF, Morneault S. Protection of the ocular surface after keratoprosthesis surgery: the role of soft contact lenses. Clao J 2002;28:72-4.
6. Dudenhoefer EJ, Nouri M, Gipson IK, Baratz KH, Tisdale AS, Dryja TP, et al. Histopathology of explanted collar button keratoprostheses: A clinicopathologic correlation. Cornea 2003;22:424-8.
7. Sayegh RR, Avena DL, Vargas-Martin F, Webb RH, Dohlman CH, Peli E. Optical functional properties of the Boston Keratoprosthesis. Invest Ophthalmol Vis Sci 2010;51:857-63.
8 Al Arfaj K, Hantera M. Short-term visual outcomes of Boston keratoprosthesis type i in Saudi Arabia. Middle East Afr J Ophthalmol 2012;19:88-92.
10. Nouri M, Terada H, Alfonso EC, Foster CS, Durand ML, Dohlman CH. Endophthalmitis after keratoprosthesis: incidence, bacterial causes, and risk factors. Arch Ophthalmol 2001;119:484-9.
11. Khan BF, Harissi-Dagher M, Khan DM, Dohlman CH. Advances in Boston keratoprosthesis: Enhancing retention and prevention of infection and inflammation. Int Ophthalmol Clin 2007;47:61-71.
12. Yaghouti F, Dohlman CH. Innovations in keratoprosthesis: Proved and unproved. Int Ophthalmol Clin 1999;39:27-36.
13. Zerbe BL, Belin MW, Ciolino JB. Results from the multicenter Boston Type 1 Keratoprosthesis Study. Ophthalmology 2006;113:1779.
14. Chew HF, Ayres BD, Hammersmith KM, Rapuano CJ, Laibson PR, Myers JS, et al. Boston keratoprosthesis outcomes and complications. Cornea 2009;28:989-96.