Original Research Paper

VOLUME-6 | ISSUE-2 | FEBRUARY-2017 • ISSN No 2277 - 8179 | IF : 3.508 | IC Value : 78.46

Treatment of Leukoplakia with Carbon Dioxide Laser and Excision: A Comparative Study.

Dental Science

KEYWORDS: leukoplakia, white patch, potentially malignant disorder, biopsy, malignancy

Dr. Rajib Khadka	Associate professor, Department of dentistry, Gandaki Medical college, Nepal
Dr. K. Anand	Lecturer, Department of dentistry, Gandaki Medical college, Nepal.
Dr. Sankalp Verma	Oral Physician, SRI SAI HOSPITAL Moradabad, India Corresponding Author

ABSTRACT

Background: Oral leukoplakia is one of the most frequently encountered potentially malignant disorders. Definitive treatment of leukoplakia is essential because of its recurrences and malignant transformation. Though there are variety of treatment options available but it is often reported that using high power laser has some advantages like less pain, swelling, prevention of metastasis, edema, less bleeding (dry surgery) and infection. **Aim:** to compare the efficacy of carbon dioxide laser and scalpel excision in the treatment of oral leukoplakia **Study design:** This prospective, double blinded, randomized clinical trial included sixty patients divided into two groups. Group A patients were treated using scalpel excision while carbon-di-oxide laser ablation was used for group B. Patients were followed for one month to observe any post operative complications. **Results:** The prevalence of oral leukoplakia was more in young males. Homogenous leukoplakia on the buccal mucosa was the most common clinical variant seen in the study. Pain, swelling, sloughing, scarring and recurrence of the lesion were least in CO2 laser treated cases compared to cases treated with scalpel excision. **Conclusion:** CO2 laser supersedes conventional scalpel in terms of better intra-operative hemostasis and reduced scarring.

Introduction

WHO collaborating centre for oral precancerous lesions (1978) defined leukoplakia as, *"A white patch or plaque 5 mm or more than 5 mm in dimension that cannot be scrapped off and that cannot be characterized clinically or pathologically as any other disease"*. Various treatment procedures (surgical and medicine) for leukoplakia have been reported, however, occasionally there is recurrence to malignant transformation irrespective of the treatment procedure.[1]

There are numerous treatment regimes for oral leukoplakia including surgical managements like excision, cryotherapy laser therapies, as well as medical managements like retinoids and vitamin A.LASER surgery is one of the treatment modalities which has been reported to have many advantages and is widely used in the treatment of leukoplakia.[2,3] It's haemostatic effect maintains the operative field and enhances removal of the lesion due to good visibility. Moreover, the damage to the tissue is minimal, thus reducing acute inflammatory reaction and postoperative pain with excellent wound healing.[4,5,6] Review of literature states that morphological and functional recovery following laser surgery is superior when compared with conventional instrumentation surgery (scalpel) and electrocautery [4, 5]. However , the epithelial regeneration and wound re-epithelialisation are delayed but without any detrimental effect on outcome. [4,5,6,7]

Material and methods

Study design

The aim of this study is to compare the efficacy of Co2 laser and scalpel incision in the treatment of oral leukoplakia. The sample was calculated using the following formula with 85% power of test and 5% error:

Necessary sample size = ∄ score * standard deviation * (1-standard deviation) / Margin of error

The inclusion Criteria included patients of both sexes, aged between 15–70 years, who presented with bilateral oral leukoplakia of similar clinical presentation and at similar site measuring\2 cm, occurring in the buccal mucosa anywhere from the corner of the mouth anteriorly to the pterygomandibular raphe region posteriorly. While the exclusion criteria included subjects with HIV and other immunosuppressive disorder, pregnancy, lactation, allergy to lignocaine, patients on contraceptives/ steroids and patients unfit for surgery. Other exclusion criteria specific to the study were patients with multifocal leukoplakia, lesions measuring more than 2 cm.

Study Protocol

After seeking institutional ethical clearance and informed written consent from patients, detailed history, clinical examination and necessary investigations were performed in standard manner. All patients were operated under local anesthesia using infiltration with xylocaine 2 % containing 1:200,000 epinephrine (1.5 ml each side). Scalpel excision was conducted using a 15 no surgical blade. Continuous wave CO2 lasers having a high power continuous output and having a infrared wavelength of 10.6 microns was used for the purpose of this research.

The study sample was randomly divided under two groups: Group A: 30 samples- excision (scalpel) and Group B: 30 samples- CO2 laser (Ablation)Group A cases were treated with excision using a scalpel 15 No. surgical blade and fine tweezers, surgically intending to remove the lesion with 1cm margins of clinically healthy appearing mucosa before sending for histopathological examination.(Fig1a,b) Group B CO2 laser ablation was used (Lasers at- CO2 satelac, France) at an average power of **6-10 watts** in a non-contact mode. The spot size varied from 2.3 mm in diameter with ablation power density **474-950 watts sq.** cm and fluence of **120-600 m joules/pulse.** The beam was directed towards a suitable margin of 2-3 mm within this marginal outline was done. (Fig.2a,b)



Moist gauze was used to wipe away the treated area of mucosa and raw area left to undergo healing by secondary intention. The patient was asked to rinse the mouth with warm dilute saline mouth rinses 4-6 times per day. All times during the treatment and follow up patients were introduced to report any change in signs and symptoms.(Fig1c,2c)

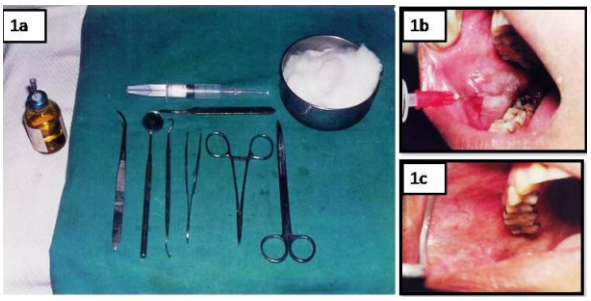

After the management, healing was comparatively assessed and evaluated at regular intervals (Ist postoperative day, 1st postoperative week, Ist and 3rd postoperative month).The cases were comparatively assessed and evaluated under the following parameters: pain, slough, scarring, recurrence and infection. (Fig.1c,2c)The method of recording post-operative pain was using visual analog scale.

Statistical analysis

The result values were tabulated using Microsoft excel spread sheets. Chi-square test was used to check fitness of sample randomization. Student t test was employed to compare pre-op and post-op complications in both the groups.

Results

Total number of sixty patients was included in this study. Homogenous leukoplakia was the most common variant seen in both the groups. Table 1 shows the demographic details of patients included in the study.

Table 1: shows the distribution of patients according to gender, age, clinical variant, site and shape

Group	Gender	Age Age	Clinical variant			Site				Size (cm2)			
	Males	>30	Homogenous	Nodular	Erosive	Dorsum of tongue	Buccal mucosa			<2	2-4	4-6	>6
							R	L	Bilateral				
Group A	18	18	21	03	01(4)	2	7	8	8	10	7	6	2
Group B	07	08	09	01	00(0)	1	2	4	3	6	2	2	0
P value >0.05(NS: non significant; S: significant)													

Table 2: shows the details of post operative complications in both the groups.

Table 2 shows the post operative complications

Group	Post op complications								
	Pain	Swelling	Slough						
	After 1day	After 1 week	After 1month	After 1day	After 1week	After 1month	After 1day	After 1week	After 1month
Group A	16	12	0	18	18	0	19	19	0
Group B	3	0	0	0	0	0	1	1	0
P value	0.37 NS	0.43 NS	0.03 NS	0.001 S	0.001 S	-	0.013 S	0.013 S	-

Discussion

Felix WK Chu et al. (1988) was the pioneer who reported that the CO2 laser provided a new approach in the management of Leukoplakia with very low morbidity and improved control.[8] Ishii et al. (2003) reported CO2 to have many advantages in the treatment of oral leukoplakia. It has been reported that rate of recurrence was 7.7-38.1% while malignant transformation was 2.6-9% for oral leukoplakia treated with laser surgery.[4]

In the present study, majority of patients were in the age group 40-50 years when taken the mean of the age groups which was in accordance with the previous studies.[3,4,6] In our study, 71.43% of subjects were males which was consistent with the findings of previous surveys.[6,8]. There were 10 (40%) cases in Group A and 6 (60%) cases in Group B with lesions measuring >2 cm which was incidentally the size category of maximum number of patients. Homogenous leukoplakia was seen in majority of cases (30/35). Maximum number of patients presented with duration of illness within 6-11 years. This could be due to the growing trends of deleterious habits (tobacco chewing, pan chewing, pan masala chewing, smoking) from early age as prevalent in this region. [3,4,9,10]

Pain was more in excision cases as it could be attributed to greater amount of tissue involvement causing exposure of larger amounts of nerve endings. Post-operative pain in CO2 lasers was comparatively less which probably relates to decreased tissue trauma and alteration of neural transmission due to sealing of the nerve endings. Swelling was seen in 18 (72%) cases of Group A on the first post-operative day and first post-operative week interval. However, no swelling was seen in cases of Group B.

Post-operative scarring index was higher in Group A compared to Group B.The observation of Luomanen et al. saw less activity of myofibroblasts in healing wounds of CO2 lasers compared to scalpel incision wounds of the oral mucosa.[11] No case of infection was reported from any of the two groups during the study due to minimal damage of the adjacent tissue. There is maintenance of wound sterilization which reduces risk of post-operative infection in case of CO2 laser. No case of recurrence was reported.

Summary

It was apparent that male ratio was more predominant than female ratio in the prevalence of oral leukoplakia. Majority of the patients were in the age group 41-50 years while the smallest age registered was 18 years. Homogenous leukoplakia was abundant in the study in both the group samples which was regarded as a good prognosis due to its less chances of malignant transformation.

It was distinguished that buccal mucosa was more prevalent as the common site of the lesion where as 2 cm2 was the size category amongst the registered samples. Pain, swelling, sloughing, scarring and recurrence of the lesion were least in CO2 laser treated cases compared to cases treated with scalpel excision.

Conclusion

Through the results of the present study we can infer that CO2 laser supersedes conventional scalpel in terms of better intra-operative hemostasis and reduced scarring.

Legends for figures & tables

Table 1: shows the distribution of patients according to gender, age, clinical variant, site and shape
Table 2: shows the post operative complications
Fig 1a: instruments used for group A
Fig.1b: preoperative photograph of patients presenting with oral leukoplakia
Fig.1c: post operative photograph
Fig 1a: instruments used for group B
Fig.1b: preoperative photograph of patients presenting with oral leukoplakia
Fig.1c: post operative photograph

References

1. Lodi G, Sardella A, Bez C, Demarosi F, Carrassi A. Systematic review of randomized trials for the treatment of oral leukoplakia. J Dent Educ 2002; 66:896–902

VOLUME-6 | ISSUE-2 | FEBRUARY-2017 • ISSN No 2277 - 8179 | IF : 3.508 | IC Value : 78.46

2. Lodi G, Porter S. Management of potentially malignant disorders: evidence and critique. J Oral Pathol Med 2008; 37:63-9
3. Chandu A, Smith AC. The use of co2 laser in the treatment of oral white patches: outcomes and factors affecting recurrence. Int J Oral Maxillofac Surg 2005; 34: 396-400
4. Ishii J, Fujita K, Komori T. Laser surgery as a treatment for oral leukoplakia. Oral Oncol 2003; 39(8):759-769.
5. Yang SW, Tsai CN, Lee YS, Chen TA. Treatment outcome of dysplastic oral leukoplakia with carbon dioxide laser- emphasis on the factors affecting recurrence. J Oral Maxillofac Surg 2011; 69(6): 78-87
6. Tuncer I, Ozçakir-Tomruk C, Sencift K, Cölo lu S.Comparison of conventional surgery and CO2 laser on intraoral soft tissue pathologies and evaluation of the collateral thermal damage. Photomed Laser Surg 2010; 28(1):75–9.
7. Hamadah O, Thomson PJ. Factors affecting carbon dioxide laser treatment for oral precancer: a patient cohort study. Lasers Surg Med 2009; 41(1):17–25
8. Carbone M, Goss E, Carozzo M, Castellano S, Controntto D, Broncoletti R, et al.. Systemic and topical corticosteroid treatment of oral lichen planus: a comparative study with long term follow-up. J Oral Pathology Med 2003;32:323-329.
9. Deppe H, Hillemanns M, Hauck W. Recurrence rates of premalignant lesions after CO2 laser resection. Med Laser Appl 2004; 19(1):55–60.
10. Wang CP, Chang SY, Wu JD, Tai SK. Carbon dioxide laser microsurgery for tongue cancer: surgical techniques and long-term results. J Otolaryngol 2001; 30(1):19–23.
11. Luomanen M. Experience with a carbon dioxide laser for removal of benign oral soft-tissue lesions.1992; Proc Finn Dent Soc 88:49-55.