Volume : 3 | Issue : 2 | February 2014 • ISSN No 2277 - 8179

Research Paper

Treatment of Recalcitrant Warts by Contact Immunotherapy Using Diphenylcyclopropenone (Dpcp)

Medical Science

KEYWORDS : diphenylcyclopropenone, immunotherapy, facial warts, palmoplantar warts

Dr Yuvraj More	Department of Dermatology, Smt. Kashibai Navale Medical College, Narhe, Pune 411041.
Dr Swapna Khatu	Department of Dermatology, Smt. Kashibai Navale Medical College, Narhe, Pune 411041.
Dr Neeta Gokhale	Department of Dermatology, Smt. Kashibai Navale Medical College, Narhe, Pune 411041.
Dr Deepali Chavan	Department of Dermatology, Smt. Kashibai Navale Medical College, Narhe, Pune 411041.

ABSTRACT

Introduction: Warts are common benign tumors of the skin. Warts, specially periungual, palmoplantar and facial are highly recurrent, and thus present a treatment challenge. We have decided to evaluate DPCP in treating resistant and multiple facial warts, periungual and plamoplantar warts to assess the effectiveness of this alternative treatment modality. Methodology: Total 45 patients with recalcitrant facial warts, palmoplantar and/or periungual warts were included in the study. The DPCP solution of concentration 2% for adults and 1% for pediatric patients was applied on lesion to induce sensitization. In sensitized patients low concentration was applied initially (0.001%) which was gradually increased up to 2% until a mild eczematous reaction was noticed. Results: Out of total 29 patients suffering from facial warts, 20 (68.96 %) cases improved completely. And out of 14 patients suffering from recalcitrant hand and foot warts, 11 (78.57%) patients improved completely. Conclusion: The results of our study indicate that DPCP is an effective, safe, well tolerated and preferred treatment option for periungual warts and can be considered as treatment option for multiple facial warts

Introduction-

Warts are common benign tumors of the skin caused by the infection of human papilloma virus. Recurrent skin and palmoplantar warts may be disfiguring impose a considerable psychological burden, and a frequent cause for medical office visit. Most of the lesion show spontaneous regression but some may increase in number and size which may interfere with daily activities. Warts, specially periungual, palmoplantar and facial are highly recurrent, and thus present a treatment challenge. A wide range of treatment modalities have been used for warts including cryotherapy[1] , LASER therapy[2] electrosurgery, chemical cauterisation, intralesional bleomycin[3], 5 flurouracil, photodynamic therapy, immunotherapy etc. while many of the treatment modalities have limitation in practice due to pain and scarring especially for facial, palmoplantar and periungual warts. Recent reports have demonstrated that topical immunotherapy with diphenylcyclopropenone (DPCP) is a safe and effective treatment modality of recalcitrant wart[4] which includes facial warts for absence of scarring and palmoplantar, periungual warts for painless removal and absence of scarring. Thus we decided to evaluate DPCP in treating resistant and multiple facial warts, periungual and plamoplantar warts to assess the effectiveness of this alternative treatment modality.

Methodology-

Total 45 patients with recalcitrant facial warts, palmoplantar and/or periungual warts were included in the study. Pregnant female, lactating mother, immunocomprmised patients and patients below 10 years of age and above 70 years of age were excluded from the study. After informed written consent of patients or their parents (in case of minor) all recruited subjects were treated with DPCP immunotherapy. The DPCP solution of concentration 2% for adults and 1% for pediatric patients was applied on upper inner arm to induce sensitization. It was confirmed to have occurred on the week following, when the application site showed eczematous conditions, which were represented by an erythema and/ or mild oozing. After sensitization has occurred solution of DPCP was applied to the warts to induce a low grade inflammatory reaction. Initially low concentration was applied (0.001%) which was gradually increased up to 2% until a mild eczematous reaction was noticed. DPCP was applied onto the lesions weekly. The concentration of DPCP was adjusted depending on the severity of the inflammatory reaction from the previous application. If the reactions were severe enough to have bullae or severe oozing, the concentration was lowered. The concentration was elevated when the reaction from the previous application was too weak to produce desired results. The desired target concentration was the initial point when erythema, mild itch and/or mild oozing were observed. The number of applications was restricted to no more than ten weeks.

We assessed the results of the treatment as 'success' or 'failure.' A 'success' was clinically defined as when all lesions were completely cleared, and 'failure' was considered in one of the following three conditions: (i) if a patient had not been sensitized; (ii) if a proper reaction had not occurred on the wart lesions that were treated with DPCP for 3 consecutive weeks in a sensitized patient; (iii) if clinical improvement had not been observed for 10 consecutive weeks, although a proper reaction of DPCP application had occurred;

Results-

Total 45 patients were sensitized to DPCP during study period. Seven patients defaulted from the study. Of the remaining 38 patients, 24 were males and 14 were females. The mean age was 24.5 years (ranging from 20 to 43). 24 patients were suffering from facial warts, 9 patients were suffering from palmoplantar and / or periungual warts and 5 patients were suffering from both. Out of total 29 patients suffering from facial warts 20 (68.96 %) cases improved completely (Figure1A&B). And out of 14 patients suffering from recalcitrant hand and foot warts 11 (78.57%) patients improved completely.(Figure 2 A&B) The median time for clearance of wart was 7.4 weeks. Success rates decreased as the duration of disease increased- 100% (duration less than 6 months), 68% (duration 6 months to 1year) and 55% (duration more than 1 year). Adverse effects occurred in 23 of 38 patients (60.52%), most commonly intense pruritus (n=17), painful local blister- mainly observed in facial warts (n=11), blistering at site of sensitization (n=6), pompholyx like reaction (n=4), eczematous eruption (n=3). Five of those who defaulted did so due to side effects while two dropped out for unknown reason.

Discussion-

Viral warts are benign tumors caused by human papillomavirus infection, and its prevalence among general population is reported to be 7% to 10%.[5,6] Although spontaneous resolution is

observed in most cases, treatments are required in some cases with increasing size and number. Periungual, palmoplantar and facial warts, particularly, behave recalcitrant to treatments and become cosmetic problems and distress to daily life in many cases.[7]

Wide variety of treatment modalities is available for treatment of warts like radiofrequency, cryotherapy[1], 5 flurouracil, chemical cauterization, keratolytic agents, photodynamic therapy, LASER therapy[2], intralesional bleomycin[3], hypnosis, levamizole, cimetidine[8], retinoids etc many of these treatments have limitations in practice. Periungal warts are difficult to treat because involvement of nail fold and / or nail bed increases the possibility of damaging or deforming the nail apparatus, including matrix, nail bed or underlying bone and recurrence is very commonly observed[7]. Palmoplantar warts are highly contagious, recalcitrant and chances of painful scarring after treatment is high. Multiple facial warts is cosmetically damaging, recurrence is very high[9]. So choosing a proper treatment plan is very important.

Topical immunotherapy for warts was first described by Lewis[10] in 1973, when warts cleared after the application of universal allergic contact sensitizer dinitrochlorobenzene (DNCB) in previously sensitized subjects. DNCB is no longer used in clinical practice due to its mutagenic potential. DPCP was first reported to successfully treat patients with resistant plantar warts in 1984 and since then, there have been several other reports of recalcitrant warts, including periungual, palmoplantar and facial warts, which were successfully treated with DPCP[11].

It has been reported to have a high response rate, absence of scarring and painless application. Immunotherapy has many advantages: multiple lesions can be treated simultaneously, and frequency and size of relapsing warts are much reduced. DPCP may bind to wart protein and subsequently induce a specific immune reaction. An immune mechanism seems to be confirmed by the fact that untreated warts can also be rejected[9].

Our cure rate for facial wart was 68.96% which is comparable to study conducted by Aghaei S 2006, which was 66.6%.[9] While our cure rate for hand foot warts is 78.57% which is comparable to study conducted by Choi Y et al in 2013, he reported clearance in 85% of cases[7], Upitis JA in 2002, he reported clearance of 87.7% [4] and to study conducted by Buckley et al in year 1999, he reported clearance rate off 88%[12]. In study conducted by Rampen FH in 1996, however clearance rate was slightly less that is 60%[13].

We observed 100% improvement in warts when duration of disease was less than 6 months, thus as duration of disease increased, success rate decreased. Treatment period for the lesions less than 6 months was significantly lower than those for above 6 months. This finding is comparable with Y choi et al, he also reported 100% success rate when duration of warts was less than 6 months[7].

Potential side effects of topical immunotherapy are not significant, most of involve blistering at the sensitization and application site[7]. Distant or more widespread eczematous eruptions also occur, but such reactions usually disappear with topical steroids[13,14]. More rarely contact urticaria[14], erythema multiforme like reactions[15], influenza like symptoms[16] have been reported as well. We observed adverse effects in 60.52% of patients most common being intense itching. Buckely et al reported adverse effects in 56% of cases comparable to our study[12]. Pruritus is commonly noted side effect by Upitis JA[4], this finding is consistent with our study.

Possible dreaded side effect is that this particular form of chronic immunostimulation may induce onset of lymphomas even after a long period of time, this problem arises more commonly with the treatment of alopecia areata than with the brief period of treatment for warts[9].

Conclusion-

The results of our study indicate that DPCP is an effective, safe, well tolerated and preferred treatment option for periungual warts. Immunotherapy with DPCP should not be used routinely as first line of treatment for facial warts but should be regarded as a safe and effective alternative in patients suffering from recalcitrant and multiple facial warts.

As total numbers of patients are less, we would like to conduct this study with more number of subjects. We would also like to do follow up of these patients for 6 months duration to look for recurrence of lesions.



Figure 1 A



Figure 1 B

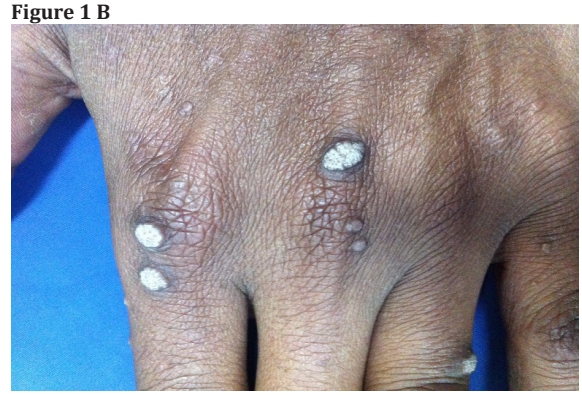

Figure 2 A



Figure 2 B

REFERENCE

1. Kuflik EG. Specific indication for cryosurgery of the nail unit. Myxoid cysts and periungual verrucae. J Dermatol Surg Oncol 1992;18:702-706. | 2. Oni G, Mahaffey PJ. Treatment of recalcitrant warts with carbon dioxide LASER using an excision technique. J Cosmet Laser Ther 2011;13231-236. | 3. Munn SE, Higgins E, marshall M, Clement M.A new method of intralesional bleomycin in the treatment of recalcitrant warts. Br J Dermatol 1996;135:969-971. | 4. Upitis JA, Krol A. The use of diphenylcyclopropenone in the treatment of recalcitrant warts. J Cutan Med Surg 2002;6:214-217. | 5. Laurent R, Kienzler JL. Epidemiology of HPV infections. Clin Dermatol 1985;3:64-70. | 6. Aum HS, Kim YH, Kim DH. Study of pulsed dye laser followed by intralesional bleomycin treatment compared to lone intralesional bleomycin treatment for recalcitrant periungual warts. Korean J Dermatol 2006;44:45-50. | 7. Choi Y, Kim do H, Jin SY, Lee AY, Lee SH. Topical immunotherapy with diphenylcyclopropenone is effective and preferred in the treatment of periungual warts. Ann Dermatol 2013;25:434-439. | 8. Gooptu C, Higgins CR, James MP. Treatment of viral warts with cimetidine : an open –label study.Clin Exp Dermatol 2000;25:183-185. | 9. Aghaei S . Treatment of disseminated facial warts through contact immunotherapy with | diphencyclopropenone (DPCP). Dermatol Online J 2006;12:10 | 10. Lewis HM. Topical immunotherapy of refractory warts. Cutis 1973;12:863-867. | 11. Wiesner-Menzel L, Happle R. Regression of plantar warts following treatment with diphencyprone. 1984;59:1080-1083 | 12. Buckely DA, Keane FM, Munn SE, Fuller LC, Higgins EM, Du Vivier AW. Recalcitrant viral warts treated by diphencyprone immunotherapy. Br J Dermatol 1999;141:292-296. | 13. Rampen FH, Steijlen PM. Diphencyprone in the management of refractory palmoplantar and periungual warts: an open study. Dermatology 1996;193:236-238. | 14. Lane PR, Hogan DJ. Diphencyprone. J Am Acad Dermatol 1988;19:364-365. | 15. Puig L, Alegre M, Cuatrecasas M, De Moragas JM. Erythema multiforme-like reaction following diphencyprone treatment of plane warts. Int J Dermatol 1994;33:201-203. | 16. Monk B. Induction of hair growth in alopecia totalis with diphencyprone sensitization. Clin Exp Dermatol 1989;14: 154-157. |