Volume : 5 | Issue : 10 | October 2016 • ISSN No 2277 - 8179 | IF : 3.508 | IC Value : 69.48

Tuberculer Osteomyelitis of 1St Metatarsal Bone Right Foot

Medical Science

KEYWORDS :Tuberculosis;Metatarsal; Foot; Child

Dr. Sahil Sarwal	PG Resident, Department Of Orthopaedics, Maharishi Markandeshwar Institute of Medical Sciences and research , Mullana, Ambala (Haryana)
Dr. Manjeet Singh	Professor and Head Of The Department, Department Of Orthopaedics, Maharishi Markandeshwar Institute of Medical Sciences and research , Mullana, Ambala (Haryana)
Dr. Rakesh Kumar Gautam	Associate Professor,Department Of Orthopaedics, Maharishi Markandeshwar Institute of Medical Sciences and research , Mullana, Ambala (Haryana)
Dr. Sartaj Singh Gill	Senior Resident, Department Of Orthopaedics, Maharishi Markandeshwar Institute of Medical Sciences and research , Mullana, Ambala (Haryana)
Dr. Jaiveer Singh Hunjan	PG Resident, Department Of Orthopaedics, Maharishi Markandeshwar Institute of Medical Sciences and research , Mullana, Ambala (Haryana)
Dr. Mankaran Singh Arora	PG Resident, Department Of Orthopaedics, Maharishi Markandeshwar Institute of Medical Sciences and research , Mullana, Ambala (Haryana)

ABSTRACT

Tuberculer osteomyelitispresents 1.7–2% of all tuberculosis (TB). The localization in the foot is rare and accounts for less than 10% of TB osteomyelitis.

The following report describes the case of a 12-year-old boy who presented with a gradually increasing swelling and sinus over the medial and anterior aspect of the right foot. X-ray of his right foot showed an osteolytic image at the 1st metatarsal. Diagnosis was confirmed by the presence of a tuberculoid granuloma with caseous necrosis on bone biopsy.

Case report:

A 12-year-old boy presented with complaint of pain in his right foot associated with a gradually increasing swelling and presence of discharging sinus over the lateral and anterior aspect of the right midfoot. These symptoms began 4 months ago in the context of fever and pus discharging from sinus. His previous medical history reveals that patient got operated (curettage and excision) twice from some other institute in last 4 months.

Biologically, a hemogram showed hyperlymphocytosis and an erythrocyte sedimentation rate (ESR) that was found to be elevated with a value of 65 mm after one hour, CRP was found to be positive with raised TLC. Human immunodeficiency virus (HIV) was found to be negative.

Radiographs of the right ankle with foot showed an osteolytic lesion of the 1st metatarsal (Fig. 1). Figure shows clinical presentation of right foot (Fig. 2.). The chest radiograph was normal. MRI (Fig.4.) of foot revealed a lytic lesion measuring involving the head, proximal shaft and base of first metatarsal and a sequestrum within the bone with preliminary diagnosis of active tubercular osteomyelitis open biopsy (Fig.3.) and wound debridement was planned. A formal dorsal approach to the first metatarsal was employed. The medullary cavity was found to be filled with caseous material with thinning of the overlying cortex. The cavity was thoroughly curetted, sinus tracts were excised and the samples were sent for histopathological and microbiological work-up. Under the microscope, extensive areas of caseous necrosis surrounded by lymphocytes and epitheloid cells were observed, which is typical of tubercular pathology (Fig.3)

Considering the possibility of contagious tuberculous (his father was treated for pulmonary tuberculosis [TB]) and the fact that he was in an endemic area, the diagnosis of bone TB was considered.



Fig. 1. Anterior and oblique radiograph of the right foot with ankle showing an osteolytic lesion of the calcaneus

Volume : 5 | Issue : 10 | October 2016 • ISSN No 2277 - 8179 | IF : 3.508 | IC Value : 69.48





Fig. 2.Clinical presentation of right foot showing multiple sinuses.

Aspiration of the small swelling did not find the presence of acid fast bacilli (AFB). Curretage and excision was done . Excised sequestrum was sent for histopathological examination showed an epithelioid granuloma and giant cells with caseous necrosis (Fig. 3).

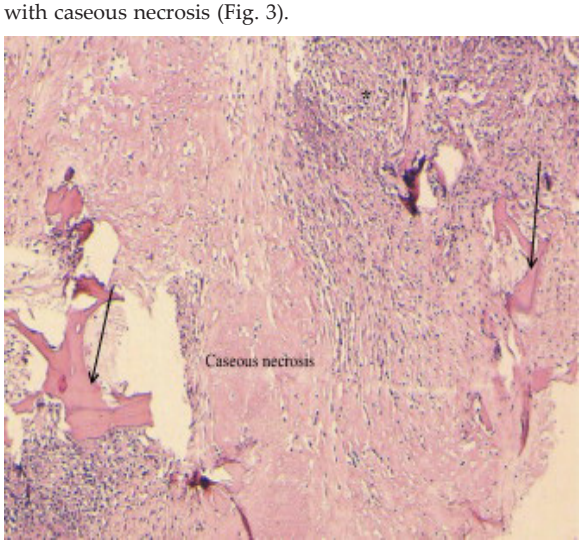

Fig. 3. Bone trabeculae dissociated (arrow) by the beaches of epithelioid granuloma with caseous necrosis and giant cell.

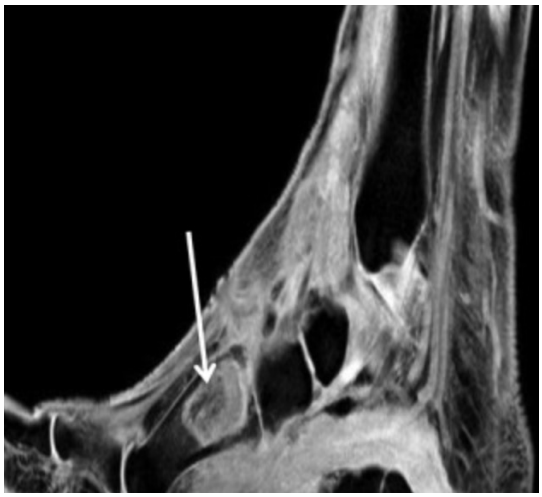

Fig 4 Scan of MRI.



Fig 5 :- Showing healing of ulcers

He was started on an anti-tubercular regime comprising of four drugs (Isoniazid, Rifampicin, Pyrazinamide and Ethambutol) daily for 2 months followed by two drugs (Isoniazid and Rifampicin) daily for 10 months. Pt was given below knee slab support and advised non-weight-bearing walking for 6 weeks, followed by partial weight bearing with walking boot for another 6 weeks. Patient is currently in the follow-up and 12 months planned treatment with healing sinuses (Fig.5.) and no fresh complaints. There was a decrease in ESR count , TLC and CRP was found to be negative after 6 months of anti-tuberculer drugs.

Introduction:

Tuberculer osteomyelitis of the 1metatarsal is extremely rare and accounts for less than 0.65%-6.9%(3)of osteoarticular TB[1]. The diagnosis is often made at a late stage. This study reports a rare example of a12-year-old boy who presented with a rare localization of extra-pulmonary TB with osteomyelitis located at the foot involving the 1st metatarsal to draw attention to this exceptional location in children and an atypical presentation of a clinical observation.

Discussion:

Bone TB is a leading cause of morbidity and mortality in many developing countries and actually in the entire world due to the increased incidence of TB in HIV-positive patients. Its incidence has been relatively stable since 1994, with 300,000 new cases per year [1].

Osteoarticular TB represents 1.7–2% of all forms of TB. It is the third amongst extrapulmonary TB after the peritoneal

and lymph node forms of TB. It is a disease that must be diagnosed quickly before the disease progresses and injures or destroys the bone or joint.

In osteoarticular TB, the spine and hip are the most commonly affected areas.About 10% of osteoarticular. TB is known to affect the foot bones with calcaneum being the commonest followed by metatarsals and phalanges [2]. The literature review suggests an incidence of <0.5% for metatarsal osteomyelitis[3], among which first and fifth are frequently involved[4]. The calcaneus is most often affected, but only calcaneal localization without joint involvement is extremely rare that also with osteomyelitis, and diagnosis is often made at a late stage because osteoarticular TB is paucibacillary and it is difficult to isolate or cultivate the Koch bacillus.

Clinical manifestations of TB metatarsals include chronic foot pain, swelling, difficulty in walking and in long-standing cases, discharging sinuses/wound and pathological fractures. Constitutional symptoms such as weight loss, loss of appetite and fever are seldom seen[5].Radiologically, the common sign is a cystic lesion without sequestrum, but a bone sclerotic appearance can be observed.five types of bone lesions for osteoarticular TB of foot bones are described: cystic, rheumatoid, kissing, subperiosteal and spina ventosa [1]. Among these, TB metatarsal can present with cystic or spina ventosa like picture. CT and MRI play an important role in its early diagnosis[6]. Biological examinations help in diagnosing the disease with elevated ESR and c-reactive protein (CRP). The tuberculin intradermal reaction (IDR) can be negative. Isolation of Mycobacterium TB and its culture are difficult because osteoarticular TB is paucibacillary[7].

The diagnosis of TB must be concluded in the face of a cystic lesion of the bone with blurred boundaries and sclerosis minimal peripheral. Biopsy of the cystic lesion is an essential step to make a positive diagnosis. The only confirmatory test is isolation of the acid-fast bacillus (AFB).

The search of other localisations of pulmonary and extrapulmonary TB is systematic.

TB treatment is the basis of treatment for a period of 9–12 months with treatment of osteomylitis. Surgery may be indicated as a debridement, curettage or excision of a sequestrum [8] . A bone graft can be performed before the apparition of a loss of bone [9], [10], [11] and [12]. The plaster immobilization is recommended [13] and [14]. The course and prognosis depend on an early diagnosis and therapeutic management.

Conclusion:

The location of TB at the 1st meta-tarsal is rare. The diagnosis should be suspected in view of clinical and radiological signs, especially in endemic countries.

The rarity of the lesion and its atypical presentation make the diagnosis of TB osteomyelitis of the 1St metatarsal very difficult based on clinical criteria. The clinical observations of this case highlight the unusual skeletal manifestations of TB and should be considered to prevent delay in diagnosis and therapeutic management.

Consent:

Written and informed consent was obtained from patient and his parents explaning all pros and cons .

References:

1. Gyanshankar PM, Dhamgaye TM, Amol BF. Spina ventosa discharging tubercle bacilli--a case report. Indian J Tuberc. 2009;56(2):00–3.
2. Mittal R, Gupta V, Rastogi S. Tuberculosis of the foot. J Bone Joint Surg Br 1999;81:997–1000.
3. Tuli SM. Tuberculosis of the Skeletal System: Bones, Joints, Spine and Bursal Sheaths. New Delhi: Jaypee Brothers, 2004.
4. Narang S. Tuberculous osteomyelitis of the metatarsals: a report of two cases and literature review. JBJS Case Connect 2012;3:40–1.
5. Yuen MC, Tung WK. An uncommon cause of foot ulcer: tuberculous osteomyelitis. Emerg Med J 2001;18:140–1.
6. J.C. Yombi, B. Vandercam, O. Cornu Tarsal osteoarthritis: a rare localisation of tuberculosis Rev. Chir. Orthop. Reparatrice Appar. Mot., 93 (7) (2007), pp. 740–745.
7. M.B. Werd, F.J. Masson, A.S. Landsman Peripheral skeletal tuberculosis of the foot. Etiologic review and case study J. Am. Podiatr. Med. Assoc., 84 (1994), pp. 390–398.
8. S.M. Tuli Tuberculosis of the Skeletal System (second ed.)Jaypee Brothers Medical Publishers (P) Ltd, New Delhi (1991) pp. 3–122.
9. V. Arlet, P. Rigault, J.P. Padovani Aneurysmal bone cysts in children: a study of 28 cases Rev. Chir. Orthop. Reparatrice Appar. Mot., 73 (1987), pp. 337–348.
10. K. Kumar, M.B. Saxena Multifocal osteoarticular tuberculosis Int. Orthop., 12 (1988), pp. 135–138
11. A.A. Freiberg, R.T. Loder, K.P. Heidelberger, R.N. Hensinger Aneurysmal bone cysts in young children J. Pediatr. Orthop., 14 (1994), pp. 86–91.
12. F.A. Khan Aneurysmal bone cyst: the role of fibular graft in its treatment Ann. Saudi Med., 15 (6) (1995), pp. 566–569
13. H.G. Watts, R.M. Lifeso Current concepts review: tuberculosis of bones and joints (78-A:288–298, Feb. 1996) by Watts and Lifeso J. Bone Joint Surg. Am., 80 (4) (1998), p. 604.
14. J.P. Eschard, J. Leone, J.C. Étienne Tuberculose osseuse et articulaire des members Encycl. Med. Chir. Appar. Locomot., 14 (185-A-10) (1993), p. 5.