ORIGINAL RESEARCH PAPER

Volume-7 | Issue-4 | April-2018 | PRINT ISSN No 2277 - 8179

INTERNATIONAL JOURNAL OF SCIENTIFIC RESEARCH

ULTRASONOGRAPHY OF THE THYROID LESIONS CORRELATED WITH FNAC

Radiodiagnosis

Dr Raj G Bumiya MD,Assistant Professor, Department of Radiodiagnosis, Parul Institute of Medical Sciences and Research, Limda,Vadodara, Gujarat-391760

Dr Roopa* MD, Assistant Professor, Department of Radiodiagnosis, Christian Medical College, Vellore, Tamilnadu, India-632004.* Corresponding Author

ABSTRACT

Introduction : The thyroid gland is one of the largest endocrine glands. Current management guidelines (American Thyroid Association) state that diagnostic ultrasonography (USG) should be performed in all patients with thyroid disease and fine needle aspiration (FNA) in potentially malignant nodules.

Materials and Methods : This prospective study included 50 patients presenting with thyroid gland related complaints over a period of two and half years. Gray scale ultrasound of neck followed by USG guided FNAC of thyroid swelling was done.

Results : Mean age of presentation was 37.5 years with female preponderance. Benign pathology was observed in 90% cases, amongst which the commonest was goitre (66%). Malignancy accounted for 10% of cases out of which commonest was papillary carcinoma.

Conclusion : Sonographic findings can be useful when used along with cytology in the assessment of thyroid nodules and their likelihood of malignancy

KEYWORDS

FNAC, Goitre, Thyroid, USG.

Introduction

The thyroid gland is one of the largest endocrine glands and is affected by many benign and malignant lesions. Thyroid disorders can be divided into nodular thyroid disease and diffuse thyroid disease. Various congenital conditions may affect the thyroid gland which includes agenesis, hypoplasia and ectopia. Epidemiologic studies estimate that 4-7% of adult population in United States have palpable thyroid nodules, women being more frequently affected than men. Exposure to ionizing radiation increases the incidence of benign and malignant nodules, with 20-30% of radiation exposed individuals having palpable thyroid nodules.

It has been estimated that 15% to 60% of the asymptomatic population have a thyroid nodule found incidentally on sonography, yet only around 8% to 10% of these nodules will represent malignant disease on further workup [1]. The majority of these cases are clinically occult but readily detected by high-resolution Ultrasonography (USG). The advantages of ultrasound are that it is an easily accessible, inexpensive, devoid of radiation, non-invasive and highly sensitive imaging modality for distinguishing cystic from solid lesion. Colour Doppler study helps in assessment of blood flow in addition to depiction of the morphology.

Various sonographic features that have been identified in previous studies which are suggestive of malignancy include marked hypoechogenicity, noncircumscribed margins, microcalcifications, and taller-than-wide shape and intranodular vascularity [2][3][4]. There have been a few reports that evaluated the diagnostic performance of Doppler Ultrasound in assessment of thyroid malignancy. Currently much debate exists as to whether such features have been successfully identified [2][3]. Some authors claim that intranodular vascularity is useful for predicting thyroid malignancy, while others demonstrate that intranodular vascularity does not help predict thyroid malignancy.

In the absence of reliable clinical or sonographic signs to distinguish benign from malignant thyroid nodule fine-needle aspiration cytology (FNAC) has assumed a prominent role in the management of thyroid nodule. It has been found that FNAC is a safe, reliable and cost effective diagnostic modality with a high sensitivity of 83.3% and specificity of 100%; and is the single best investigation for preoperative evaluation of thyroid nodule to differentiate between benign and malignant nodules [5]. The current management guidelines (American Thyroid Association) state that diagnostic USG should be performed in all patients with thyroid disease and fine needle aspiration (FNA) in potentially malignant nodules. Thus this study was undertaken with an aim to prove USG as the best first line investigation for thyroid lesions supported by FNAC correlation.

Materials and Methods

This prospective study was carried out on patients who were referred to the Department of Radiology, Medical College and SSG Hospital Vadodara, for the evaluation of suspected thyroid lesions. These cases were collected over a period of two and half years from May 2010 to November 2012. Patients with physical examination suggestive of palpable thyroid swelling in lower neck in midline or on either side and sign and symptoms suggestive of thyroid disorder (Hyper/ Hypothyroidism) were included. Patients already diagnosed and treated for thyroid lesions and FNAC showing inadequate aspirated material were excluded from the study. Based on above inclusion and exclusion criteria and the statistical calculation based on previous studies a total of 50 patients were studied. The detailed medical history of the patient including the personal information, presenting complaints, and other relevant history were taken.

Patients selected on the basis of above mentioned criteria were subjected to a detailed gray scale ultrasound and Colour Doppler of thyroid on Esaote MyLab 40 and Philips iu22 Ultrasound machines. A linear array transducer of centre frequency 7-17 MHz was used. Images were recorded using JPEG images. During the ultrasound examination of the thyroid gland the measurement of right lobe, left lobe and isthmus was taken. Echotexture of thyroid gland was noted. If any lesion was seen, it was studied for size, shape, number, single or multiple, margins whether well-defined or ill defined, solid or cystic nature was studied. Also noted was the calcification, comet-tail artifact. Great vessels were studied for the flow and any lymphadenopathy was also reported. USG guided FNAC was done by free hand technique from the least vascular and solid area of the lesion. The ultrasound findings were correlated with the histopathological findings.

Results

In our prospective study of 50 patients, the mean age of presentation was 37 years, ranging from seven to 72 years. Majority of the cases were seen in 30-39 age group, having 28% of the total cases. There were 43 female patients and remaining seven were male patients. Male to female ratio was 1:6, with females being more commonly affected than the males. The common clinical presentation was thyroid gland enlargement followed by pressure effects. The most common clinical diagnosis was diffuse thyroid swelling followed by nodular swelling.

Table 1: Distribution of Cases according to Age

Age Group	No of Patients	Percentage (%)
00-09	01	02
10-19	04	08
20-29	10	20
30-39	14	28
40-49	07	14
50-59	10	20

60-69	03	06
70-79	01	02
Total	50	100

Table 2: Clinical Symptomatology of the cases

Clinical Symptoms	Patients	Percentage (%)
Thyroid Enlargement	49	89
Pressure effects	07	14
Signs of Hyperthyroidism	03	06
Pain	03	06
Pedal edema	01	02
Weight gain	01	02
Weight loss	01	02

Table 3: Clinical Diagnosis of Thyroid Disease

Clinical Diagnosis	Number of Patients	Percentage (%)
Diffuse Thyroid Swelling	29	58
Nodular Swelling	20	40
No Swelling	01	02
Total	50	100

Out of the 50 patients studied with ultrasound, 45 had benign lesion and five of the remaining cases were malignant. On further characterization of benign lesion using ultrasound, goitre being most common was seen in 33 cases followed by thyroiditis in eight cases and follicular adenoma in four cases. In the five cases reported as malignant based on ultrasound, three patents had papillary carcinoma and remaining each one was follicular carcinoma and secondary invasion by squamous cell carcinoma. Malignancy was seen in the age group of 20-69 with female preponderance.

Table 4: Sonographic Diagnosis of Thyroid Lesions

Sonographic Diagnosis	No of Patients	Percentage (%)
Benign Thyroid Lesion	05	10
Goitre	23	46
Thyroiditis	15	30
Follicular Adenoma	02	04
Malignancy	05	10
Total	50	100

Table 5: Pathological Diagnosis of Thyroid Lesions

Pathological Diagnosis	No of Patients	Percentage (%)
Goitre	33	66
Thyroiditis	08	16
Follicular Adenoma	04	08
Carcinoma	05	10
Total	50	100

Out of the 45 cases reported as benign on ultrasound, one case turned out to be malignant on pathological examination of FNAC sample as papillary carcinoma. This case on sonography presented as an isoechoic lesion with well-defined margin and with solid and cystic components. Due to this typical appearance it was reported as benign on ultrasound but turned out to be malignant on pathological examination. Similarly of the five malignant cases, one case was benign lesion, the colloid goitre on pathological examination but reported as malignant. This case had ill-defined margins which made us report as malignant.

Table 6: Correlation of Radiological diagnosis with Pathological diagnosis

Radiological Diagnosis		Pathological Diagnosis	
Number of cases		Benign	Malignant
Benign	45	44	01
Malignant	05	01	04
Total	50	45	05

On statistical calculation, the positive predictive value of ultrasound for malignant lesions was 80% and negative predictive value was 97.8% with an accuracy of 96%.

Most of the lesions were multiple (48%), hypoechoic (58%) with well-defined margin (92%), and solid (50%) in echo-texture. Calcification was seen in 24% cases. Out of 45 benign lesions, most benign lesions were multiple (40%), hypoechoic (52%) with well-defined margin (86%) and solid (86%) component. Majority of 23 cases of perilesional halo and all six cases of comet-tail artifact proved to be benign and seen in 51% and 13.3% of benign cases respectively. Similarly both the cystic lesions proved to be benign.

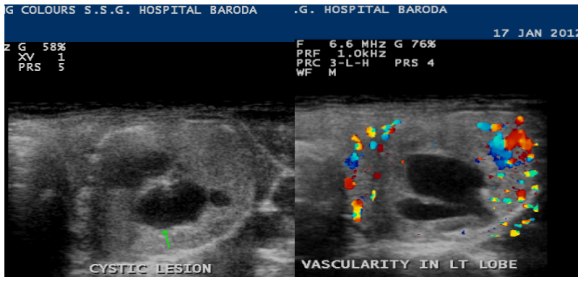

Figure 1: Goitre : solid-cystic component with increased intralesional vascularity

Out of 5 malignant cases, most of the malignant lesions were multiple (80%), hypoechoic (60%), showing calcification (40%) and solid (60%) echo-texture. Three malignant cases showed perilesional halo. None of the malignant cases showed comet-tail artifact. Well-defined margin was seen in 60% and ill-defined seen in 40% cases.

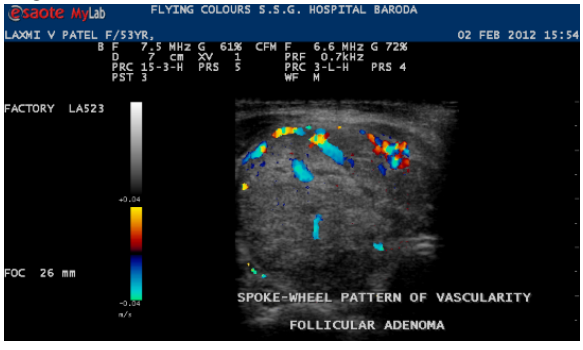

Figure 2: Follicular neoplasm – well defined hypoechoic lesion with spoke wheel pattern of vascularity

Discussion

The thyroid disorders are more common in females. Similar to the study done by I.S.Nam-Goong et al [6] (78%) and Amer A M Ali et al [7] (78%) female preponderance was seen in our study (86%). Mean age of presentation was 37.5 years in our study whereas it was 48 years in study done by Mi Jung Lee et al [8]. In our study 90% of the lesions were benign and 10% were malignant. This was similar to the study done by Joseph F Simeone et al [9], in which there were 88% benign and 12% were malignant.

In the benign lesions goitre was most common in both present and Kamaljit Kaur et al [5] study, 66% Vs 68% respectively. In our study, among the malignant lesions papillary carcinoma was seen in 60% followed by one each of follicular carcinoma and secondaries. In the study by Kamaljith Kaur et al [5] papillary carcinoma was seen seen in 88% and one patient had follicular carcinoma.

Increased intratumoral vascularity was seen in 51.1% of benign lesions and 02% of malignant lesions. This finding was seen in 65% cases in the study done by John A Bonavita et al [10] and 84 % for malignant lesions in Mahira Yunus et al [10] study. In the study by A Ahuja et al [12] all the patients with comet tail artifact proved to be benign which was similar in our study.

On comparing the sonographic findings of malignant thyroid lesions with study done by T Rago et al [13], it was seen that increased intralesional vascularity was more in their study compared to the present study, 84% and 40% respectively. Findings of irregular margin of the malignant lesions were similar in both the above and present study.

Table 7: Sonographic findings of malignant Thyroid Lesions compared with other study

Sonographic findings	T Rago et al [13]	Present Study
Malignant	30(28%)	5(10%)
Microcalcification	13(43%)	2(40%)
Absent halo	20(66%)	2(40%)
Hypoechoic (of total malignant lesions)	20(66%)	3(60%)

Several ultrasound features are associated with an increased risk of thyroid cancer like presence of calcifications, hypo echogenicity, irregular margins, predominantly solid composition and intra nodular vascularity however the sensitivities, specificities and negative and positive predictive values for these criteria are extremely variable from study to study and no ultrasound feature has both a high sensitivity and a high positive predictive value for thyroid cancer. The sensitivity and specificity of ultrasound for detecting malignant thyroid lesion of our study was comparable to that of Eisuke Koike et al [14] which was 80% and 97.8% versus 81.8% and 91% respectively.

Conclusion

Thyroid gland is affected by many benign and malignant lesions. Ultrasonography due to its excellent resolution is very sensitive in detection and characterization of lesions of the thyroid gland. The advantages of ultrasound are that it is an easily accessible, inexpensive, devoid of radiation, non-invasive and highly sensitive imaging modality for distinguishing cystic from solid lesion. Color Doppler study helps in assessment of blood flow in addition to depiction of the morphology. Real time sonography is a valuable tool to guide the needle for FNAC, especially for the small size thyroid nodule (< 1.5 cm) as well as for the aspiration of cysts. FNAC is always suggested for the final confirmation of diagnosis in sonographically detected suspicious thyroid nodule. In conclusion, sonographic findings can be useful when used alongside cytology in the overall assessment of thyroid nodules and their likelihood of malignancy.

REFERENCES

1. Mancuso AA. Another pesky incidental thyroid nodule. AJNR Am J Neuroradiol 2005 Nov-Dec;26(10):2444-5.
2. Papini E., Guglielmi R., Bianchini A., Crescenzi A., Taccogna S., Nardi F., et al. Risk of malignancy in nonpalpable thyroid nodules: Predictive value of ultrasound and Color Doppler features. J Clin Endocrinol Metab 2002; 87: 1941-1946.
3. Kim E., Park C. S., Chung W. Y., Oh K.K., Kim D. I., Lee J. T., et al. New sonographic criteria for recommending fine-needle aspiration biopsy of non-palpable solid nodule of the thyroid. AJR 2002; 178: 687-691.
4. Frates M. C., Benson C. B., Doubilet P. M., Cibas E. S., Marqusee E. Can Color Doppler Sonography aid in the prediction of malignancy of thyroid nodules?. J Ultrasound Med 2003; 22: 127-131.
5. Kaur K., Sonkhya N., Bapna A. S., Mital P. A comparative study of FNAC, USG and radionuclide scan in the management of solitary thyroid nodule. Indian Journal of Otolaryngology & Head & Neck Surgery 2002; 54: 96-101.
6. Nam Goong I S, Kim HY, Gong G., Lee HK, Hong SJ, Kim WB, et al. Ultrasonography-guided fine-needle aspiration of thyroid incidentaloma: Correlation with pathological findings. Clin Endocrinology 2003; 60:21-28.
7. Amer A M Ali, Abulkadir H Hasan, Tahir A Hawrami. Role of conventional Ultrasound in the assessment of thyroid nodules in Al- Sulaimanyia Territory. Bas J Surgery 15 ;September, 2009.
8. Lee MJ, Hong SW, Chung WY, Kwak JY, Kim MJ, Kim EK. Cytological Results of Ultrasound-Guided Fine-Needle Aspiration Cytology for Thyroid Nodules: Emphasis on Correlation with Sonographic Findings. Med J 52(5):838-844, 2011
9. Simeone J.F., Daniels G.H., Mueller P.R., Maloof F, Vansonnenberg E, Hall D.A., et al. High-resolution real-time sonoglraphy of the thyroid. Radiology 1982; 145: 431-435.
10. John A. Bonavita,Jason Mayo, James Babb, Genevieve Bennett, Thaira Oweity, Michael Macari and Joseph Yee. Pattern Recognition of Benign Nodules at Ultrasound of the Thyroid: Which Nodules Can Be Left Alone?. American Journal of Roentgenology July 2009:Vol 193: Issue 1:Pages. 207-213.
11. Mahira Yunus, Zeba Ahmed. Significance of ultrasound features in predicting malignant solid thyroid nodules: Need for fine-needle aspiration. J Pak Med Assoc. Oct 2010; 60(10):848-53.
12. Ahuja A., Chick W., King W., Metreweli C. Clinical significance of the comet-tail artifact in thyroid ultrasound. J Clin Ultrasound 1996; 24: 129-133.
13. Rago T., Vitti P., Chiovato L., Mazzeo S., De Liperi A., Miccoli P., et al. Role of conventional ultrasonography and Color Flow Doppler Sonography in predicting malignancy in 'cold' thyroid nodules. Eur J Endocrinol 1998; 138: 41-46.
14. Kim E.K., Park C.S., Chung W. Y., Oh K.K., Kim D.I., Lee J.T. et al. New sonographic criteria for recommending fine-needle aspiraltion biopsy of non-palpable solid nodules of the thyroid. AJR 2002; 178:687-691.