ORIGINAL RESEARCH PAPER

Volume-7 | Issue-5 | May-2018 | PRINT ISSN No 2277 - 8179

INTERNATIONAL JOURNAL OF SCIENTIFIC RESEARCH

# ULTRASOUND EVALUATION OF ACUTE ABDOMEN WITH CT CORRELATION

Radiodiagnosis

**Dr. Pruthvi M** Assistant Professor Department of Radiodiagnosis Alluri Sitarama Raju Academy of Medical Sciences Eluru-534004 West Godavari district, Andhra Pradesh, India

**Dr. Srinivasa Reddy. M*** Assistant Professor Department of Radiodiagnosis Alluri Sitarama Raju Academy of Medical Sciences Eluru-534004 West Godavari district, Andhra Pradesh, India
*Corresponding Author

## ABSTRACT

'Acute abdomen' defines a clinical syndrome characterized by sudden onset of severe abdominal pain demanding immediate observation and emergency medical or surgical treatment.

**OBJECTIVES:**

1. To evaluate role of ultrasonography and CT in evaluation of acute abdomen.
2. To evaluate the sensitivity of USG and CT in diagnosing acute abdomen and which is more sensitive.
3. To determine various conditions which can present as acute abdomen.

**MATERIALS AND METHODS:** A prospective study of ultrasonography evaluation of acute abdomen with CT correlation was done by taking a sample size of minimum 100 patients referred from emergency department, out-patient and in-patients who were clinically diagnosed as a case of acute abdomen. ethical committee approval with informed patient consent was obtained prior to data collection.

**CONCLUSION:** CT has become the most important noninvasive imaging tool to diagnose acute abdomen as it has the potential to positively affect the outcome, morbidity and mortality in patients with acute abdomen. Sensitivity as well as specificity of CT in this study is 100% each.

## KEYWORDS

CT- Computed Tomography, USG- Ultrasonography.

## INTRODUCTION:

The term 'acute abdomen' defines a clinical syndrome characterized by sudden onset of severe abdominal pain demanding immediate observation and emergency medical or surgical treatment.

A rapid and accurate diagnosis in the patients of acute abdomen is a must if the morbidity and mortality associated with this condition is to be significantly reduced.Acute abdomen can be due to acute appendicitis, pancreatitis, cholecystitis, pyelonephritis, renal colic, bowel obstruction, bowel perforation intra-abdominal abscesses and abdominal trauma.

Clinical diagnosis is many times difficult in the patients of acute abdomen primarily due to overlap of signs and symptoms, also laboratory and other conventional radiological studies are many times nonspecific. Today, ultrasonography (USG) of abdomen is one of the commonly asked investigations by the surgeon in case of acute abdomen. Advantage of USG over other radiological investigation is that it is easily available, cost effective, portable, no known side effects, non invasive and requires minimal patient preparation. One of the major limitations of ultrasound is the frequently occurring adynamic ileus in patients with an acute abdominal condition. This renders large areas of the abdomen inaccessible for ultrasound evaluation, since gas transmits sound waves poorly. Another significant limiting factor for ultrasound is that it is a totally operator oriented modality.

Development of computed tomography has made a big impact on the diagnosis and management of patients of acute abdomen. Because computed tomography, especially spiral CT is a very rapid and also a non-invasive modality that provides, detailed and cross sectional views of all types of tissues, it is becoming the preferred modality for the diagnosis of various conditions that can give rise to acute abdomen. CT examination can quickly identify the source of abdominal pain and can reduce the risk of further complications.

Spiral CT techniques have made scanning much faster, reducing respiratory and other movement artifacts as well as reducing the time these acutely ill patients need to be in the scanner. CT images are not degraded by abdominal fat as compared to radiography and ultrasound. It can cover a wide range of abnormalities involving solid organs, gastrointestinal tract, mesentery, omentum, peritoneum and retroperitoneal organs. More ever thinner slices enable much better reconstruction in sagittal and coronal planes, as well as 3D reconstructions, which may be useful in vascular emergencies.

Spiral CT is now considered as the most reliable and accurate modality of diagnosis in patients of acute abdomen.

## MATERIALS & METHODS

A prospective study of ultrasonography evaluation of acute abdomen with CT correlation was done by taking a sample size of minimum 100 patients. The results were tabulated.

**Place of study:** Department of Radiodiagnosis and imaging at Alluri Sitaramaraju Academy of Medical Sciences, Eluru, after taking prior clearance from ethical committee.

**Equipment:**

Duration of study: The period of study was carried out from November 2016 to February 2018.

**SELECTIONCRITERIA:**

**Inclusion criteria:**

- Both traumatic and non traumatic cases
- patients presenting with acute abdominal pain

- **Exclusion criteria:**
- Patients on whom ultrasound cannot be performed due to improper stance /positioning.
- Unco-operative patients, Unwilling patients, Patients not ready to give consent.
- Very serious cases requiring immediate surgical intervention
- Dead on arrival

## RESULTS:

**AgeDistribution:** The most common age group affected was 31 to 40 yrs of age(22%).

**Sex Distribution:** Of 100 patients 73 (70%) were males and 27 (27%) were females.

**Distribution of pathologies according to system/organ:** The system most commonly involved was GIT (38.0% patients).

**TABLE 1: Distribution of Pathologies according to system/organ**

| System involved | Frequency | Percent |
|---|---|---|
| GI | 38 | 38.00% |
| GUT | 8 | 8.00% |
| Hepatobiliary | 21 | 21.00% |
| Pancreas | 11 | 11.00% |
| Spleen | 2 | 2.00% |

| | | |
|---|---|---|
| Polytrauma | 9 | 9.00% |
| Others | 4 | 4.00% |
| Normal | 7 | 7.00% |
| Total | 100 | 100.00% |

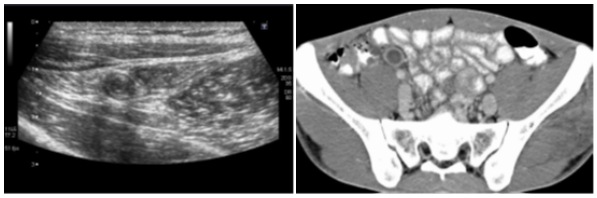

**Figure 1 :** Acute appendicitis- USG showing dilated appendix with thickened wall. Contrast enhanced CT shows dilated appendix (arrow) with thickened enhancing wall.

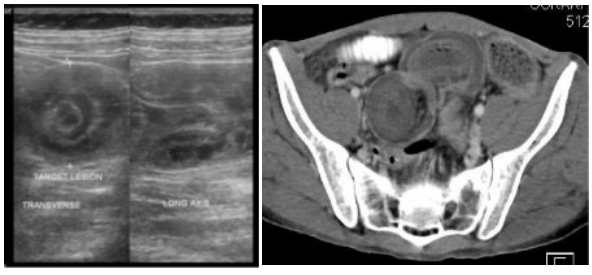


**Figure 2:** Intussusception: USG showing target sign ( bowel within bowel appearance). Contrast enhanced CT shows "bowel-within-bowel" appearance in ileo-ileal intussusception- Sausage sign in longitudinal axis & target sign in transverse axis.

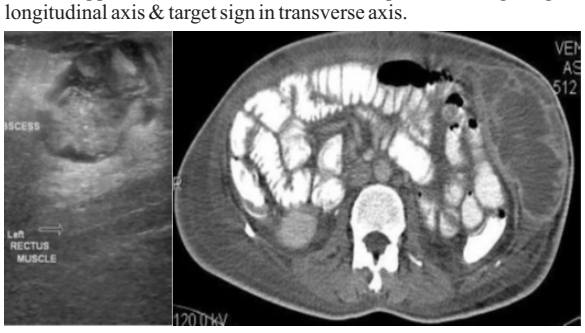


**Figure3 :** USG showing anterior abdominal wall abscess. Parietal wall abscess- contrast enhanced CT shows a multiloculated peripherally enhancing hypodense collection in parietal wall in left lumbar region.

## DISCUSSION:

The 'acute abdomen' is a clinical condition which demands urgent diagnosis so as to enable the physician to make early and correct decision regarding patient's management. This often poses a diagnostic challenge to the physician because the differential diagnosis of acute abdomen includes a wide spectrum of disorders; also physical examination, clinical presentation and laboratory examination are many times nonspecific and non-diagnostic. Almost all patients are exposed to USG prior to CT. although USG cannot make exact diagnoses in all cases, its findings are contributory to final diagnoses in many conditions like perforation, intestinal obstruction, appendicitis etc.. Although sonography has gained a wide acceptance in evaluating acute abdomen, it has got its own limitations like inadequate study because of bowel gases and obesity.

Over the years CT has evolved as the prime imaging technique in evaluating the patients presenting with acute abdominal pain. CT has got high sensitivity in diagnosing most of the conditions causing acute abdomen like acute appendicitis, pancreatitis, cholecystitis, pyelonephritis, renal colic, bowel obstruction, bowel perforation intra-abdominal abscesses and abdominal trauma. The most important aspect of CT is that it cannot only detect the cause but can also serve as a roadmap for planning surgical or nonsurgical management of the patient. Early detection of conditions like bowel obstruction, bowel perforation, ischemic bowel disease, acute appendicitis and cholecystitis by CT can lead to more timely surgical intervention, whereas in conditions like acute pancreatitis, pyelonephritis, intra-abdominal abscesses, appendicular mass or abscess the accurate diagnosis of the problem by CT will often lead to nonsurgical management, or image guided percutaneous therapy.

**Chakraborty S.** (2003) discussed the impact of development of spiral computed tomography on the management of acute abdomen and concluded that spiral CT techniques have made scanning much faster, reducing respiratory and other movement artifacts as well as reducing the time these acutely ill patients need to be in the scanner. Also thinner slices enable much better reconstruction in sagittal and coronal planes, as well as 3D reconstructions, which may be useful in vascular emergencies. Spiral CT is now the most reliable and accurate method of diagnosis in many of these patients. (8)

In a study done by **HS Fung, S Lau** Et al, the utility and accuracy of ultrasonography in evaluation of acute appendicitis was determined. In this retrospective study, 242 of 286 patients undergoing ultrasonography of the appendix from 1 June2006 to 31 December 2006 were included. The ultrasonography report, pathology report, and clinical notes were reviewed. The overall rate of visualization of the appendix was 41.7%. Fifty-six patients (23%) had a positive diagnosis of acute appendicitis by ultrasonography, 45 (19%) had a negative diagnosis, and 141 (58%) had an inconclusive diagnosis; 17 patients (7%) had an alternative diagnosis suggested by ultrasonography. Twentynine patients (12%) underwent computed tomography on the basis of the ultrasonography report, 6 of whom had a positive diagnosis for acute appendicitis, 5 had a negative diagnosis, and 18 had an alternative diagnosis suggested by computed tomography. The sensitivity, specificity, positive predictive value, and negative predictive value of ultrasonography for acute appendicitis were 75.9%, 89.7%, 73.2%, and 91.0%, respectively, after adjusted calculation for the group with an inconclusive ultrasonography diagnosis.(9)

**Mackersie Andrew B.** et al. (2005) conducted prospective study on 91patients with acute non-traumatic abdominal pain to evaluate and compare the diagnostic accuracy of unenhanced helical computed tomography. The sensitivity, specificity and accuracy of CT in the diagnosis of acute abdomen in this study were 96%, 95.1% and 95.6% respectively. He concluded that unenhanced helical CT is an accurate technique to evaluate patients with acute non-traumatic abdominal pain and should be considered alternative to radiography as the initial imaging modality.(11)

In this study total 100 patients who presented with acute abdomen were subjected to ultrasound of abdomen and pelvis prior to CT scan. CT scan was done in all these patients as per requisition by referring clinician using both oral and I.V contrast. Out of these ultrasound was able to make the diagnosis in 45 cases. Ultrasound of abdomen- pelvis was normal in 8 cases. In 34 cases ultrasound findings were found to be contributory to final diagnosis and in 13 cases USG findings were either inconclusive or non diagnostic.

The most common system involved in this study was GIT (38%) and the most common single organ involved was pancreas. Incidence of acute abdomen was more in males. 73 out of 100 patients (73%) were males However only 27% females were affected. The most common age group affected was between 31 to 40 years with 22 patients (22%) belonging to this group.

## CONCLUSION:

CT has become the most important noninvasive imaging tool to diagnose acute abdomen as it has the potential to positively affect the outcome, morbidity and mortality in patients with acute abdomen. Sensitivity as well as specificity of CT in this study is 100% each.

## REFERENCES

1. Gore Richard M, Miller Frank H, Pereles F. Scott, Yaghma Vahid et.al ,Helical CT in the evaluation of the acute abdomen. American Journal of Roentgenology, 2000; Vol 174: 901-913
2. Saleh M. Al-Salamah, Shaukat M. Mirza, Sheikh N. Ahmad, Kamran Khalid, Role of ultrasonography, computed tomography and diagnostic peritoneal lavage in abdominal blunt trauma. Saudi Med J 2002; Vol. 23 (11): 1350-1351
3. Taourel P, Baron MP, Pradel J, Fabre JM, et.al. Acute abdomen of unknown origin: impact of CT on diagnosis and management. Gastrointestinal Radiology. 1992; 17(4):287-291
4. Can AKTAŞ,1 Esin YENCİLEK,2 Didem AY,1 Baki EKÇİ,3 Sezgin SARIKAYA, et .al Comparison of Computerized Spiral Tomography with Ultrasonography for detection of ureteral calculi- Turk J Emerg Med 2010;10(1):12-14
5. H. Prasad, G. Rodrigues, R. Shenoy: Role Of Ultrasonography In Non Traumatic Acute Abdomen. The Internet Journal of Radiology.2006 Volume 5 Number 2. DOI: 10.5580/676.
6. Siewert B, Raptopoulos V, Mueller MF, Rosen MP et.al. Impact of CT on diagnosis and management of acute abdomen in patients initially treated without surgery. American Journal of Roentgenology, 1997; Vol 168, 173-178.
7. Urban Bruce A and Fishman Elliot K. Tailored helical CT evaluation of acute abdomen. Radiographics. 2000; 20:725-749.

8. Chakraborty S. The role of spiral Computed Tomography(CT) in diagnosis of acute abdomen. Journal of Surgery (Oxford), Vol 20, Issue10, Pages 1-2.
9. HS Fung, S Lau, JCW Siu, CM Chan, et.al, Audit of ultrasonography for diagnosis of acute appendicitis. Department of radiology and imaging, Hong Kong, J HK col radiology 2008;11:108-111.
10. Jang TB 1,2 Schindler D, Kaji AH, bedside ultrasonography for the detection of small bowel obstruction, Emerg Med J 2011;28:676e678. doi:10.1136/ emj.2010.095729.
11. MacKersie AB, Lane MJ, Gerhardt RT, Claypool HA, et al. Non-traumatic acute abdominal pain: Unenhanced helical CT compared with three-view acute abdominal series Radiology2005; 237:114–122.
12. Khalid M, Redhu N, Nazir B, et al, Diagnostic value of ultrasonography in evaluation and management of acute abdominal conditions in the paediatric age group. Afr J Paediatr Surg. 2012 Sep-Dec;9(3):198-201