VOLUME-6 | ISSUE-4 | APRIL - 2017 • ISSN No 2277 - 8179 | IF : 4.176 | IC Value : 78.46

Original Research Paper

Dental Science

KEYWORDS:

UNITY BEATS DIVERSITY-AN INTERDISCIPLINARY APPROACH

Dr. Manish Goyal	Professor,Department of Orthodontics and Dentofacial Orthopedics, Kothiwal Dental College and research centre, Moradabad, UP-244001
Dr. Richashree	Post graduate student, Department of Orthodontics and Dentofacial Orthopedics, Kothiwal Dental College and research centre, Moradabad, UP-244001
Dr. Sonam Rastogi	Post graduate student, Department of Orthodontics and Dentofacial Orthopedics, Kothiwal Dental College and research centre, Moradabad, UP-244001
Dr. Swati Gupta	Post graduate student, Department of Orthodontics and Dentofacial Orthopedics, Kothiwal Dental College and research centre, Moradabad, UP-244001
Dr. Kanishk Mudgil	Post graduate student, Department of Orthodontics and Dentofacial Orthopedics, Kothiwal Dental College and research centre, Moradabad, UP-244001
Dr. Soumitra Agarwal	Post graduate student, Department of Orthodontics and Dentofacial Orthopedics, Kothiwal Dental College and research centre, Moradabad, UP-244001

ABSTRACT

The role of orthodontist in an interdisciplinary treatment approach can be primary or secondary. Primary as in a case wherein an orthodontic patient requires adjunctive other specialties treatment. Secondary as in cases where the orthodontic treatment rendered is an adjunct to other treatment planned.

A male patient of age 13years reported to the department of prosthodontics with the chief complaint of missing teeth in relation to 11, 12, 13,22,21,31 and 41.

Patient was referred from the prosthodontic for the intrusion of 35 for the placement of 24. Patient had facial symmetry with competent lips and straight profile. Treatment was started through burstone cantilever. 19 gauge wire was bonded in relation to 33, 34 and 35. Banding was done in relation to 36 and buccal tube was welded. Burstone cantilever was fabricated with 17x25 inch titanium molybdenum alloy wire. Treatment duration was 6 months..

Introduction

In today's life style patients are more concerned about their esthetics and also desire functionally stable occlusion. So, this is leading to the new era in the dentistry. This enables the best utilization of the skills of expertise of the clinicians of different specialties for the best possible treatment outcome of the patients[1]. Such joint care of a patient's dental needs is defined as interdisciplinary treatment[2].

Indication for interdisciplinary treatment

1. Periodontally compromised dentition
2. Missing teeth
3. Space management
4. Trauma from occlusion
5. Fractured tooth
6. Post and core

The role of orthodontist in such an interdisciplinary treatment approach can be primary or secondary. Primary as in a case wherein an orthodontic patient requires adjunctive other specialties treatment as prosthetic replacement of missing teeth, tooth build-up to match a Bolton discrepancy, periodontal rehabilitation, surgical exposure of an impacted tooth, etc. Secondary as in cases where the orthodontic treatment rendered is an adjunct to other treatment planned. Like in the present case report of space creation was required to facilitate prosthetic replacement of a missing tooth.

Case report

A male patient of age 13years reported to the department of prosthodontics with the chief complaint of missing teeth in relation to 11, 12, 13,22,21,31 and 41(fig 1). Patient had a history of bike accident. Patient was referred from the prosthodontic for the intrusion of 35 for the placement of 24. Patient had facial symmetry with competent lips and straight profile (fig 2).

Treatment progress

Treatment was started through burstone cantilever[3]. 19 gauge wire was bonded in relation to 33, 34 and 35. Banding was done in relation to 36 and buccal tube was welded. Burstone cantilever was fabricated with 17x25 inch titanium molybdenum alloy wire(fig 3). Treatment duration was 6 months(fig 4). In the meantime patient was instructed to maintain oral hygiene.



Fig 1- Intra- oral



Fig 2- Extra- Oral



VOLUME-6 | ISSUE-4 | APRIL - 2017 • ISSN No 2277 - 8179 | IF : 4.176 | IC Value : 78.46

Fig 3- Burstone cantilever

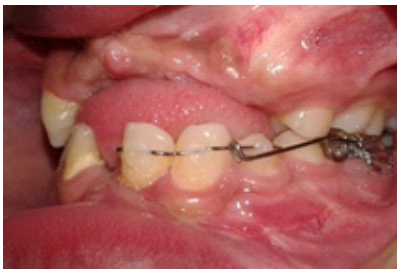

Fig 4- After 6 months intrusion of 7mm



Fig 5- With removal partial denture

Discussion

A cantilever is, in principle, any piece of wire, whose end is inserted, on one side, into a bracket or a tube, or included in the acrylic of a removable appliance, while the other one is tied to another unit, with only a one-point contact. When using the cantilever, the orthodontist can easily estimate the force system on both units, just measuring the length of the appliance and its force by means of a dynamometer -in the direction of its activation- and thereby predict the clinical result. Considering the biomechanical force system generated by a cantilever, it is important to remember that a combination of a moment and a force is produced at the unit into which the cantilever is inserted, whereas only a single force is developed with respect to the point of force application of the other end. The magnitude of the two forces is equal and opposite, according to the third law of Newton, and the activation can be measured by a dynamometer.

$M = F \times d$

An important characteristic of the force systems generated by the cantilever, is their high degree of constancy over time and deactivation. In other words, the forces at its two ends, maintain their direction and decrease in a linear manner, proportionally to the cantilever deactivation. In addition, there is also a high degree of constancy of the MOMENT/FORCE ratio (with respect to the bracket). This means also a homogeneous dental movement. The force system being always directed towards the treatment goal, this is rapidly achievable, with a minimum iatrogenic response.

Conclusion

Frequently in our practice, a patient's care involves a multidisciplinary treatment approach. Examination of the patient's chief complaint and treatment demands should be evaluated thoroughly. It is salient factor that the orthodontist together with the other specialists scaffold a treatment objectives which meet the necessity of the patient's demand. Persistent co-operation and conversation among the team members and the patient at all level of treatment are the keys to the triumph of the interdisciplinary treatment.

References

1. Khumanthem Savana, Akram Ansari, Rani Hamsa PR, Mukesh Kumar, Abhay Jain, Ankit Singh. Interdisciplinary Therapy in Orthodontics: An Overview. International Journal of Advanced Health Sciences September 2014; 1(5): 23-31.
2. Kharbanda O.P. Orthodontics: Diagnosis and Management of Malocclusion and Dentofacial Deformities 2nd ed, Elsevier; 2013.
3. Burstone CJ. The mechanics of the segmented arch techniques. Angle Orthod. 1966;36:99–120.
4. Proffit WR, Fields HW. Contemporary Orthodontics. 3rd ed. St Louis, Mo: Mosby; 20007