Research Paper

Volume : 5 | Issue : 6 | June 2016 • ISSN No 2277 - 8179 | IF : 3.508 | IC Value : 69.48

Unusual Cases of Epidermoid Cyst : Case Series

Medical Science

KEYWORDS : Epidermoid cyst, breast epidermoid cyst, tonsillar epidermoid cyst

Dr. Rajul Desai	Consultant Pathologist, GRMI, Rajasthan Hospital.
Dr. I. M. Desai	HOD & Consultant Pathologist, GRMI, Rajasthan Hospital.
Ms. Kunjlata Rajput	Quality Manager, GRMI, Rajasthan Hospital.

ABSTRACT

Epidermoid cyst is an common benign condition. We report two cases of enlarging epidermoid cyst in uncommon areas like tonsil and breast. The diagnosis of this condition is usually not straightforward with imaging alone. Diagnosis can be made on histopathological examination or cytological examination (FNA). Excision is usually recommended for definite histopathological diagnosis and potential risk of malignant transformation. The incidence of epidermoid cyst arising in the tonsil is very rare and usually an incidental findings

INTRODUCTION

Epidermoid cysts are non odontogenic inclusion cyst lined by ectoderm [1]. These are rare lesions derived from germinal epithelium and are encountered throughtout the body in areas where embryonic elements fuse together [2,3,4,5]. Most cases have been reported in ovaries and the testicles, with 7% occurring in the oro facial area and 1.6% in the oral cavity, representing 0.01% of all oral cavity cysts. [4,5]. Here we are presenting two cases of Epidermoid cyst, 1) a case of epidermoid cyst in 37 year male patient arising in the tonsil which was encountered as an incidental finding in the patient with the diagnosis of chronic tonsillitis. 2) a case of epidermoid cyst arising in the breast in the 48 year female patient.

CASE REPORTS

CASE REPORT 1

A 37 year male patient presented with complaining of chronic tonsillitis since 4 months. The patient was asymptomatic before that and the swelling gradually increased in size. On oral examination both tonsils were enlarged circumscribed swelling was seen with yellowish cyst & left tonsil was larger than right. Regional lymph nodes were not palpable. Blood and urine examination were normal. Tonsillectomy was performed as asymmetrical adult tonsils with normal mucosa in absence of cervical adenopathy is associated with 7% risk of malignancy.[6] Histopathology showed tonsils with cyst lined by stratified squamous epithelium filled with cholesterol cleft, keratin flakes, foamy macrophages and lymphocytes, multiple calcified foci were seen and diagnosis of Chronic tonsillitis with calcified epidermoid cyst was made. Post operative period was uneventful and patient was discharged subsequently and followup was uneventful.

CASE REPORT 2

A 48 year female patient present with complaint of painful breast lump for about 3 years and associated with low grade fever and the swelling gradually increased in size over period of 3 years. Regional lymphnodes were non palpable, blood and urine examinations were normal. On examination a round firm lesion adherent to the overlying skin in the lower outer quadrant of the right breast was present. Mamography reveled a smoothly outline dense oval mass with a surrounding lucent halo suggestive of benign breast lesion. Based on the clinical and imaging finding differential such as fibroadenoma, sebaceous cyst and epidermal cyst were suspetecd and fine needle aspiration of the lesion was performed and whitish viscid material was aspirated, confirming the cystic nature of the lesion. Cytological examination revealed numerous clumps of mature squamous epithelial cells with small amounts of anucleated keratin. There were no other cells elements presents. The findings were consistent with a beningn epidermoid cyst.

DISCUSSION

Epidermoid cysts are benign lesions that are histologically characterized by cystic spaces lined by squamous epithelium. They generally appear in areas where embryogenic element fuse. They can be classified as being either congenital or acquired based on its origin.

Histologically there are three types of dermoid cysts– epidermoid cyst, true dermoid cyst and teratoid. Epidermoid is a type of dermoid cyst, lined by squamous epithelium, contains keratin and has no adnexal structures. True dermoid cyst contains appendages such as hair follicle, sweat glands, sebacious gland etc. Teratoid cyst contains elements from all germ layers- skin, nail, teeth, nervous tissue, gland etc. The most prevalent theory was proposed by Remark and Bucy in 1854, which suggests the inclusion of ectodermal tissues during embryogenesis.[7] The theory of metaplasia, proposed by Wendt in 1873, states that the non-keratinizing squamous epithelium lining the cavity undergoes metaplastic changes in response to prolonged irritation due to chronic infection[7]. In 1928 Ewing proposed the Implantation theory, which states that these cysts are a result of direct entry of epithelium into a site during trauma [8]

Tonsillar retention cyst is most common cyst seen in tonsil. Dermoid cyst in tonsils is very rare. Other rare causes of tonsillar cyst include lymphoepithelial cyst, hydatid cyst etc. Tonsillar cyst is asymptomatic in many patients. Presence of swelling in the throat may cause difficulty in swallowing. Our patient had recurrent episodes of sore throat probably due to cyst infection. Head and neck constitutes approximately 7% of all cases of epidermoid and dermoid cyst. [9] Surgical excision is the treatment of choice. If the cyst can be excised completely, there is no chance of recurrence. Histopathology will confirm the benign nature of the cyst. Hence the incidence of epidermoid cysts is very rare-within the tonsil. They appear as painless, asymptomatic mass, slowly increasing in size [10]

Based on the English language literature reviews, fewer than 40 cases of EIC that develop in the breast have been reported. [11] Epidermoid cysts typically appears well-circumscribed with homogeneous increased density on mammography.[11] Diagnosis is straightforward when EIC occurs

as a small nodule in the subcutaneous tissue of the breast. [12] However, EIC occurring in the breast parenchyma can occasionally be misdiagnosed based on imaging alone, especially if they present as breast lumps with mammographic and sonographic appearances mimicking fibroadenomas or phyllodes tumours, or even malignant breast lesions with benign features such as mucinous carcinomas In view of its uncommon occurrence and in the hands of less experienced clinicians and radiologists, a palpable breast lump with mammographic and sonographic appearance of a well-circumscribed solid hypoechoic mass is more likely to be thought of as a fibroadenoma. In addition in view of the increasing size of the lesion, tissue diagnosis was carried out to exclude carcinoma with well defined border. Although epidermal inclusion cysts are known to be benign, they may rarely have malignant potential with transformation into squamous cell carcinoma. Menville et al found that 19% of the patients with EIC in his case series showed malignant squamous cell lining on histopathological examination.[12]

Case Photos

1. (Case 1)

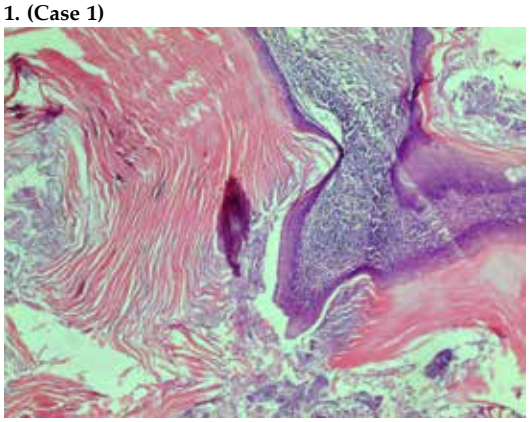

2. (Case 2)

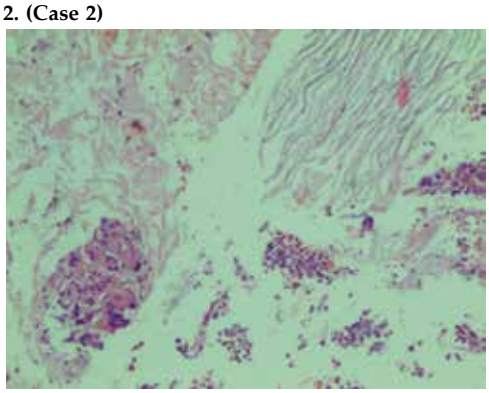

3. (Case 2)

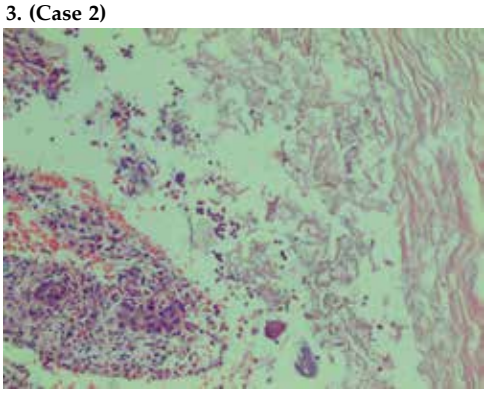

Reference

1. Pancholi A, Raniga S, Vohra PA, Vaidya V. Midline submental epidermoid cyst: A rare case. Internet J Otolaryngol 2006; 4 (2).
2. Brown CA, Barker RD. Dermoid cyst: Report of a case. J Oral Surg 1972; 30: 55.
3. Rajayogeswaran V, Everson JW. Epidermoid cyst of buccal mucosa. Oral Surg Oral Med Oral Pathol 1989;67: 181.
4. Koca H, Seckin T, Sipahi A, Kaznac A. Epidermoid cyst in the floor of the mouth: report of a case. Quintessence Int 2007; 38: 473-7.
5. Ozan F, Polat HB, Ay S, Goze F. Epidermoid cyst of the buccal mucosa: A case report. J Contemp, Dent Pract 2007;8(3):1-6.
6. Macnamara M. Acute and chronic pharyngeal infections. In Gleeson M (ed). Scott-Brown's Otorhinolaryngology, vol 2, 7th ed. Hodder Arnold;2008. pp 1981-2025.
7. Rozario Joyce Pascal; Appaji Mohan; Abhilash A.M. (2013). Epidermoid Cyst of Maxilla- Rare and interesting Case Report. *Otolaryngology online journal*, *UIS*, 3(4), 163 – 170.
8. Viswanatha B, Nayak LK, Karthik S. (2007). Cholesteatoma of the maxillary sinus. *Ear Nose Throat J*, 86(6), 351–353.
9. Dutta M, Saha J, Biswas G, Chattopadhyay S, Sen I, Sinha R. Epidermoid cysts in head and neck: Our Experience, with Review of Literature. Indian J Otolaryngol Head Neck Surg. 2013;65(1):S14-S21.
10. Paraskevi Tsirevelou, Mattheos Papamanthos, Paschalis Chlopsidis, Ifigenia Zourou, Charalampos Skoulakis. (2009). Epidermoid cyst of the floor of the mouth: two case reports. *Cases Journal*, 2, 9360. (doi:10.1186/1757-1626-2-9360.
11. Taira N, Aoji K, Ohsumi S, et al. Epidermal Inclusion Cyst of the Breast. Breast Cancer 2007; 14:434-7
12. Menville JG. Simple dermoid cyst of the breast. Ann Surg 1936; 103:49-56.