ORIGINAL RESEARCH PAPER

Volume-8 | Issue-7 | July - 2019 | PRINT ISSN No. 2277 - 8179

INTERNATIONAL JOURNAL OF SCIENTIFIC RESEARCH

UNUSUAL FORMATION OF MEDIAN NERVE AND OCCURRENCE OF MUSCULO-APONEUROTIC BAND IN THE COURSE OF MEDIAN NERVE IN ARM: A CLINICO-ANATOMICAL STUDY

Anatomy

Deepika Poonia MBBS, MD-Senior Resident, Department of Anatomy, Maulana Azad Medical College, New Delhi, India

Anita Mahajan* MBBS, MD-Professor, Department of Anatomy, Maulana Azad Medical College, New Delhi, India *Corresponding Author

Sabah Yaseen Shah MBBS, MD-Senior Resident, Department of Anatomy, Maulana Azad Medical College, New Delhi, India

Sabita Mishra MBBS, DNB, PhD-Director, Professor and Head of Department, Department of Anatomy, Maulana Azad Medical College, New Delhi, India

ABSTRACT

Median nerve is one of the commonly involved nerves in peripheral neuropathy of the upper limb. Peripheral neuropathies may occur due to various intrinsic (medical conditions like diabetes mellitus & Guillian Barre syndrome) and extrinsic (nerve entrapment) causes. This study reports an unusual course of median nerve which can be considered as cause of such entrapment neuropathy. During routine MBBS dissection on a 76 years old male cadaver unusual formation and variant course of median nerve was noted.

In present study unusual relation of the medial root of median nerve with axillary artery was found at the origin and secondly the nerve was found coursing under the musculo-aponeurotic band located on the antero-medial side of lower one-third of the right arm. These observations are important as the aponeurotic band may compress the median nerve and may results in entrapment neuropathy. The comprehensive knowledge of possible variant anatomical relations of median nerve are of great importance to understand the cause of symptoms and to facilitate early diagnosis and prompt management of patient presenting with median nerve compression.

KEYWORDS

Compression; entrapment; fascia; neuropathy.

INTRODUCTION

An entrapment neuropathy may results when the nerve traverses a fibro-osseous canal and is fixed relatively. The most common site of median nerve [MN] entrapment is below flexor retinaculum in the carpal tunnel (Andreisek G, 2006). Other sites of compression due to variant anatomical structures have been described in the forearm and lower part of the arm (Caetano EB, 2015; Dellon AL and Mackinnon SE, 1987; Spinner M, 1970; Tubbs RS, 2011; Caetano EB, 2017; Jelly L and Georgiev G, 2009).

Mechanical irritation of the nerve due to any rare variant anatomical structure must be considered in cases with unexplained peripheral neurological symptoms. Thus variations must be reported to assist surgeons in better understanding and management planning to alleviate neurological symptoms (Bilecenoglu B, Aysun Uz and Nazim Karalezli, 2005).

Median Nerve is formed by the union of two roots- medial [C8, T1] and lateral [C5, 6, 7] anterior or lateral to the third part of axillary artery where medial root of MN crosses axillary artery anteriorly. MN then descends in the arm lateral to brachial artery; in the middle of the arm MN crosses the brachial artery, anterior to it, from lateral to medial. Further it descends medial to brachial artery in the groove between brachialis and biceps brachii before it enters the cubital fossa lying deep to bicipital aponeurosis and superficial to brachialis muscle (Williams PL, 2000).

This paper highlights the presence of a rare musculo-aponeurotic band formation in the lower one-third part of the arm. MN coursed deep to the band, in contrast brachial artery passed superficial to the band. This variant aponeurotic band in the arm may predispose MN to compression neuropathy.

CASE REPORT

During routine dissection for MBBS students, in the right arm of a 76 years old male cadaver, variant formation and course of MN was noted. In the right arm number of variations was observed. Firstly the medial root [MR] of median nerve crossed the axillary artery posteriorly, to unite with the lateral root [LR] of median nerve to form median nerve [Figure 1(a), (b)].

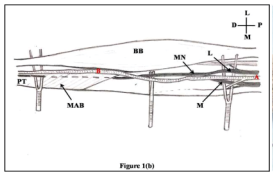

Figure 1(b)

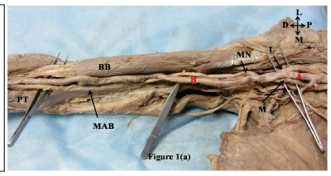

Figure 1(a)

Caption and Legends

Figure 1(a), (b) show unusual formation and course of median nerve and axillary artery.

M: Medial root of median nerve, L: Lateral root of median nerve, P: Proximal, D: Distal, MN: Median Nerve, A: Axillary artery, B: Brachial artery, BB: Biceps Brachii, MAB: Musculoaponeurotic band, PT: Pronator Teres.

Secondly, MN which was formed lateral to third part of axillary artery descended lateral to the brachial artery in the upper half of the arm. In middle of the arm, MN crossed behind the brachial artery, descended medial to it in the musculoaponeurotic tunnel. MN coursed through this musculoaponeurotic tunnel in the lower one-third of the medial side of the arm, for a distance of about 7 centimetres. The roof of tunnel was formed by the variant oblique musculo-aponeurotic band, whereas the floor was formed by brachialis muscle. Brachial artery located lateral to the MN, passed superficial to the musculo-aponeurotic band. On being traced, the variant band became thin and continued with the deep fascia covering brachialis supero-laterally and with the fascia covering humeral head of pronator teres infero-medially [Figure 1(a), (b)]. Upper and lower edges merged with the neighbouring connective tissue. The nerve was traced distally to check other possible sites of entrapment. We did not find any other MN entrapment site.

Histological examination revealed presence of few skeleton muscle fibers within the aponeurotic band (Figure 2).

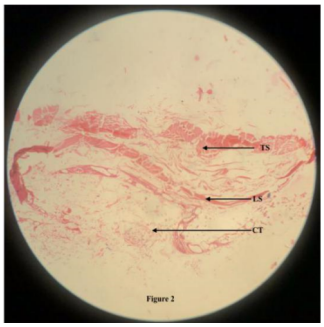

Figure 2 shows transverse and longitudinal sections of skeleton muscle fibers in the aponeurosis.

TS: Transverse section, LS: Longitudinal section, CT: Connective tissue fibers.

DISCUSSION

Peripheral neuropathies may be due to intrinsic causes such as in diabetes mellitus, poly-arteritis nodosa, Sjogren's disease, Guillain-Barre syndrome and Berger's disease or extrinsic causes like nerve compression i.e. entrapment neuropathy. Among the three major peripheral nerves in forearm, prevalence of neuropathy is highest in ulnar nerve (67.3%) followed by median nerve (51.9%) and lowest in radial nerve (4.8%) (Lukas R et al, 2015).

Neuropathy due to MN compression is a common cause of peripheral nerve entrapment neuropathy. The causes of MN entrapment in forearm have been extensively studied. According to various studies, MN is prone to get entrapped due to anatomic impingement below flexor retinaculum, Gantzer muscle, variant origin of pronator teres and flexor digitorum superficialis, brachialis muscle and lacertus fibrosus (Caetano EB 2015; Dellon AL and Mackinnon SE 1987; Spinner M, 1970; Bilecenoglu B, Aysun Uz and Nazim Karalezli, 2005).

Entrapment of MN in arm is less common compared to forearm. Studies have shown the existence of various anatomical structures in the arm which predispose MN to compression. The commonly described structures which are prone to compress MN in arm, are ligament of Struther's (Tubbs RS, 2011; Caetano EB, 2017; Jelly L and Georgiev G, 2009) lacertus fibrosus i.e. bicipital aponeurosis, accessory brachialis muscle (10% cases) (Flory PJ, Berger A, 1985), variant fibers of brachialis merging with the fibers of biceps brachii ending in bicipital aponeurosis. Cadaveric studies have also revealed the MN tunneling within the fibers of brachialis (Wadhwa S, 2004) and 4-headed biceps brachii (Nakatani T, 1998) which may be a cause of MN compression.

We report a rare case highlighting possible sites of MN compression in the arm. Firstly in the axilla, medial root of MN crossed the axillary artery posteriorly followed by the trunk of the MN which crossed the brachial artery posteriorly in the arm before the nerve finally passed deep to a musculo-aponeurotic band. The variant posterior relation of medial root and the trunk of MN with the brachial artery have been rarely reported. The finding of posterior relation of the trunk of MN with the artery was previously reported by Haviarova Z et al (2001) in right upper limb. Later, Mat Taib et al (2016) reported in 13.6% cases on the left side and 4.5% cases on the right upper limb.

Secondly we report a musculo-aponeurotic band in the course of MN nerve endangering it to get compressed in the lower part of the arm. Awareness about the variant aponeurosis bridging MN is essential, for physicians to diagnose the cause of neuropathy as well as for the surgeons during pre-operative planning of surgical release in cases with compressive neuropathy. Knowledge of MN variation is equally important in post-operative cases with persistent symptoms of neuropathy as they reflect existence of nerve compression at multiple sites (Idler RS, 1996).

According to Meyer P et al (2018) aponeurotic bands over-riding a neural tissue may partially interrupt the axoplasmic flow which may results in neuralgia. Furthermore, persistent stretching of MN and mechanical compression may result in neural ischemia and hence increased permeability of micro-vasculature resulting in interstitial edema which further exaggerates nerve fiber compression resembling compartment syndrome.

The cause of the variation may be explained by considering the embryogenesis of arterial system of upper limb. According to Rodriguez-Niedenfuhr et al (1995) formation of arterial system in upper limb commences with the formation of deep axial artery and superficial brachial artery, both connected by multiple anastomotic channels. During development due to hemodynamic predominance, deep axial artery persists whereas superficial brachial artery and anastomotic channels disappear. Abnormal persistence of these arteries, results in variant course and relations of brachial artery. According to Park K.W. (2004) Netrin-1 secreted by limb buds during embryonic life attracts both developing blood vessels and neural tissue. Alteration in Netrin-1 secretion explains the existence of vascular and peripheral nerve variations seen in the present cadaver.

CONCLUSION

Awareness about the variant relations of neurovascular bundles in upper limb may prevent undue trauma during laproscopic approach of shoulder joint (Broadman ND, Cofield RH (1999). This report also emphasizes surgically important relationship between MN and deep fascia in arm. The comprehensive knowledge of probable anatomic structures roofing neural tissue in the limbs can help clinicians to answer the cause of symptoms due to nerve compression which may require surgical release.

Ethical consideration

This cadaveric study was done on a voluntarily donated body, dissected for the teaching of MBBS students and hence no ethical consideration was required.

Conflict of interest

The Authors declare that they have no potential conflict of interest.

REFERENCES

1. Andreisek, G. (2006). Crook DW, Burg D, Marincek B and Weishaupt D. Peripheral neuropathies of the median, radial and ulnar nerves: MR imaging features. Radiographics, 26(5), 1267-87.
2. Bilecenoglu, B., Aysun Uz and Nazim K. (2005). Possible anatomic structures causing entrapment neuropathies of the median nerve: An anatomic study. Acta Orthopaedica Belgica, 71, 169-176.
3. Broadman ND, Cofield RH (1999). Neurologic complications of shoulder surgery. Clinical Orthopaedics and Related Research, 368, 44-53.
4. Caetano, E.B., Neto, J.J.S., Vieira, L.A., Caetano, M.F. and Moraes, D.V. (2015). Gantzer muscle: An anatomical study. Acta Ortopaedica Brasileira, 23(2), 72-75.
5. Caetano, E.B., Neto, J.J.S., Vieira, L.A., Caetano, M.F. (2017). The arcade of Struthers: an anatomical study and clinical implications. Revista Brasileira de Ortho-pedia, 52(3), 331-36.
6. Dellon, A.L. and Mackinnon, S.E. (1987). Musculoaponeurotic variations along the course of median nerve in the proximal forearm. Journal of Hand Surgery, 12(3), 359-63.
7. Flory, P.J. and Berger, A (1985). The accessory brachial tendon- a rare cause of prona-tor teres syndrome. Handchir Mikrochir Plast Chir, 17, 270-72.
8. Haviarova Z et al (2001). Atypical course of the median nerve. Bratislavske lekarske listy, 102(8), 372-373.
9. Idler, R.S.(1996). Persistence of symptoms after surgical release of compressive neu-ropathies and subsequent management. Orthopedic Clinics of North America, 27(2), 409-16.
10. Jelly, L. and Georgiev, G. (2009). Unusual high-origin of the pronator teres muscle from a Struther's ligament coexisting with a variation of the musculocutaneous nerve. Romanian Journal of Morphology and Embryology, 50(3), 497-499.
11. Lukas, R. (2015). The epidemiology of forearm nerve injuries- A retrospective study. Acta Clinica Croatica, 54, 19-24.
12. Mat Taib, C.N., Hassan, S.N.A., Esa, N., Mohd Moklas, M.A., San, A.A. (2016). Anatomical variations of median nerve formation, distribution and possible communication with other nerve in preserved human cadavers. Folia Morphologica, doi: 10.5603/FM.a2016.0045
13. Meyer, P., Lintingre, P.F., Pesquer, L., Poussange, N., Silvestre, A. and Dallaudiere, B. (2018). The median nerve at the carpal tunnel. Journal of Belgian Society of Radi-ology, 102(1), 17, 1-11.
14. Nakatani, T., Tanaka, S. and Mizukami, S. (1998). Bilateral four headed biceps brachii muscles: the median nerve and brachial artery passing through a tunnel formed by a muscle slip from accessory head. Clinical Anatomy, 11, 209-12.
15. Park, K.W., Crouse, D., Lee, M., Karnik S.K., Sorensen, L.K., Murphy, K.J., Kuo, C.J., Li D.Y. (2004). The axonal attractant Netrin-1 is an angiogenic factor. Proc Natl Acad Sci USA, 101, 16210-16215.
16. Rodriguez-Niedenfuhr, M., Burton, G.J., Deu, J., Sanudo, J.R. (2001). Development of the arterial pattern in the upper limb of staged embryos: normal development and anatomic variations. Journal of Anatomy, 199, 407-417.
17. Spinner, M. (1970). The anterior interrosseous-nerve syndrome, with special attention to its variations. American Journal of Bone Joint Surgery, 52(10), 84-94.
18. Tubbs, R..S., Deep, A., Shoja, M.M., Mortazavi, M.M., Loukas, M., Cohen-Godal, A.A. (2011). The arcade of Struthers: An anatomical study with potential neurosurgi-cal significance. Surgical Neurological International, 2, 184. doi:10.4103/2152-7806.91139. Epub 2011 Dec 26.
19. Williams, P.L., Bannister, L.H., Berry, M.M., Collins, P., Dyson, P., Dussek, J.E., Ferguson, M.W.J. (2000). Nervous System. Gray's Anatomy: The Anatomical Basis of Medicine and Surgery. 38th edition. Churchill Livingstone, 1270-71, 844, 857.
20. Wadhwa, S., Mehra, S., Khan, R.Q. and Kapur, V. (2004). Abnormal Musculoaponeurotic Tunnel in the Arm: Possible Entrapment of the Median Nerve and Brachial Artery With High Origin of Nerve to Pronator Teres Within the Tunnel. Clinical Anatomy, 17, 360-63.