ORIGINAL RESEARCH PAPER

Volume-8 | Issue-7 | July - 2019 | PRINT ISSN No. 2277 - 8179

INTERNATIONAL JOURNAL OF SCIENTIFIC RESEARCH

UNWONTED OCULODERMAL SIBLINGS WITH LENTIGO MALIGNA

Ophthalmology

Dr Sharmistha Behera Associate Professor, Department Of Ophthalmology, Vssimsar, Burla

Dr Kshyanaprava Priyadarshini* PG Trainee, Department Of Ophthalmology, Vssimsar, Burla *Corresponding Author

Dr Gopeswari Hota Assistant Professor, Department Of Ophthalmology, Vssimsar, Burla

Dr Jayashree Dora Professor, Department Of Ophthalmology, Vssimsar, Burla

ABSTRACT

Xeroderma pigmentosum is a rare, autosomal recessive disease caused by a defect in nucleotide excision repair pathway.It is a lethal precancerous affliction, primarily of the skin and mucous membranes. Ocular abnormalities have been reported and restricted to tissues exposed to ultraviolet radiation (lid, conjunctiva, and cornea) and included ectropion, corneal opacity leading to blindness, and neoplasms. We report the clinical history and ocular pathology of 2 siblings who had xeroderma pigmentosa. A 21 year old female presented to us with irritation, watering, photophobia, foreign body sensation, pain associated with diminution of vision in both eyes. She presented with ulcerative blepharitis, lower lid ectropion(grade 1), conjunctivalization with anterior symblepharon, interstitial keratitis with both superficial & interstitial vascularization of the cornea in the florid stage with filamentary keratopathy. Similar condition was also found in the sibling. Association of a basal cell carcinoma was present in the right forehead and cheek region. The ophthalmic manifestations of xeroderma pigmentosum are discussed. Mild to extreme sensitivity to ultraviolet radiation resulting in inflammation and neoplasia in sun-exposed areas of the skin, mucous membranes, and ocular surfaces was noted. Structural eyelid abnormalities, tear film abnormalities, ocular surface disease and inflammation, as well as corneal abnormalities was found in both the siblings.

KEYWORDS

INTRODUCTION:

Xeroderma Pigmentosum is also called Atrophoderma Pigmentosa by some or lentigo maligna by others[1]. Xeroderma pigmentosum (XP) was first described by Kaposi in 1870.[1] It is a lethal precancerous affliction, primarily of the skin and mucous membranes. It is a rare, autosomal recessive disease caused by defective DNA repair.

Patient presents with progressive pigmentary abnormalities & an increased incidence in UVR- induced skin & mucous membrane cancers at sun-exposed sites. The most dreaded complication is cutaneous cancers, especially Basal cell carcinoma.

Ocular disease is evident in at least 40% of XP patients and often causes visual impairment [2] Ocular manifestations of XP are primarily those that have been linked to UV exposure of the eyelids, cornea, or lens. Clinically apparent ocular disease includes eyelid atrophy and tumors, corneal sicca and opacification, exposure keratitis, pterygium, and chronic conjunctival injection [3,4]These commonly include photophobia, dry eye,conjunctival injection & inflammation,as well as development of premature pingueculae & pterygium,ectropion, symblepharon, corneal opacities & scarring, ulcerations and epithelioma of lids among many others. XP is divided into 8 complementation groups XP-A to XP-G & XP-V corresponding to the affected DNA repair gene.

CASE REPORT:

A 21 year old female presented with pain, watering & photophobia in both eyes alongwith mucoid discharge in the left eye since 6 months after birth as informed by her mother. She started developing irritation, watering, photophobia, foreign body sensation, pain which was gradual in onset associated with diminution of vision in both eyes. It was associated with intolerance to light. History of rubbing of eyelids was present. Not associated with hearing loss, cognitive deterioration, abnormalities in speech, breakage & thinning or discoloration of hair.
On careful history taking there was a history of similar condition in her sibling (brother) & a death of another sibling due to similar condition with mass all over the body a few months back. No history of consanguinity was revealed. No other family members suffered from similar condition.

General physical examination revealed undernourished body built. Lymph node along the jugular vein was found to be enlarged. Systemic examination revealed no significant abnormality. Dermatological examination showed multiple hypo & hyperpigmented macules were present all over the face & body, multiple hyperpigmented annular to oval plaques of size approximately 2×3 cm present over the face, 2-3 well defined plaques with irregular border & verrucuous surface present over left malar area & right side of nose, areas of hemorrhage with some crusting present all along the body. There were multiple hyperpigmented freckle- like lesions predominantly on sunexposed sites. A mass of size 4×4×5 cm present in the right cheek area over the maxillary region which was soft-cystic in consistency, non-tender, mobile not fixed to the underlying bony surface, with transillumination test negative since last 1 year. She had history of similar mass in the right temporal area which was excised 2 years back (no documentation available) . Multiple hyperpigmented macules and papules of variable size were seen over face, neck, back and bilateral upper and lower limbs. Clinical diagnosis of XP was made.



Figure 1: Multiple Hyperpigmented Annular To Oval Macules & Plaques With A Mass Of Size 4×4×5 Cm In The Right Malar Region



Figure 2: Multiple Hypo & Hyperpigmented Macules & Nodules All Over The Body

- BCVA was OD – 6/18 & OS – CF ½ mtr. Ocular examination revealed madarosis, multiple hyperpigmented lesions along the lid margin with ulcerative blepharitis, lower lid ectropion(grade 1), conjunctivalization with anterior symblepharon, interstitial keratitis with both superficial & interstitial vascularization of the cornea in the florid stage with filamentary keratopathy. On F/L staining superficial punctate erosions in the left eye. Rose Bengal stain revealed filaments. Schirmer test 1 revealed 10mm wetting of the strip (OD) & 9mm wetting of the strip (OS). Punctal stenosis in left eye.

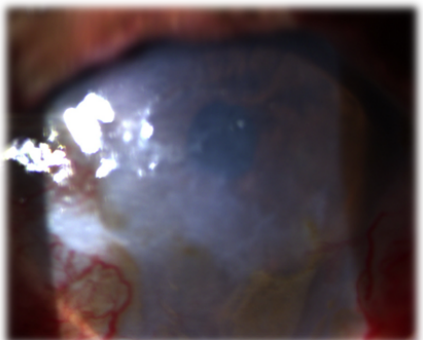

Figure 3 : Le Corneal Edema, Pigmentation & Vascularization

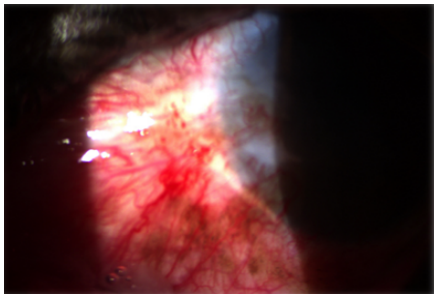

Figure 4 : Le Conjunctivalisation & Pannus

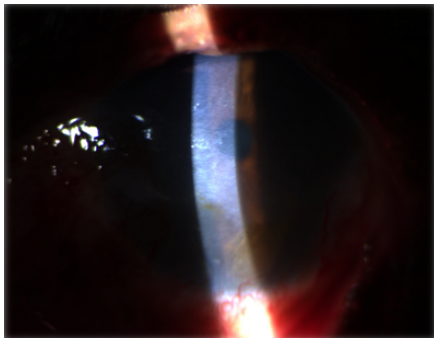

Figure 5 : Slit Beam Showing Corneal Edema

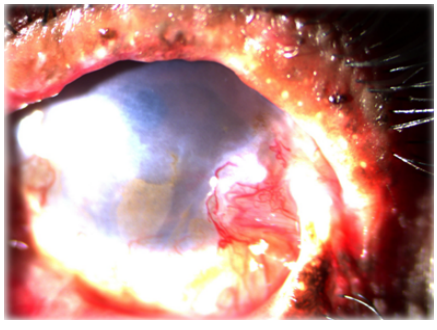

Figure 6 : Anterior Symblepharon

Routine investigations were within normal limits. FNAC right cheek mass revealed features suggestive of basal cell carcinoma. MRI revealed 4.7 ×3.8 ×2.8 cm heterogenous mass with predominantly T2 hyperintensity in right cheek showing loss of fat planes with buccinators muscle.a 3.2×2.1 cm enlarged lymph node with heterogenous signal in right upper jugular region.Her younger brother was also found to have similar manifestations with both cutaneous and ocular manifestations in addition to some amount of mental retardation.



DISCUSSION :

Ocular manifestations of XP are primarily ophthalmohelioses -- those that have been linked to UV exposure of the eyelids, cornea, or lens[5-7]. Entropion, ectropion and lid margin keratinization all can lead to meibomian gland dysfunction, which may result in alteration of the lipid layer of the tear film.The disease is usually inherited and recessive, tending to affect the children of consanguinous marriages.[1] Our case exhibited scattered, multiple hyperpigmented annular to oval macules & plaques & nodules particularly on the face, neck, upper part of the trunk and arms. Photophobia, tearing, ectropion of the lower lid, loss of eyelashes, conjunctivitis, exposure keratitis, were all present in our case- these being common ocular manifestations in xeroderma pigmentosa. Apart from that anterior symblepharon was also manifested in one of the siblings. Corneal pathology, occurring in 17–40% of XP cases, includes dryness, exposure keratitis, hazyness, band-like nodular keratopathy, scarring, ulceration, occasional perforation, and corneal opacity with vascularization[8,9] Our case showed interstitial keratitis with both superficial & interstitial vascularization of the cornea in the florid stage with filamentary keratopathy.Malignant lesions of eyelids was absent in both the siblings.

Iritis, iris atrophy and abnormal pigmentation of the iris, mental retardation, deafness, and joint malformations have been described as rare occurrence, but were absent in both the siblings except for mental retardation which was present in one of the sibling.

CONCLUSION :

XP is a rare disease (1 case in 500.000 newborn) that is inherited in an autosomal recessive form. Regular ophthalmologic evaluation is important in cases of xeroderma pigmentosa for early diagnosis and prevention of ocular morbidities. Strict sun protection measures, including use of fully shielding eyewear is important for all patients to prevent a spectrum of ophthalmologic abnormalities.

REFERENCES:

1. Gulati G C, Ahluwalia B K. Ocular involvement in xeroderma pigmentosum. Indian J Ophthalmol 1967;15:233-5
2. Kraemer KH, Lee MM, Scotto J. Xeroderma pigmentosum. Cutaneous, ocular, and neurologic abnormalities in 830 published cases. Arch Dermatol. 1987;123:241–250.
3. El-Hefnawi H, Mortada A. OCULAR MANIFESTATIONS OF XERODERMA PIGMENTOSUM. Br J Dermatol. 1965;77:261–276
4. Giller H, Kaufmann WC. Ocular lesions in xeroderma pigmentosum; a case report of carcinoma of the cornea. AMA Arch Ophthalmol. 1959;62:130–133
5. Norval M, Cullen AP, de Gruijl FR, et al. The effects on human health from stratospheric ozone depletion and its interactions with climate change. Photochem Photobiol Sci. 2007;6:232–51.
6. Taylor HR. Ultraviolet radiation and the eye: an epidemiologic study. Trans Am Ophthalmol Soc. 1989;87:802–53
7. Coroneo M. Ultraviolet radiation and the anterior eye. Eye Contact Lens. 2011;37:214–24.
8. Sevel D. Xeroderma Pigmentosum with Ocular Complications. Br J Ophthalmol. 1963;47
9. Touzri RA, Mohamed Z, Khalil E, et al. Ocular malignancies of xeroderma pigmentosum: clinical and therapeutic features. Ann Dermatol Venereol. 2008;135:99–104.