ORIGINAL RESEARCH PAPER

Volume-7 | Issue-5 | May-2018 | PRINT ISSN No 2277 - 8179

INTERNATIONAL JOURNAL OF SCIENTIFIC RESEARCH

URINARY TRACT INFECTION ASSOCIATED WITH A POLYPOIDAL GROWTH OF BLADDER IN CHILDREN - A RETROSPECTIVE STUDY

Pediatrics

Dr. Anuspandana Mahapatra Dept. of Pediatrics, IMS & SUM Hospital, SOA (Deemed to be University), Bhubaneswar

Dr. Akash Bihari Pati* Dept. of Pediatric Surgery, AIIMS, Bhubaneswar *Corresponding Author

ABSTRACT

Urinary tract infection presents as polypoidal bladder growth in pediatric age group and mimics urothelial neoplasm.

Material and methods: Retrospectively data of patients attending to a tertiary care hospital with urinary tract infection was collected. Patients having polypoidal bladder growth were studied.

Results: 234 patients presented with urinary tract infection of which six patients had polypoidal bladder growth. The growth subsided with treatment in five patients and one patient was diagnosed having low grade urothelial neoplasm.

Conclusion: Hematuria along with urinary tract infection can have polypoidal bladder growth on imaging even without any chronic irritating factor in pediatric patients

KEYWORDS

Polypoidal Cystitis, Pseudotumoral Cystitis, Papillary Growth Bladder

INTRODUCTION

Polypoidal growth in the urinary bladder of a paediatric patient is a rare occurrence. A bladder lesion described by radiology as a polyp is worrisome to the physician as well as the parents. The lesions become more worrisome when they are associated with haematuria. Such lesions are more commonly described after irritation of the bladder mucosa like injury or prolonged catheterization. Many bladder tumors in children are benign or reactive in nature. Information regarding the incidence and differential diagnosis of such lesions is scant in literature. The diagnosis of polypoidal bladder growth in some cases of urinary tract infection prompted us to retrospectively analyse the records of our institute for similar condition. We describe here our experience with polypoidal growth of bladder in paediatric age group.

MATERIAL AND METHODS

This is a retrospective study carried out in a tertiary teaching hospital of eastern India from 2013 to 2016. Records of all patients admitted to the pediatric ward and paediatric intensive care unit with a diagnosis of urinary tract infection, fever for evaluation, hematuria, surgical diagnoses of urinary tract infection like posterior valve, reflux nephropathy etc were analysed. The ultra-sonogram reports of all these patients were analysed to find out the diagnosis of polypoidal bladder growth. The follow up record of these patients with diagnoses of polypoidal bladder growth were analysed.

RESULTS

There were 234 admissions with diagnosis of urinary tract infection (UTI) and above mentioned causes. Polypoidal bladder growth on ultrasound was present in 6 (2.5%) cases (Fig 1). All these 6 patients had thickened bladder wall and no other predisposing anomaly was detected on USG for UTI. The age range of these patients was 2 to 13 years with a median of 4.7 years. There were 4 males and 2 female patients. All these patients had haematuria. Fever was present in 4 cases. One case was associated with severe worm infestations. Roundworms were crawling out of the anal orifice during examination. Urine of all six patients was examined to rule out UTI. All UTI patients had pus cells more than 50 per high power field in urine microscopy. Culture sensitivity of urine revealed E coli in 4 cases and Enterococcus in one case and streptococcus in one case. Sensitivity to netilmicin was present in all cases.

Three patients with E coli growth were sensitive to meropenem and amikacin in addition. The other case of E coli growth was sensitive to amoxyclav in addition. Streptococcus was sensitive to ampicillin, gentamycin and meropenem. Enterococcus was sensitive to Tigecycline, Colistin and amikacin. Antiboitics were given according to the culture sensitivity pattern and in a dose appropriate to the weight of the patient. All patients were followed up for subsidence of urinary tract infection and mean period for recovery was 8 to 21 days, mean 17 days. After subsidence of UTI and symptoms patients were subjected to repeat ultrasonogram. Polypoidal mass had disappeared in all except one patient. On further investigation with cystoscopy (Fig 2) and biopsy we diagnosed the case to be having a low grade non invasive urothelial neoplasm of bladder which was treated by transurethral resection of bladder tumor and is on regular follow up.

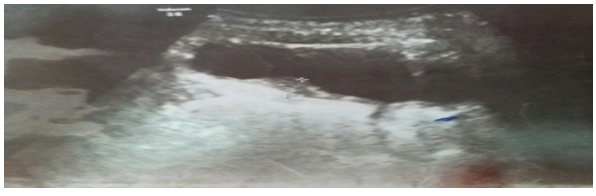

Fig 1. Polypoidal cystitis on ultrasonogram

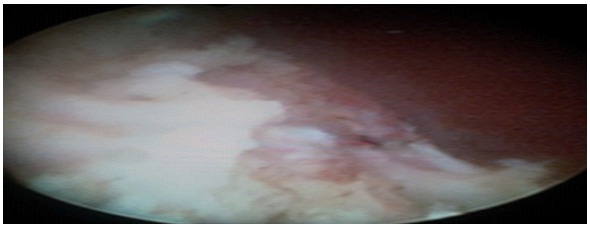

Fig 2. Cystoscopic view of the Low Grade Urothelial Neoplasm

DISCUSSION

Cystitis presenting as a mass in the bladder is a very rare occurrence. Mostofi coined the term “polypoid cystitis” for such lesions resulting from insult to bladder mucosa in 1954 [1]. Various nomenclatures have been reported in the literature for such type of lesions like pseudotumoral cystitis, cystitis follicularis, cystitis glandularis etc. [2]. Such mass like appearance may occur due to focal edematous changes within the lamina propria or proliferation of mucosal or submucosal glands in the epithelial layer. Eosinophillic cystitis is a rare differential diagnosis and also has a mass like appearance due to antigenic reaction and release of inflammatory mediators [3]. In all our cases we had elevated total count with neutrophillia. Eosinophillia was present in only one case which was associated with worm infestation.

The presence of indwelling catheter is a well recognized etiology for polypoid cystitis though in the present report we have found no such catheterisation prior to diagnosis in all 5 cases [4]. Any factor that irritates the bladder mucosa can result in polypoid cystitis like colovesical fistula, lower urinary tract obstruction, calculi, radiation etc. [5].

Differentiation between polypoidal cystitis and papillary carcinoma bladder is difficult. The later is a rare occurrence in paediatric age group and is commonly a papillary urothelial neoplasm of low malignant potential. In the present series one out of the 6 cases had a neoplasm. The polypoidal growth in this patient did not subside after antibiotics and hence cystoscopy and biopsy was done to confirm the diagnosis. However no urinary cytology was done for any of the patient though urinary cytology is of poor diagnostic value in on low grade urothelial neoplasm. Clinical, radiological and cystoscopic findings are difficult to differentiate between polypoid cystitis and urothelial neoplasm low grade. Lane and Epstein [5] have described a series of 41 cases where polypoidal cystitis has been misdiagnosed as low grade urotelial neoplasm. An inflamed background with absence of nuclear polymorphism and hyperchomasia is the key to diagnose poypoidal cystitis in paediatric patients histopathologically. Immunohistochemistry does not play a significant role in differentiation between the two entities.

While investigating hematuria associated with UTI the presence of a polypoidal mass in the bladder is a rare occurrence. Such finding alerts the clinician towards a diagnosis of urothelial neoplasm. Even in the absence of chronic irritating cause, polypoidal cystitis can occur in paediatric age group moreover incidence of urothelial neoplasm is rare. Hence appropriate investigations and follow up plan can be made for confirmation and prognosticating the disease.

ACKNOWLEDGEMENTS:
We are thankful to Prof. Dr. MR Nayak, Honorable President, Siksha 'O' Anusandhan (Deemed to be University), Bhubaneswar. We also acknowledge Mr. Somadatta Das, Central Research Laboratory, IMS & SUM Hospital, for his technical support in submitting the manuscript.

REFERENCES

1. Mostofi FK. Potentialities of bladder epithelium. J Urol. 1954;71: 705–714.
2. Rosenberg HK, Eggli KD, Zerin JM, et al. Benign cystitis in children mimicking rhabdomyosarcoma. J Ultrasound Med 1994;13(12):921–932.
3. Zhou AG, Amin A, Yates JK, et al. Mass forming eosinophilic cystitis in pediatric patients. Urology 2017;101:139–141.
4. Ekelund P, Johansson S. Polypoid cystitis: a catheter associated lesion of the human bladder. Acta Pathol Microbiol Scand [A]. 1979;87A:179–184.
5. Lane Z, Epstein JI. Polypoid/Papillary Cystitis: A Series of 41 Cases Misdiagnosed as Papillary Urothelial Neoplasia. Am J Surg Pathol 2008;32:758–764