ORIGINAL RESEARCH PAPER

Volume-8 | Issue-3 | March-2019 | PRINT ISSN No 2277 - 8179

INTERNATIONAL JOURNAL OF SCIENTIFIC RESEARCH

UTILITY OF SQUASH CYTOLOGY IN DIAGNOSING CNS LESIONS

Pathology

Badiginchala Suguna	MD Pathology, Senior Resident , Department of Pathology, Sri Venkateswara Institute of Medical Sciences(SVIMS), Tirupati.
Amit Kumar Chowhan*	MD Pathology, Associate Professor , Department of Pathology, Sri Venkateswara Institute of Medical Sciences(SVIMS), Tirupati. *Corresponding Author
Rukmangadha Nandyala	MD Pathology, Associate Professor , Department of Pathology, Sri Venkateswara Institute of Medical Sciences(SVIMS), Tirupati.
Prasad C M Bodapati	MS, MCh Neurosurgery, Professor, Department of Neurosurgery, Sri Venkateswara Institute of Medical Sciences(SVIMS), Tirupati.
Aruna Kumari Prayaga	MD Pathology, Professor , Department of Pathology, Sri Venkateswara Institute of Medical Sciences(SVIMS), Tirupati.

ABSTRACT

BACKGROUND: The different modalities used for intraoperative consultation of CNS lesions are squash smear cytology, frozen sections & fluid cytology. The intraoperative diagnosis of squash cytology enables the surgeon to take decision regarding treatment. Squash technique requires small sample size, needs minimal technical equipment, is less expensive and gives better morphological detail. The present study was taken to assess the diagnostic accuracy of intraoperative squash cytology of CNS lesions.

MATERIAL AND METHODS: It is a prospective study conducted for one and half year in the department of Pathology. All lesions of brain and spinal tract comprised the study group. The stain used for squash cytology was rapid haematoxylin and eosin. The squash diagnosis was compared with gold standard histopathology.

RESULTS: Total 96 cases were studied. Male to female ratio was 1.13:1. The overall concordance rate was 89.13% (including both complete and partial agreement cases). Good correlation was noted in diffuse astrocytoma (100%) and least correlation was noted in anaplastic oligodendroglioma (28.5%).

CONCLUSION: Squash cytology is a rapid and simple technique for intraoperative diagnosis with high overall accuracy.

KEYWORDS

CNS lesions, intraoperative diagnosis, squash cytology

Introduction

The intraoperative cytology preparation was first introduced by Eisenhardt and Cushing in early 1930 and by Badt in 1937.[1,2] This technique was further championed and documented by Russell et al[3] in 1937. The squash smears provide a preliminary diagnosis, enabling the surgeon to take a decision regarding further management at the operation table.[4] The ideal method for providing intraoperative diagnosis, apart from being rapid & accurate, should allow tissue to be preserved for further paraffin embedding.[5] The application of smear technique is a means of obtaining rapid diagnosis for neurosurgical biopsies.[6] Due to high fat as well as water content & soft nature of brain tissue which produces poor quality frozen sections & freezing artefacts, squash technique is preferred rather than frozen sections in the routine neurosurgical practice.[5] The present study was done to assess the accuracy and utility of intraoperative squash cytology in the evaluation of CNS lesions and to evaluate the common reasons for misdiagnosis on squash cytology.

Materials and Methods

This is a prospective study conducted in the Department of Pathology, Sri Venkateswara Institute of Medical Sciences (SVIMS), Tirupati. The study was conducted after obtaining approval from the thesis protocol committee & Ethical Review Committee (IEC No: 528 / dated / 29.02.2016). The study subjects were patients admitted to the Department of Neurosurgery for space occupying lesions of both brain and spinal cord.

Inclusion criteria:

All cases of intraoperative neuropathological specimens of brain and spinal cord received between March 2015 and June 2017 were assessed.

Exclusion criteria:

Small sample where all the material had to be squashed and where paraffin tissue could not be examined for histopathology.

Detailed clinical history of the patients such as presenting symptoms, location of lesion and radiological findings were noted.

Preparation of squash smears:

Upon receiving the requisition and the specimen, the specimen container and the requisition were checked to ensure that all the information is correct. First, the specimen was inspected grossly and variable areas of tissue were selected for squash technique. Then 0.5-1 mm^2 of tissue was dissected with a scalpel and placed at one end of a labelled clean glass slide. Then the smear was made by crushing the tissue with the second slide and drawing the second slide quickly across the first slide in order to produce a relatively uniform tissue layer. Minimum of three to five smears were made depending on the amount and sample of tissue received. The smears were rapidly fixed in 95% isopropyl alcohol for one or two minutes. The smears were stained with rapid haematoxylin and eosin stain, where differentiation in acid alcohol is not required and takes around 3 minutes for the procedure. The remaining tissue after squash technique was preserved in buffered formalin for further routine paraffin processing. The tumours were reported according to WHO 2007 classification system.

Diagnostic categories:

The squash diagnosis was compared with the gold standard test i.e. final histopathology and the cases were divided into four categories: 1) **Complete agreement**: when there was complete correlation between intraoperative squash diagnosis and final histopathology report. 2) **Partial agreement**: When the cell of origin was same, but there was difference in tumour grading. 3) **Disagreement**: Difference in cell of origin. 4) **Deferred**: When squash diagnosis was deferred for final histopathology report.

The overall concordance rate was calculated including both complete and partial agreement.

Immunohistochemistry was performed on few of the cases for which differentials were given on Haematoxylin & Eosin stain. The final diagnosis concluded after Immunohistochemistry (IHC) result was taken into consideration when comparing with squash diagnosis.

Results:
Total 96 cases of CNS lesions (Including both neoplastic and non neoplastic) during the period from March 2016 to June 2017 were included in the study. Out of these, 4 cases which were included under deferred category were excluded from the statistical analysis.

In the present study, age of the patients ranged from 3 to 73 years, youngest being 3 years female and oldest being 73 years male. Majority of the patients were in 5th decade (21.8%) followed by 3rd and 6th decades (19.79% each). Male: Female ratio was 1.13:1.

Of the 96 lesions, 82 cases (85.5%) were intracranial and 14 cases (14.5%) were spinal in location. Majority of the intracranial lesions were supratentorial (80.49%) in location [Table1].

Table1: Location wise distribution of intracranial lesions

Location	Number of cases
Supratentorial lesions	**66 (80.49%)**
Frontal region	14 (17.07%)
Frontoparietal region	5 (6.09%)
Frontotemporal region	5(7.57%)
Infratemporal	1(1.22%)
Insular region	3(3.66%)
Temporal region	12(14.28%)
Parietal region	7(8.53%)
Parieto occipital region	2(2.44%)
Parasagittal region	1(1.22%)
Corpus callosum	1(1.22%)
Petroclival region	1(1.22%)
Parafalcine region	1(1.22%)
Anterior falcine region	1(1.22%)
Basal ganglia	1(1.22%)
Thalamus region	2(2.44%)
Hypothalamus region	1(1.22%)
Suprasellar region	1(1.22%)
Sellar region	2(2.44%)
Pituatory region	2(2.44%)
Pineal gland	1(1.22%)
Lateral ventricle	1(1.22%)
Third ventricle	1(1.22%)
Infratentorial region	**16(19.51%)**
Cerebellar region	7(8.53%)
Pontine region	1(1.22%)
Cerebellopontine region	6(7.32%)
4th ventricle	1(1.22%)
Trigeminal region	1(1.22%)
Total cases	**82(100%)**

In a total of 96 cases (including both neoplastic and non neoplastic lesions), 72 showed complete agreement with final histopathological diagnosis, 10 cases showed partial agreement, 10 cases showed disagreement and remaining 4 cases were deferred [Table 2].

The CNS lesions of the present study are divided into glial, neuronal, mixed neuronal glial and non glial / non-neuronal in origin. Among them 46 were glial / neuronal and 46 were non-glial / non-neuronal excluding the deferred cases. The overall concordance rate for glial / neuronal tumours was 86.95% and 91.3% for non glial / non neuronal tumours [Table 2].

Table 2: Distribution according to glial / neuronal and non-glial / non-neuronal origin (excluding 4 deferred cases)

Category	Glial / Neuronal Lesions (n = 46)	Non glial / non neuronal lesions (n = 46)	Total (n = 92)
Complete agreement	30 (65.21%)	42 (91.3%)	72 (78.26%)
Partial agreement	10 (21.73%)	-	10 (10.87%)
Disagreement	6 (13.04%)	4 (8.67%)	10 (10.87%)
Overall accuracy (excluding deferred cases)	(40) 86.95%	(42) 91.3%	(82) 89.13%

The majority of glial lesions were astrocytomas(45.65%) [Figure 1] followed by oligodendrogliomas(34.78%) [Figure 2] and least common being glioneuronal tumor i.e. dysplastic cerebellar gangliocytoma(2.17%). Glioblastomas(66.66%) [Figure 3] were the most common lesions among all astrocytomas. Among non- glial / non - neuronal lesions, majority being schwannomas(45.65%) followed by meningioma(23.9%), haemangioblastomas(8.69%) and less commonly craniopharyngiomas(4.34%), primitive neuroectodermal tumours (4.34%) and other rare tumours.

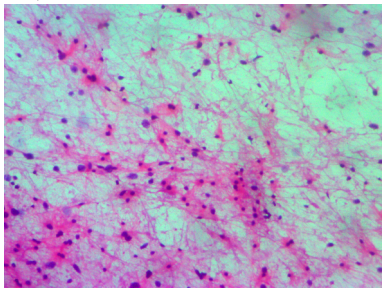

Figure 1: Diffuse astrocytoma: Mildly cellular smear with astrocytes showing mild nuclear pleomorphism (H&E X 200).

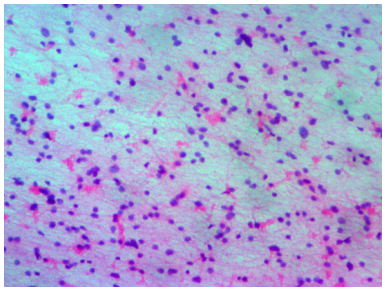

Figure 2: Oligodendroglioma: Moderately cellular smear with round tumour cells displaying uniform nuclei, speckled chromatin and scant cytoplasm with occasional mitotic figure (H&E X200).

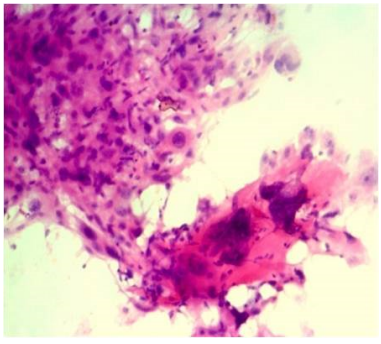

Figure 3: Giant cell glioblastoma: Poorly spread smear with astrocytes arranged in clusters displaying marked nuclear pleomorphism and bizarre looking multinucleate giant cells (H&E X200)

In our study, concordance rate for intracranial and spinovertebral lesions were 88.4% and 92.8% respectively. The overall concordance rate was 89.13% (including both complete and partial agreement cases) and the accuracy for the cases showing only complete agreement was 78.26%, excluding deferred cases.

DISCUSSION:
Squash cytology of CNS lesions is used to confirm or exclude the presence of neoplasia, to know the tumour cell type and histological grade of the tumour. Squash cytology is a worldwide method for intraoperative consultation, especially for CNS lesions, because it provides a rapid diagnosis, requires small sample size, minimal technical equipment, is less expensive and gives better morphological detail.7 Pathologist should pay attention to the nuclear details, mitotic activity, presence of necrosis, microvascular proliferation and radiological location of tumours for definite diagnosis. The reported diagnostic accuracy of cytological smears ranged from 75% to 94% in various studies existing in the literature.8,9 The overall concordance rate of the present study is 87.75% which is comparable to many

studies5,6,7,10 [Table3].

Table 3: Comparison with other studies

	Lesions	Commonly misdiagnosed lesions	% of concordance
Roessler K et al[7] (2002)	All Tumours	Oligodendrogliomas	95%
Goel et al[6] (2007)	All Tumour + Infections	Oligodendrogliomas	85%
Kini JR et al[10] (2008)	All Tumour + Infections	Oligodendrogliomas	86%
Krishnani et al[5] (2012)	All Tumour + Infections	Oligodendrogliomas	79.9%
Present study (2018)	Tumor + infections	Anaplastic oligodendrogliomas	87.75%

Astrocytomas(22.82%) followed by schwannomas(13.04%) and meningiomas(11.95%) were the most common tumours found in this study. Good correlation was seen in schwannoma(100%), diffuse astrocytoma(100%), subependymoma (100%) [Figure 4] meningioma (90.9%), hemangioblastoma (100%) and craniopharyngioma(100%) [Table 4]. The lesions frequently misdiagnosed on squash cytology were anaplastic oligodendrogliomas(57.1%) followed by glioblastomas (35.7%) and oligodendrogliomas (20%) similar to that of Krishnani N et al5 and Goel D et al.[6]

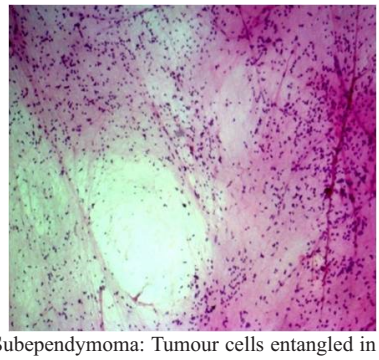

Figure 4: Subependymoma: Tumour cells entangled in the fibrillary material and twisted around each other to enclose large cystic spaces (H&E X100).

Table 4: Table showing concordance rate of all intracranial and spinovertebral lesions included in the study (excluding deferred cases).

	Squash Cytology										
	Biopsy		Complete agreement		Partial agreement		Disagreement		Concordance rate		
	B	S	B	S	B	S	B	S	B	S	Total
Diffuse astrocytoma(5)	5	-	5	-	-	-	-	-	100%	-	100%
SEGA(1)	1	-	-	-	1	-	-	-	100%	-	100%
Anaplastic astrocytoma(2)	2	-	1	-	1	-	-	-	100%	-	100%
Glioblastoma(14)	14	-	9	-	4	-	1	-	92.85%	-	92.85%
Oligoastrocytoma(2)	2	-	2	-	-	-	-	-	100%	-	100%
Oligodendroglioma(10)	10	-	8	-	1	-	1	-	90%	-	90%
Anaplastic oligodendroglioma(7)	7	-	3	-	3	-	1	-	85.7%	-	85.7%
Subependymoma(1)	1	-	1	-	-	-	-	-	100%	-	100%
Ependymoma(1)	-	1	-	1	-	-	-	-	-	100%	100%
Choroid plexus papilloma(1)	1	-	1	-	-	-	-	-	100%	-	100%
Choroid plexus carcinoma(2)	2	-	-	-	-	-	2	-	0%	-	0%
DNT(1)	1	-	1	-	-	-	-	-	100%	-	100%
Dysplastic cerebellar gangliocytoma(1)	1	-	-	-	1	-	-	-	100%	-	100%
Meningioma(11)	9	2	9	2	-	-	-	-	100%	100%	100%
Schwannoma(12)	6	6	6	5	-	-	-	1	100%	83.3%	91.6%
Hemangioblastoma(4)	4	-	4	-	-	-	-	-	100%	-	100%
PNET(2)	-	2	-	2	-	-	-	-	-	100%	100%
Pituatory adenoma(1)	1	-	1	-	-	-	-	-	100%	-	100%
Medulloblastoma(1)	1	-	1	-	-	-	-	-	100%	-	100%
Craniopharyngioma(2)	2	-	2	-	-	-	-	-	100%	-	100%
Esthesioneuroblastoma(1)	1	-	1	-	-	-	-	-	100%	-	100%
Chondrosarcoma(1)	-	1	-	1	-	-	-	-	-	100%	100%
Choriocarcinoma(1)	1	-	1	-	-	-	-	-	100%	-	100%
Atypical teratoid tumor(1)	1	-	-	-	-	-	1	-	0%	-	0%
Granulomatous inflammation(5)	1	4	1	4	-	-	-	-	100%	100%	100%
Reactive gliosis(1)	1	-	-	-	-	-	1	-	0%	-	0%
Non specific inflammatory pathology(1)	1	-	-	-	-	-	1	-	0%	-	0%
Total cases (92)	76	16	57	15	11	0	8	1			

B - Brain, S - Spinal cord, SEGA - Subependymal giant cell astrocytoma, DNT - Dysembryoplastic neuroepethelial tumor, PNET- Primitive neuroectodermal tumor.

Among all the anaplastic oligodendrogliomas(WHO grade III) included in the study (n=7), four cases were under graded as oligodendroglioma(WHO grade II) on squash cytology [Table 5]. A complete correlation of glial tumours could not be offered due to sampling error and due to the fact that grading may vary from one area to another in the same tumour. One case of anaplastic oligodendroglioma was misdiagnosed as small round cell tumour because the smears from oligodendroglioma show uniform round nuclei and speckled nuclear chromatin and the round cell morphology and they mimic as small round cell tumour.

Table 5: Evaluation of misdiagnosed cases

Final histopathological diagnosis	Cases showing partial agreement	Cases showing disagreement
Anaplastic oligodendroglioma(4)	Oligodendroglioma(3)	PNET(1)
Glioblastoma(5)	Astrocytoma(3) PXA(1)	Poorly differentiated carcinoma(1)
Oligodendroglioma(2)	Anaplastic oligodendroglioma(1)	PNET(1)
Choroid plexus carcinoma(2)	-	Anaplastic ependymoma(1) Metastatic Adenocarcinoma (1)
SEGA(1)	GBM(1)	-
Atypical teratoid/rhabdoid tumor(1)	-	Astrocytoma(1)
Schwannoma(1)	-	Fibrous Meningioma(1)

Dysplastic cerebellar gangliocytoma(1)	-	Low grade glioma(1)
Reactive gliosis(1)	-	Astrocytoma(1)
Anaplastic pleomorphic Xanthoastrocytoma(1)	Pleomorphic Xanthoastrocytoma(1)	-
Non specific inflammatory pathology(1)	-	Mucormycosis(1)

In the present study, of all the glioblastomas(WHO grade IV), three cases showed bizarre looking giant cells with markedly pleomorphic nuclei and were correctly diagnosed. Glioblastomas were misdiagnosed as low grade gliomas, metastasis and pleomorphic xanthoastrocytoma. The discrepancy among the grading might be due to sampling error and missing the necrotic areas while preparing smears. One case was misinterpreted as pleomorphic xanthoastrocytoma (PXA) due to the marked pleomorphic cells arranged in a fibrillary background and it was a diagnostic dilemma even on histopathology sections. One case was misdiagnosed as poorly differentiated carcinoma due to high cellularity, pleomorphism and the round to polygonal appearance of the cells and sometimes gemistocytes were mistaken for mucinophages.[6]

Oligodendrogliomas can be easily misdiagnosed as ependymoma, lymphoma and other small round cell tumour on squash cytology due to scant cytoplasm and uniform round slightly dark nuclei with inconspicuous nucleoli and lack of the fibrillary background. Perinuclear halos that give oligodendroglioma the 'fried-egg' appearance on paraffin sections is an artefact of fixation and does not present on smears.

Oligoastrocytomas showed 100% correlation with final paraffin section diagnosis in the present study. However many studies in the literature showed difficulties in diagnosing mixed gliomas due to predominance of one histological type. The smaller component may be missed partly due to sampling error and because of the dense fibrillary background of the astrocytic component.[11,12]

A case of choroid plexus carcinoma was misinterpreted as anaplastic papillary ependymoma due to papillary configuration of the cells and their arrangement around the blood vessels. However ependymoma show gliofibrillary background and typical perivascular pseudorosette formation. Pleomorphic xanthoastrocytoma was mistakenly diagnosed on squash cytology as glioblastoma due to presence of marked nuclear pleomorphism.[13]

In the present study a case of subependymal giant cell astrocytoma was overgraded as glioblastoma on squash cytology because of the presence of considerable pleomorphism, large vesicular nuclei, prominent nucleoli and focal necrotic areas. In general sometimes necrosis can be seen in SEGA which can be misdiagnosed as high grade glioma on squash cytology.

Reactive gliosis was a rendered false positive diagnosis on cytology as low grade astrocytoma in our study. Smears of this case had minimal anisocytosis with fine to coarsely granular chromatin and inconspicuous nucleoli, the cytoplasm was scant and showed variable processes with fibrillary background. Similar misinterpretation of diagnosing reactive gliosis as low grade astrocytoma has been reported in a study done by Sanjeev et al.[13] Reactive astrocytes have abundant cytoplasm and more prominent numerous, long and symmetrical processes. As compared to neoplastic astrocytes these lack hyperchromatic and lobulated nuclei, progressive atypia and mitosis. Smears of low grade astrocytoma had minimal anisocytosis with fine to coarse granular chromatin and inconspicuous nucleoli, the cytoplasm was scant and showed variable processes with fibrillar background.

One case of schwannoma misinterpreted as fibrous meningioma due to spindle nature of cells and lack of typical whorling formation, which is seen usually in classical meningiomas. Kobayashi S et al[14] also described similar misinterpretation in their result.

A case of dysplastic cerebellar gangliocytoma was misdiagnosed as low grade astrocytoma on squash cytology due to presence of ganglion cells which may mimic as gemistocytes on squash cytology.

One case of medulloblastoma showed complete correlation with paraffin section diagnosis. Smears are highly cellular with cells exhibiting carrot shaped nuclei, nuclear moulding, scant cytoplasm with Homer-Wright pseudorosettes as described in a study done by Deshpande et al.[15]

In our study a case of atypical teratoid / rhabdoid tumour was misinterpreted as low grade astrocytoma as the rhabdoid cells due to eccentrically placed nucleus and abundant cytoplasm gives a appearance of gemistocytes which can be misdiagnosed as gemistocytic astrocytoma on squash cytology and the tumour was located in cerebellum.

Tuberculous lesions [Figure 5] showed 100% correlation with histopathology in our study. Sometimes the reactive astrocytes surrounding the lesion can be sampled by mistake and over diagnosed as neoplastic astrocytes.

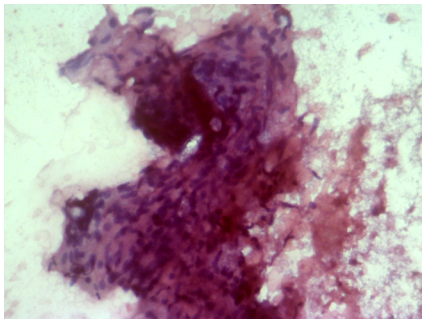

Figure 5: Showing epithelioid cellular cluster on squash cytology with slipper shaped nuclei (H&E 200X).

Few of the cases included in the study were diagnosed after Immunohistochemistry on histopathology, they include atypical teratoid / rhabdoid tumour, choroid plexus papilloma, glioblastoma and dysembryoplastic neuroepthelial tumor (DNT).

The deferred cases were those on which no opinion was possible on squash smears and the most common causes being fibrosis, inflammation, calcification, necrosis and lack of definite morphological details. In the present study 4 cases were deferred, of which one case showed only necrosis in a glioblastoma case, other showed only blood clot in a haemangioblastoma case and other two cases were pituitary adenoma and craniopharyngioma in which the tissue was very scant for cytological interpretation.

The pathologist's goal in the intraoperative setting should be to provide sufficient information for optimal surgery i.e. whether the tumour is either benign or malignant rather than to provide a precise diagnosis and accurate grade for each case. A correct intraoperative diagnosis is necessary because an adverse impact occurs when a malignant tumour is diagnosed as benign or vice-versa.

Limitations of squash cytology

As limited amount of tissue is sampled for squash cytology there are chances of missing pleomorphic and necrotic areas which are important for grading glial lesions. In oligodendrogliomas, perinuclear halo of the cells provide clue for identification which is usually an fixation artefact, absent on squash smears. Frozen sections are preferable for non squashable lesions like meningiomas, schwannomas and vascular lesions rather than squash cytology.

CONCLUSION:

To conclude, squash smear technique is an accurate and rapid method of intraoperative diagnosis. Accuracy can be improved by paying attention to cellularity, nuclear features, nature of background tissue, correlating with radiological localization and the neurosurgeons intraoperative impression.

ACKNOWLEDGEMENT:

We would like to express our special thanks to S. Usha Nandini and R. Ramana for performing excellent cytological and histology sections and stains.

REFERENCES:

1. Eisenhardt L, Cushing H. Diagnosis of Intracranial Tumours by Supravital Technique. Am J Pathol 1930;6:541-52.
2. Berkeley BB, Adams JH, Doyle D, Graham DI, Harper CG. The smear technique in the

diagnosis of neurosurgical biopsies. N Z med J 1978;87:12-5.
3. Russell DS, Krayenbuhl H, Cairns H. The wet film technique in the histological diagnosis of intracranial tumours: a rapid method. Am J Bacteriol 1937;45:501-5.
4. Adams JH, Granam DJ and Doyle D. Brain Biopsy. The smear technique for Neurosurgical biopsies. Biopsy Pathology series, Chapman and Hill Pub. London;1981.
5. N.Krishnani, N.Kumari, S.Behari, C.Ran, P.Gupta. Intraoperative squash cytology: diagnostic accuracy and its impact on immediate surgical management of central nervous system tumours. Cytopathology 2012;23:308-14.
6. D.Goel, C.Sundaram, T.R.Paul, S.G.Uppin, A.K.Prayaga, M.K.Panigrahi et al. Intraoperative cytology(squash smear) in neurosurgical practice – pitfalls in diagnosis experience based on 3057 samples from a single institution. Cytopathology 2007;18:300-
7. Roessler K, Dietrich W, Kitz K. High diagnostic accuracy of cytologic smears of central nervous system tumors, 15-year experience based on 4,172 patients. Acta Cytol 2002;46:667–74.
8. Firlik KS, Martinez J, Lunsford LD. Use of cytological preparations for the intraoperative diagnosis of stereo-tactically obtained brain biopsies: a 19-year experience and survey of neuropathologists. J Neurosurg 1999;91:454–8.
9. Silverman JF, Timmons RL, Leonard JR 3rd, Hardy IM, Harris LS, O Brien K et al. Cytologic results of fine needle aspiration biopsies of central nervous system. Cancer 1986;58:1117–21.
10. Kini JR, Jeyraj V, Jayaprakash CS, Indira S, Naik CNR . Intraoperative consultation and smear cytology in the diagnosis of brain tumours. Kathmandu University Medical Journal 2008;6:453-7.
11. Cahill EM, Hidvegi DF. Crush Preparations of Lesions of the Central Nervous System. A Useful Adjunct to the Frozen Section. Acta Cytol 1985;29:279-85.
12. Torres LFB, Collaco LM. Smear Technique for the Intraoperative Examination of Nervous System Lesions. Acta Cytol 1993;37:34-40.
13. Sanjeev K, Aparna B, Anuradha K, Brijesh T, Sanjay K, Neetika S. Intraoperative Squash Cytology of Central Nervous System and Spinal Cord Lesions with Histological Correlation. Annals of Pathology and Laboratory Medicine 2016;3:61-72.
14. Kobayashi S. Meningiomas, neurilemmoma and astrocytoma specimens obtained with the squash method for cytodiagnosis. A cytological and immunohistochemical study. Acta Cytol 1993;37:913-22.
15. Deshpande K, Surase S, Shedge R, D'costa G, Bharambe B. Accuracy and diagnostic yield of intraoperative squash smear technique in the rapid diagnosis of CNS lesions. Bombay Hosp J 2010;52:153-60.