ORIGINAL RESEARCH PAPER
VOLUME-6 | ISSUE-6 | JUNE-2017 | ISSN No 2277 - 8179 | IF : 4.176 | IC Value : 78.46
INTERNATIONAL JOURNAL OF SCIENTIFIC RESEARCH

Vagino-abdominal Approach on a challenging case of large prolapsed leimyoma-a success story!

Gynaecology

Dr Jyoti Kankanala MRCOG,DNB,DGO,DFFP,PGDMLS, Diploma in Laparoscopy(France), Consultant Obstetrician and Gynaecology, Citizens Hospitals, Hyderabad,Telangana,India,500019.

ABSTRACT

we report an interesting and challenging case of huge gangrenous prolapsed leiomyoma in a 48 yrs old para 1 living1 who presented with sudden protrusion of irreducible red color mass per vagina. On arrival patient was giddy and anaemic. Basic investigations were performed and patient had abdomino – vaginal approach for this case with a methodical approach and Patient did well post operatively.

Pedunculated myomas or submucosal cervical myomas are likely to protrude through the cervical canal and into the vagina and due to direct exposure become necrotic and occasionally infected due to inadequate blood supply.(3,4)

KEYWORDS:

Case report :

Mrs K , 48 yrs old para 1 living 1 presented to emergency room with hours of irreducible red mass protruding through vagina in early hours while straining through stools. She noticed vaginal mass 3 months ago prior to presentation. Occasionally protruding into introitus while bending and squatting, but did not report to doctors. She has complaints of urinary incontinence, frequency and urgency

On the day of presentation she was giddy and anaemic. Patient was resuscitated and blood sent for major surgical profile and 2 units cross-matched and blood transfused. After 10 hours of admission patient was posted for emergency vagino abdominal approach to tackle gangrenous prolapsed fibroid polyp. She had no other previous history of surgery. She was known to have Diabetes and hypertension controlled on medication.On examination she was distressed because of pain,temperature was normal but pale looking .There was no pedal oedema nor peripheral Lymphadenopathy.Pulse rate was 100 bpm,BP was 154/80 mm hg, X-ray chest 2D echo was done, it was normal . Abdominal examination was soft non tender.Vaginal examination (fig2) reveales large red color gangrenous mass 15 to 20 cm firm in consistency brownish red in color like hematoma and foul smelling .Culture sensitivity of part sent .Very difficult to locate cervix.(5)

MRI (Fig 1)done- showed procidentia with gross oedema of prolapsed uterus hemorrhaegic left ovarian cystEndometriotic cyst in right ovaryAnnular tear in L5-S1, disc desiccation with broad based posterior disc protrusion.

We suspected gangrenous prolapse leiomyoma and admitted to high dependency unit and was started on blood and antibiotics and requested laboratory investigations.Haemoglobin was 7.8gm% and normal platelets,other test including serum creatinine ,liver function test,serum electrolytes were all in normal range.Blood culture on admission showed no growth(36 hours).Patient was kept on I.V fluids ,Indwelling foleys catheter inserted without difficulty.Patient was taken after 11 hrs for surgery after high risk consent taken for septicaemia and damage to ureter and bladder emphasized as leiomyoma can compress the urinary bladder, urethra, and lower end of the ureters.(1)

After thorough preanaesthetic check up under general anaesthesia and all aseptic precautions , cefazolin as a prophylactic antibiotic given.Under lithotomy position, via Vaginal (3) approach used for myoma removed by blunt and sharp dissection., later Abdominal hysterectomy(fig 4) done. Thorough abdominal wash given patient kept on cefazoline and metrogyl.Within 24 hours no temperature noticed . After 24 hours patient developed temperature . Culture sensitivity showed Ecoli and patient was put on sensitive medication cefipime for 3 days.On discharge she was afebrile for 36 hours and no other signs of septicaemia noticed.Blood culture – negative on discharge . Her post operative recovery was satisfactory and 2 week follow up patient was fine.

Histology report showed Negative for malignancy.Incarcerated fibroid polyp(fig 3)with hemorrhagic degenerated due to severe UV prolapsed.B/L adnexal – hemorrhagic cysts (indirect evidence of endometriotic cysts)

DISCUSSION:--Incidence of leiomyoma = 20-40% in reproductive age women. Incidence of prolapsed gangrenous leimyoma. In this case patient was ill-looking with mass per vagina. Urinary symptoms present due to pressure/ mass effect. It is technically challenging situation. Procedure went uneventful due to careful planning.

CONCLUSION:

Prolapse fibroid polyps are rare entity and few cases in literature noted, were immediate action had been recommended to avoid sepsis.



Fig 1(MRI PELVIS)



Fig 2 mass outside the vagina



Fig 3 prolapsed fibroid polyp

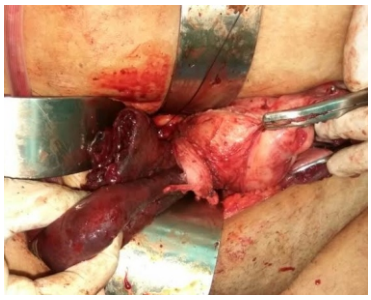

fig 4 Abdominal approach to remove completely.

References

1) Acute renal failure caused by prolapsed leimyoma,Barr S,Mclennan M,Schmitz PG.
2) Vaginal Myomectomy for a prolapsed uterine leimyoma Thomas G Stovall,Willam J
3) Ben-Baruch, G., Schiff, E., Menashe, Y., and Menczer, J. Immediate and late outcome of vaginal myomectomy for prolapsed pedunculated submucous myoma. Obstet Gynecol. 1988; 72: 858–861View in Article | PubMed
4) Golan, A., Zachalka, N., Lurie, S., Sagiv, R., and Glezerman, M. Vaginal removal of prolapsed pedunculated submucous myoma: a short, simple, and definitive procedure with minimal morbidity. Arch Gynecol Obstet. 2005; 271: 11–13
5) Kopal, S., Seckin, N.C., and Turhan, N.O. Acute uterine inversion due to a growing submucous myoma in an elderly woman: case report. Eur J Obstet Gynecol Reprod Biol. 2001; 99: 118–120