ORIGINAL RESEARCH PAPER

Volume-7 | Issue-8 | August-2018 | PRINT ISSN No 2277 - 8179

INTERNATIONAL JOURNAL OF SCIENTIFIC RESEARCH

VALIDATION OF VISUAL CLASSIFICATION OF MID-FACE ESTHETICS USING A CEPHALOMETRIC CUT-OFF IN ADULT INDIAN POPULATION

Dental Science

Dr. Sharad Kharyal	M.D.S. Orthodontics and DentofacialOrthopaedics, Private Practitioner, Jammu, J&k, India.
Dr. Mahesh Kumar Y*	M.d.s. Orthodontics And Dentofacialorthopaedics, Professor- Department Of Orthodontics And Dentofacialorthopaedics, K.v.g. Dental College And Hospital, Sullia, Karnataka, India.*Correponding Author
Dr. Revanth S Soonthodu	M.d.s. Orthodontics And Dentofacialorthopaedics, Senior Lecturer- Department Of Orthodontics And Dentofacial Orthopaedics, K.v.g. Dental College And Hospital, Sullia, Karnataka, India
Dr. Sharath Kumar Shetty	M.D.S. Orthodontics and DentofacialOrthopaedics, Professor and Head- Department of Orthodontics and DentofacialOrthopaedics, K.V.G. Dental College and Hospital, Sullia, Karnataka, India.
Dr.Fauzan Zaheer	M.D.S. Orthodontics and Dentofacial Orthopaedics, Private Practitioner, New Delhi, India.
Dr. Bhanu Kotwal	M.D.S. Periodontics, Lecturer, Deptt of Periodontics, Indira Gandhi Govt. Dental College, Jammu

ABSTRACT

Objective: To validate visual classification of mid-face esthetics using a cephalometric cut off.

Materials and Methods: Pretreatment records of 100 Adult Indian (15-25 years) were included in study. Statistical analysis was done using SPSS software version 20 (SPSS Inc., Chicago, IL, USA). Sella-Nasion-Orbitale angulations were measured for anteroposterior position of malar eminence relative to cranial base. Karl Pearson correlation test determined correlation of age and SNO angulation. The ROC analysis determined the cut off value of SNO angulation.

Results: The correlation between age and genders with SNO angulation was statistically insignificant. SNO angulations in negative vector group were significantly smaller by an average of 8.18 and a cut off value of SNO angle i.e., 56º was obtained.

Conclusion: Visual classification of anterior malar supportis supported by cephalometric analysis and can be used in ortyhodonticsto classify malar support tomidface.

KEYWORDS

Vector relationships, Midface esthetics, Cephalometric cut-off.

INTRODUCTION

Midface is a critical area for the aesthetics of the face.[1] Increasing malar prominence enhances the angularity and fullness of the midface.[2] Orbital rim and cheek bone contour deficiency correlates with maxillary hypoplasia which is often associated with true malar deficiency[3,4] People with midface deficiency tend to have a gaunt or hollow midface leading to increased show of the sclera inferior to the pupil.[5]Aging augments the hollowness as soft tissue atrophy and sagging reduces malar soft tissue prominence.[7]

Malar augmentation is a common procedure among plastic surgeons and otolarygologists and oral surgeons using Le Fort I, II, and III surgical procedures .[1,2,8]

Orthodontists, concerned with establishing facial beauty and balance, diagnose and treat according to the facial profile and the effects that treatment will have on the facial profile.[12-15] There is a minimal diagnostic criteria in orthodontic literature [16] to make accurate measurements of orbital relationships. Additionally, orthodontists focus entirely on premaxilla resulting in neglection of regional disharmonies.[16]

The ideal position of the cheek prominence should be 2mm beyond the anterior surface of the cornea in the sagittal plane along the Frankfurt horizontal.[16,18] Maxillary hypoplasia produces a negative vector relationship with the globe positioned anterior to malar eminence.[16-18] Inspite of its wide usage, the validity of the relationship between maxillary development and vector relationships has not been tested widely.

Though lateral cephalogram radiograph does not show the malar eminence but it is always lateral and inferior to the orbitale or point 109 on walker's mathematical model.[19] Measurements like SN, SNO, OANA and SNA evaluate the midface in a horizontal plane. SNO measurement represents the internal angle between the lines connecting Sella to Nasion and Nasion to Orbitale.[20] A reduced angle reflects the deficiency of upper midface and this information is of importance to the orthodontist to establish normal range of relationships .[19]

The clinical assessment of anterior malar projection showed significant relationship between cephalometric analysis and visual classification of anterior malar projection on profile photographs in white subjects[16] but is not assessed for other ethnic groups. Hence, this study was conducted to validate visual classification of mid-face esthetics using a cephalometric cut-off in Adult Indian population.

MATERIALS & METHODS

Pretreatment records of 100 Adult Indian subjects seeking orthodontic treatment in K.V.G. Dental College and Hospital, Sullia, Karnataka, India were included in the study. The subjects were equally divided into two groups of 50 each based on visual assessment of negative and positive vector relationships.

Group A included 50 subjects (25 males, 25 females) exhibiting a positive vector relationship.
Group B included 50 subjects (25 males, 25 females) exhibiting a negative vector relationship.
Age group: 15-25 years.

Inclusion criteria:

1. Good quality pretreatment lateral cephalograms and profile photographs standardized in Frankfurt horizontal plane.
2. No history of craniofacial trauma and ophthalmic problems.

Exclusion criteria:

1. Previous orthodontic treatment.
2. Craniofacial syndromes and history of maxillofacial surgery.

Methodology:
Lateral cephalograms and profile photographs standardized by orienting the patient's head in the Frankfort horizontal position were obtained from the patient's pretreatment records.

Each subject's vector relationship was determined by one operator, using only pretreatment profile photographs. The relationship of anterior cheek mass to the anterior corneal plane was established by marking a line from the anterior surface of cornea in the sagittal plane along the Frankfurt horizontal (Fig. I).

If the cheek prominence was behind the anterior surface of cornea, it was considered as negative vector relationship while if it was beyond the anterior surface of cornea, it was considered as positive vector relationship.

In order to quantify skeletal support for each subject, Sella-Nasion-Orbitale (SNO) angulation was used to evaluate the anteroposterior position of the malar eminence relative to the cranial base. For the purpose of this study, the orbitale was identified to coincide with Walker's cephalogram point 109[21]. The key ridge and the maxillary sinus were used as guides to consistently locate this landmark. All the lateral cephalograms obtained were carefully hand traced by the same observer.

Prior to the cephalometric analysis, 15 random lateral cephalograms from subjects in the study were selected, and SNO angles were traced and measured at two times. The intraclass correlation coefficient was calculated to estimate the intra observer agreement(ICC=.99)

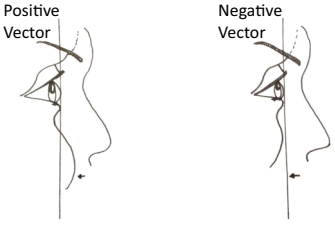

Fig. I Assessment Of Vector Relationships

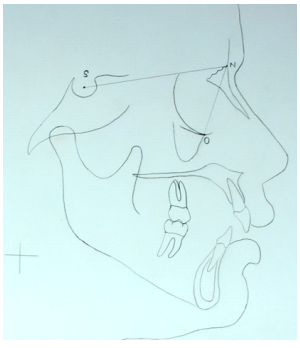

Fig. II Cephalometric Reference Points and variable SNO Angle.

Statistical Analysis
Statistical software SPSS version 20 was used to analyze the data.
The Student's t-test was used to determine if significant SNO angulation difference existed between the two groups and between different genders. The Karl Pearson correlation test was used to assess correlation between age of the subjects and SNO angulation. Statistical significance was set at P < .01 and P <.05 and the results were tabulated.

RESULTS
Table I shows that there is no statistical significant correlation between age and SNO angulation.

The analysis for sexual dimorphism in Table II shows no statistical significant difference between genders.

Table III and graph I shows mean SNO angulation of 52.11° in negative vector group with SD of 1.78°and 60.29° in positive vector group with SD of 1.80°. It also shows a highly significant difference in skeletal support between the negative and positive vector groups assessed using SNO angles and the negative vector group shows a smaller angle by an average of 8.18º.

The ROC analysis was done to obtain the cut off value of SNO angulation to differentiate negative and positive vector. Table IV and graph II shows the accuracy of ROC analysis and Table V shows the cut off value of SNO angle i.e. 56º with 100% specificity and 100% sensitivity.

Table I- Karl Pearson correlation between SNO angulation and age of the subjects. Correlations

	Karl Pearson Correlation coefficient r value	p	
Age(years) SNO Angulation(degree)	.114	.257	NS

NS- Not Significant.

Table II-Analysis for sexual dimorphism.

Sex	N	Mean	Std. Deviation	T test p value
F	50	56.330	4.8325	.773
M	50	56.070	4.1416	NS

Table IV-ROC analysis :- Area under the Curve

Area	Std. Error (a)	Asymptotic sig. (b)	Asymptotic 95% confidence interval	
			Lower Bound	Upper Bound
1.000	.000	.000	1.000	1.000

Table IV shows the accuracy of ROC analysis and area (=1.000) under the curve represents a perfect test.

Table III- Analysis of skeletal differences between positive and negative vectors. SNO Angulation(degree)

	N	Mean	Std. deviation	95% confidence interval for mean	t value		
				Lower bound	Upper bound		
Negative vector	50	52.11	1.78	51.60	52.62	22.8	P<0.0
	50	60.29	1.80	59.78	60.80	61	01
Positive vector	100	56.20	4.48	55.31	57.09		HS
Total							

HS- Highly Significant.

Table V- Coordinates of the Curve
Test Result Variable(s): SNO Angulation(degree)

Positive if Greater Than or Equal To(a)	Sensitivity	1 - Specificity
46.500	1.000	1.000
47.750	1.000	.980
48.250	1.000	.960
48.750	1.000	.940
49.250	1.000	.900
49.750	1.000	.860
50.250	1.000	.800
50.750	1.000	.780
51.250	1.000	.740
51.750	1.000	.720
52.250	1.000	.580
52.750	1.000	.460
53.250	1.000	.300
53.750	1.000	.200
56.000	1.000	.000
58.250	.960	.000
58.750	.840	.000
59.250	.640	.000
59.750	.500	.000
60.250	.340	.000
60.750	.300	.000
61.500	.240	.000
62.500	.160	.000
63.250	.080	.000
63.750	.060	.000
64.250	.040	.000
64.750	.020	.000
66.000	.000	.000

GRAPHS

Graph I- Mean SNO angulation in negative vector and positive vector groups.

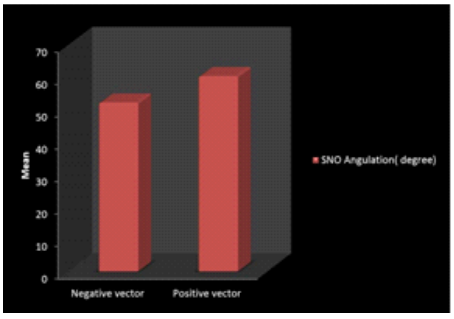

Graph II- The ROC analysis.

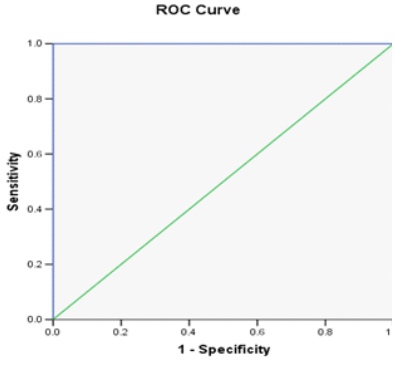

DISCUSSION

This study compared the relationship between visual classification on profile photographs and lateral cephalometric analysis of anterior malar projection in Adult Indian population. Sella-Nasion-Orbitale (SNO) angulations were measured to evaluate the validity of vector relationships as a mean of diagnosing midfaceesthetics. Comparison of angular measurements for SNO from the negative vector group with the positive vector group in this study showed highly significant ($P < .0001$) retrusion of the malar eminence by 8.18 degrees in subjects with a negative vector relationship. Frey ST in his study on white subjects also found thatthe SNO angulations in the negative vector group were smaller by an average of 6º.[16]

There were no statistically significant gender differences for SNO angulation in Adult Indian population which were in concurrence with the results of the study conducted by Frey ST in White population.[16]Suri R in her study onAngamiNagasconcluded that majority of the males had medium (30%) to pronounced (22%) malar prominence while majority of the females showed slight malar prominence (52%).[30] Also, Zide B et al, in their study had given different norms of SNO angulation for males and females.[20]

This study showed no significant correlation between age and SNO angulation which was similar to the results of Frey ST. Additionally, derived growth curves of sagittal orbital relationships have demonstrated the stability of vector relations from preadolescence into young adulthood. [22] However according to Pessa JE et al, with age, the orbital rim moved posteriorly, relative to the anterior cornea and negative vector became more pronounced.[23]Doual JM et al found that involution of the midface skeleton begins in the sixth decade and was more common in women.[24]The maxilla is more susceptible to age-related loss than the zygoma.[29] but in the present study in Adult Indian subjects, age group was between 15-25years during which midface prominence was relatively stable.

Wide variation in landmark identification of orbitale has been observed in the past [25]; however, using the protocols outlined in this study, excellent intraobserver agreement was attained for SNO measurements (ICC = .99). Though not directly examined by this study, it should be noted that numerous subjects demonstrating a negative vector relationship did not also display scleral show. Scleral show has been a traditional hallmark of maxillary hypoplasia, [26] but is less sensitive to deficiencies in malar development than vector relationships. A positive vector relationship has been identified in anthropometric studies as an important element of the youthful face and malar complex,[18] and should be considered the esthetic ideal.

In this study, SNO angle of 56º was developed as a cut off to differentiate negative and positive vectors in adult Indian population. Similarly, Zide B et al, provided normative data of SNO angulation for adult Caucasians aged 16 years or over as 60.9±4.2° for males and 53.5±4.8° for females.[20] However, esthetic norms should not be applied too rigidly across different racial backgrounds.

Deficient malar and midfacial projection leaves the soft tissues poorly supported, resulting in premature lower lid and cheek descent as well as visible bags, scleral show, and a more aged appearance.[18]

Although orthodontic treatment does not directly alter malar globe relationships, the balance between dentoalveolar and malar support has significant influence over the nasal base-lip contour (Nb-LC).[2] This interplay is important in assessing skeletal contributions to nasolabial contours, determining the optimal position of the upper incisor, and planning orthodontic anchorage if extractions are indicated for normalization of lip contours. Orthodontists must have a broad understanding of facial aging patterns. A comprehensive dentofacial analysis is central to the achievement of functional and cosmetic excellence in orthodontic treatment, and vector relationships serve as a useful diagnostic reference. Assessment of malar support will help enhance esthetic orthodontic outcomes and improve surgical orthodontic planning. The vector relationships also help in evaluating the need for alloplastic augmentation of the inferior orbital rim and selecting the appropriate maxillary surgery.

The present study suggests that vector relationship is an effective means of classifying anterior malar support and provides the orthodontist with a convenient means of classifying malar support to the midface and will help to better inform treatment decisions.

However, further studies extending to other ethnic groups and covering wider age rangesare required to establish norms and to use SNO angulation/vector relation in the day to day clinical practice.

Conclusion

Visual classification of anterior malar support using vector relationships is supported by cephalometric analysis and can serve as a useful tool in orthodontics with a convenient means of classifying malar support to the midface.

SNO angulation can be taken as a reference to estimate the anterior malar projection and the SNO angulation of 56° can be used as a cut off to differentiate negative and positive vectors in Adult Indian subjects.

References

1. Nørholt SE, Sindet-Pedersen S, Jensen J. An extended Le Fort I osteotomy for correction of midface hypoplasia: a modified technique and results in 35 patients. J Oral MaxillofacSurg 1996 Nov;54(11):1297–306.
2. Terino EO, Flowers RS. The Art of Alloplastic Facial Contouring. 1st ed. St. Louis: Mosby; 2000.
3. Arnett G. Facial keys to orthodontic diagnosis and treatment planning, part I. Am J OrthodDentofacialOrthop. 1993 Apr;103(4):299-312.
4. Arnett G, Bregman R. Facial keys to orthodontic diagnosis and treatment planning, part II. Am J OrthodDentofacialOrthop. 1993 May;103(5):395-411.
5. Schmidseder J. Aesthetic Dentistry. New York: Thieme; 2000.
6. Bell WH. Modern Practice in Orthognathic and Reconstructive Surgery: Volume 2. Philadelphia: W B Saunders Co; 1992.
7. Powell NB, Riley RW, Laub DR. A new approach to evaluation and surgery of the malar complex. Ann PlastSurg 1988 Mar;20(3):206–14.
8. Kim Y-I, Park S-B, Son W-S, Hwang D-S. Midfacial soft-tissue changes after advancement of maxilla with Le Fort I osteotomy and mandibular setback surgery: comparison of conventional and high Le Fort I osteotomies by superimposition of cone-beam computed tomography volumes. J Oral MaxillofacSurg 2011 Jun;69(6):e225–33.
9. Jensen J, Reiche-Fischel O, Sindet-Pedersen S. Autogenous mandibular bone grafts for malar augmentation. J Oral MaxillofacSurg 1995 Jan;53(1):88–90.
10. Nout E, Cesteleyn L, van der Wal K, van Adrichem L, Mathijssen I, Wolvius E. Advancement of the midface, from conventional Le Fort III osteotomy to Le Fort III distraction: review of the literature. Int J Oral MaxillofacSurg 2008 Sep;37(9):781–9.
11. Urban SD, Rebellato J, Keller EE. Intraoral maxillary quadrangular Le Fort II osteotomy: a long-term follow-up study. J Oral MaxillofacSurg 2004 Aug;62(8):943–52.
12. Holdaway RA. A soft-tissue cephalometric analysis and its use in orthodontic treatment planning. Part I. Am J Orthod 1983 Jul;84(1):1–28.
13. Holdaway RA. A soft-tissue cephalometric analysis and its use in orthodontic treatment planning. Part II. Am J Orthod 1984 Apr;85(4):279–93.
14. Merrifield LL. The profile line as an aid in critically evaluating facial esthetics. Am J Orthod 1966 Nov;52(11):804–22.
15. Downs WB. Analysis of the Dentofacial Profile. Angle Orthod 1956 Oct;26(4):191–212.
16. Frey ST. New diagnostic tenet of the esthetic midface for clinical assessment of anterior malar projection. Angle Orthod 2013 Sep;83(5):790-4.
17. Jelks G, Jelks EB. The influence of orbital and eyelid anatomy on the palpebral aperture.

ClinPlastSurg 1991 Jan;18(1):183-95.
18. Yaremchuk M. Infraorbital rim augmentation. PlastReconstrSurg 2001;107:1585-1592.
19. Leonard MS, Walker GF. A cephalometric study of the relationship between the malar bones and the maxilla in white american females. Angle Orthod 1977 Jan;47(1):42-5.
20. Zide B, Grayson B, McCarthy JG. Cephalometric analysis for upper and lower midface surgery: Part II. PlastReconstrSurg 1981 Dec;68(6):961-8.
21. Walker GF. A new approach to the analysis of craniofacial morphology and growth. Am J Orthod 1972 Mar;61(3):221-30.
22. Mulliken JB, Godwin SL, Pracharktam N, Altobelli DE. The concept of the sagittal orbital-globe relationship in craniofacial surgery. PlastReconstr Surg. 1996 Apr;97(4):700-6.
23. Pessa JE, Zadoo VP, Yuan C, Ayedelotte JD, Cuellar FJ, Cochran CS, Mutimer KL, Garza JR. Concertina effect and facial aging: nonlinear aspects of youthfulness and skeletal remodelling, and why, perhaps, infants have jowls. PlastReconstrSurg 1999 Feb;103(2):635-44.
24. Doual JM, Ferri J, Laude M. The influence of senescence on craniofacial and cervical morphology in humans. SurgRadiolAnat 1997;19(3):175–83.
25. Baumrind S, Frantz RC. The reliability of head film measurements. 1. Landmark identification. Am J Orthod 1971 Aug;60(2):111-27.
26. Tessier P. The definitive plastic surgical treatment of the severe facial deformities of craniofacial dysostosis: Crouzon's and Apert's diseases. PlastReconstrSurg1971 Nov;48(5):419-42.
27. Garn SM, Rohmann CG, Wagner B, Ascoli W. Continuing bone growth during adult life: a general phenomenon. Am J PhysAnthropol 1967 May;26(3):313-7.
28. Behrents RG. Growth in the aging craniofacial skeleton. Ann Arbor: University of Michigan Center for Human Growth and Development; 1985.
29. Flowers RS. Periorbital aesthetic surgery for men: eyelids and related structures. ClinPlastSurg 1991 Oct;18(4):689-729.