ORIGINAL RESEARCH PAPER

Volume-8 | Issue-5 | May-2019 | PRINT ISSN No 2277 - 8179

INTERNATIONAL JOURNAL OF SCIENTIFIC RESEARCH

VARIATIONS AND BRANCHING PATTERN OF RENAL ARTERY- A PROSPECTIVE OBSERVATIONAL STUDY ON CADAVERS

Anatomy

Dr. Mirza R.U. Beg Associate Professor, Deptt. of Anatomy, GMC, Datia (M.P.)

Dr. Amit Kumar Srivastava* Demonstrator, Deptt. of Anatomy, GMC, Datia (M.P.) *Corresponding Author

ABSTRACT

Introduction: Knowledge of morphology of renal artery, branches and its variations is important in renal transplantation, renal trauma surgery, radiological imaging and surgical treatment of aortic aneurysms.

Objectives: To expose the abdominal aorta and its branches. To describe the variations of renal artery and its branches.

Materials and Methods: In the present study 30 cadavers were studied during routine dissection from Department of Anatomy, Government medical college, Datia. For Dissection followed the Cunningham's manual volume-II.

Results: Out of total 60 renal arteries observed the two variations. Right renal artery gives right testicular artery, another variation on left side abdominal aorta gave accessory renal artery.

Conclusion: Knowledge of arterial supply of kidney is important to urologist, vascular surgeons, nephrologists and radiologist.

KEYWORDS

Renal artery; accessory renal artery; abdominal aorta; testicular artery.

Introduction-

Knowledge of morphology of renal artery, branches and its variations is important in renal transplantation, renal trauma surgery, radiological imaging and surgical treatment of aortic aneurysms. Variations of the branches of renal artery and their relations to surrounding structures are important regarding intra-abdominal surgery.[1] Each kidney is supplied by renal artery which is a branch of abdominal aorta. Occasionally an accessory renal artery arising from the abdominal aorta which supplies upper or lower part of the kidney without passing through the hilum. An accessory renal artery is the precocious origin of segmental artery.[2] As the kidneys ascends from pelvis to lumbar region, they are vascularised by a succession of transient aortic sprouts that arise at higher levels progressively. These arteries do not elongate to follow the ascending kidneys; instead they are degenerated and replaced by successive new arteries. The final pair of arteries forms in the upper lumbar region as the definitive renal arteries. Sometimes, the inferior pair of arteries is not degenerated and becomes an accessory lower pole artery. The origin of intrarenal vasculature has not yet been completely understood. It was postulated that the renal vasculature derived exclusively from the branches of the aorta and other pre-existing extra renal vessels. However, there was evidence that the renal vessels may originate within the embryonic kidney from the vascular progenitor cells. It was also thought that both vasculogenesis and angiogenesis may play a role in the development of renal vasculature.[3] The rationale behind the study was to study the variations of branching pattern of renal artery & abdominal aorta.

Material and Methods-

30 human cadavers were studied during routine dissection from from Department of Anatomy, Government medical college, Datia

Method- Dissection method

Procedure: As per cunningham's Manual of Practical Anatomy Volume -2, 15" edition (Thorax and Abdomen) the right and left kidneys and the surrounding tissues were removed en bloc with the adjacent part of the aorta cleared and studied.[4,5]

Results-

Dissected 30 cadavers, according Cunningham manual Volume-II. Out of 60 renal arteries. We were observed the two variations. Right renal artery gives right testicular artery, another variation on left side abdominal aorta gave accessory renal artery.

1. Right renal artery close gave right testicular artery. (Fig. 1)
2. The accessory renal artery runs above the main renal artery, it enters the kidney through the hilum on left side. (Fig. 2)

Figure 1- Showing Right renal artery gave right testicular artery on right side



Figure 2- Showing The accessory renal artery arose from Abdominal Aorta

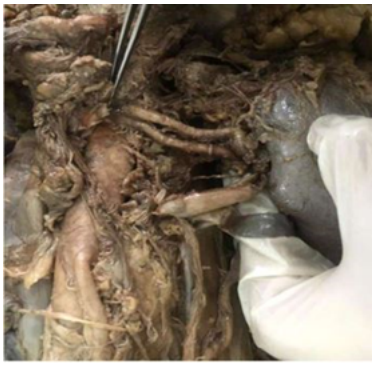

Discussion

In present study renal artery arises from lower margin of L, vertebrae in all specimens. Ugar O et al. concluded that 98% of the patients, main renal artery originated between the upper margin of L, and the lower margin of L, vertebrae. Right main renal artery originated from the lower margin of the L, vertebra in 25%, from the level of the L,-L, intervertebral disc in 23%, and from the upper margin of the L, vertebra in 20% of the patients. On the right side, 77% of ERA originated between the upper margin of L, and the lower margin of L, vertebrae, and 20% originated from the level of the L,-L, intervertebral disc.[6] According to Vanitha Gupta right kidney was supplied by three renal arteries and was drained by two renal veins. The upper renal artery arose at the level just below the superior mesenteric artery (SMA), before going to the kidney it divided into three branches in a looped pattern. The middle renal artery arose just 1 cm below the first. The lower renal artery was seen arising from the aorta just below the origin of inferior mesenteric artery (IMA).[7]

In our study right kidney was supplied two renal arteries one is main

renal artery and another one accessory renal artery both were arose from lateral aspect of abdominal aorta. Jigan A. K et al. concluded Accessory renal artery arose from abdominal aorta it enters the upper pole of the kidney without passing through the hilum in 2 specimens out of 30 renal arteries.[8]

In our study found one accessory renal artery arose from abdominal aorta it enters the kidney through the hilum. Budhiraja V observed single renal artery in 18/42 (42.9%) on right side and 20/42 (47.6%) on left side, originating from abdominal aorta. Multiple renal arteries originating from abdominal aorta were present in 24/42 (57.1%) cases on right side and 22/42 (52.4%) cases on left side, these arteries include double hilar arteries, three hilar arteries (THA), one hilar and one superior polar artery (SPA), one hilar and one Inferior polar artery (IPA).[9]

In this study renal artery gave two variations out of 60 renal arteries. one variation was accessory renal artery arose from abdominal aorta. Syamala et al. found the two renal arteries entering to the right kidney through the hilum. The accessory renal artery is above the renal artery. Left kidney had single renal artery. Normally extra renal arteries runs either above (or) below the main renal artery.[10] In our study findings were like above study. Kumareswaren M et al. studied and concluded that 51% of kidney donors showed variation in the renal artery. Out of 51% variations 38 individuals had accessory renal artery and 13 individuals had early division of renal artery. The distribution of accessory renal artery was equal on both sides (13% on right and left) and 12% of individuals had accessory renal artery on both sides. Out of 13% earlier divisions, 5% was on right side, 7% was on left side and 1% was on both sides.[11]

In our study two variations were observed in out of 30 cadavers. Accessory (hilar) renal artery arises from the ventral part of abdominal aorta on left side and right renal artery gives testicular artery. Cases.C.et.al studied in 86 renal arteries. They established the five types of classification. Type-A Aortic hilar artery, Type-B; hilar upper polar artery, Type-C-aortic upper polar artery, Type. D-aortic lower polar artery, Type-E hilar lower polar artery.[12]

Conclusion- It is important to have the knowledge about the variations of renal arteries which give awareness and help in minimizing the hazards like bleeding or ligation of the artery during various surgical procedures. As the incidence of renal arterial variation is up to 30%. It is better to have the knowledge about the anatomical consideration of renal arteries.

Source of Funding- Nil
Conflict of Interest- None declared

REFERENCES-

1. | Shivarama CH, Bhat Shivarama, Shetty RK et al. multiple variations of branches of abdominal aorta: a case study, nujhs. 2012 June;2(2).
2. Datta AK, Essentials of human anatomy, Thorax and abdomen, current books international, 6'* edition, part-1, page. no. 272.
3. He B, Hamdorf JM. Clinical importance of anatomical variations of renal vasculature during laparoscopic donor nephrectomy. OA Anatomy 2013 Oct 18;1(3):25.
4. Roman's GJ. Cunningham's manual of practical anatomy, oxford medical publications, volime-III, 15* edition, Page. no 118.
5. KhanGM. Manual of examination dissections, 1988.
6. Ugar O, Levent O, Fahri T, Osman K. Renal artery variations angiographic evaluation of 855 consecutive patients, Diagn Interv Radiol. 2006;12:183-86.
7. Vanitha G, Sheetal G, Soumitra G, Bilateral variations in renal vasculature, IJAV. 2010;3:53-55.
8. Jigna KP, A, SSubhash G, Sanjay V. A cadaveric study of variations in renal artery. IJBAR, 2012;3(11).
9. Budhiraja V, Rastogi R, Jain V, Bankwar V, Anatomical variations of renal artery and its clinical correlations a cadaveric study from central india, J.Morph.Sci. 2013;30(4):228-33.
10. Shyamala G, Lalitha. B, Prasad K. N, Morphology and variations of renal artery pattern; A case report. IOSR (JDMS), 2015;14(4):29-31.
11. Kumaresan M, Sankaran P, Kartikeyan G, Variations in Branching Pattern of Renal Artery in Kidney Donors Using CT Angiography, J. Clin.Diagn. Res, J Clin Diagn Res. 2016 Mar;10(3):AC01-AC03.
12. Cases C, Garcia Z, Manzrop. Anatomic variations of the renal arteries: cadaveric, radiological study, review of literature and proposal of a new classification of clinical interest, Ann. Anat. 2017;211:61-68.