Research Paper

Volume : 4 | Issue : 7 | July 2015 • ISSN No 2277 - 8179

Variations in the Origin of Profunda Femoris Artery and its Circumflex Branches

Medical Science

KEYWORDS : Femoral artery, Profunda femoris artery, Medial circumflex femoral artery, Lateral circumflex femoral artery

Mr. Rajeev Mukhia	Lecturer in Anatomy, Manipal College of Medical Sciences, Fulbari, Pokhara, Nepal
Mr. Phanindra Prasad poudel	Assistant professor in Anatomy, Manipal College of Medical Sciences, Fulbari, Pokhara, Nepal

ABSTRACT

The knowledge of the variations in origin and course of the profunda femoris artery andits circumflex branches has clinical importance during diagnostic imaging procedures aswell as during surgeries that are performed in the femoral triangle. We dissected 30 femoraltriangles in 15 human cadavers which revealed interesting variations apart from the usualdescription about these arteries that is available in standard anatomy textbooks. The mostcommon site of origin of profunda femoris artery was from the posterior aspect of thefemoral artery. In the present study the commonest site of origin of medial and lateral circumflex femoral artery was from the medial aspect and lateral aspect of the profunda femoris artery respectively. Hence, the knowledge of anatomical variations of profunda femoris artery origin and course is clinically important for anatomist during routine dissection as well as surgeon during surgeries.

INTRODUCTION

The profunda femoris artery emerges from the posterolateral aspect of the femoral artery in the femoral triangle approximately 4-5 cms below the inguinal ligament. This is the main artery which supplies the adductor, extensor and flexor muscles of the thigh. The branches of profunda femoris artery are medial and lateral circumflex femoral arteries and four perforating arteries.[1] The knowledge of variations in the origin of profunda femoris artery and its branches is significant in preventing flap necrosis, particularly tensor fascia latae, when used in plastic and reconstructive surgery.[2] The knowledge of the site of origin of the profunda helps in avoiding iatrogenic femoral arteriovenous fistula while performing femoral artery puncture and it also enables to identify the correct site of making incision for surgical exposure of the femoral artery and profunda femoris artery junction.[3] The medial circumflex femoral artery is used for selective arteriography to determine the arterial supply of femoral head in idiopathic ischemic necrosis of femoral head.[4] The lateral circumflex femoral artery is important clinically for harvesting of anterolateral thigh flaps, aortopopliteal by-pass, coronary artery grafting, and vascularised iliac transplant.[5] Considering the clinical importance of the profunda femoris, medial circumflex and lateral circumflex arteries, we have taken the study of the variations and dimensions of these vessels.

MATERIALS AND METHODS

A series of 30 femoral triangles in 15 human cadavers irrespective of sex were dissected for the study of variations in the origin of profunda femoris artery, medial & lateral circumflex arteries. The dissection was done according to the "cunningham's manual of practical anatomy".[6] The skin was incised and reflected, followed by the superficial fascia. The superficial inguinal lymph nodes along with the superficial vessels were identified and the fascia lata was incised thus exposing the femoral triangle. The femoral sheath was identified and its compartments were dissected thus clearing the femoral artery and its major branches. The profunda femoris artery with its medial and lateral circumflex femoral branches were dissected and identified, their origin and course were studied. The distance of the site of origin of the profunda from the midpoint of the inguinal ligament was measured in millimetres with a scale and a vernier calliper. The site of origin of the medial and lateral circumflex femoral arteries was studied and the distance of site of origin of each of them from the origin of profunda femoris was measured in millimetres.

OBSERVATIONS AND RESULTS

The site of origin of profunda femoris artery from posterior, posterolateral, lateral and medial aspect are 43.33 %(13cases), 33.33 %(10cases), 20 %(6cases) and 3.33 %(1cases) respectively. The distance of origin of profunda femoris artery from the midpoint of the inguinal ligament in percentage is shown in Table 1. The site of origin of medial and lateral circumflex femoral artery in percentage is shown in Table 2 and Table 3 respectively. The distance of origin of medial and lateral circumflex femoral artery from origin of profunda femoris artery in percentage is shown in Table 4.

DISCUSSION

The most common site of origin of profunda femoris artery is posterior aspect of femoral artery. The profunda femoris artery in the present study originated mostly from the posterior aspect in 13cases (43.33%) and in 10 cases (33.33%) from the posterolateral aspect of the femoral artery. These were similar to the results studied by Samarawickrama MB et al which were 46% and 30% respectively.[7] The normal distance of origin of profunda femoris artery from the midpoint of inguinal ligament is 35 to 40 mm.[2] In the present study this distance was recorded between 41 to 50 mm on right side and between 31 to 50 mm on the left side. This indicates that the origin of the left profunda artery is usually proximal to the origin of the right profunda artery. The average distance of origin was 50mm when both sides were taken together. This distance was more than the average distance of origin reported in the literature by Dixit et al.[3] (47.5mm). In the present study the normal pattern in which the medial circumflex femoral artery arises from the medial aspect of the profunda femoris artery was observed in 66.66% on right side and in 33.33% on the left side. This is in accordance to 67.2% reported by Prakash et al in 2010.[9] The distance of origin of medial circumflex femoral artery from the origin of profunda femoris artery was mostly between 0-10 mm on both the sides. In the present study the commonest site of origin of lateral circumflex femoral artery bilaterally was from the lateral aspect of profunda femoris artery i.e. in 86.66% cases on the right side and in 93.33% cases on the left side which is similar to 92.3% given by Samarawickrama MB et al. In most of the cases of the present study the distance of origin of lateral circumflex femoral artery from the origin of profunda femoris artery was noted between 0 to 20 mm on the right side and 11 to 30mm on the left side. Daksha et al[8] mentioned the distance of origin of lateral circumflex femoral artery from the origin of profunda femoris artery was between 21 to 30 mm.

CONCLUSION- Knowledge of the normal anatomy and variations of the site of origin and course of the profunda femoris artery and its circumflex branches is not only of paramount surgical importance during vascular diagnostic interventional procedures and surgeries but also helps in reducing the chances of intra-operative secondary hemorrhage and post-operative complications. Therefore high-resolution ultrasonic imaging is suggested before surgical procedures in femoral triangle.

ACKNOWLEDGEMENTS - The authors are highly grateful to Dr. BP Powar, Dr. CP Sharma, MS Chachhu Bhattrai, Dr. Sharbada, Dr. Bhima, & Dr Diwakar, for providing the necessary support for carrying out the present study.

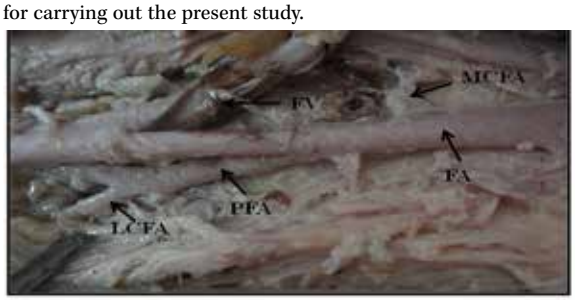

Figure showing profunda femoris artery arising from the posterior aspect of femoral artery. (FV – femoral vein, PFA – profunda femoris artery, FA – femoral artery, LCF – lateral circumflex femoral artery.

Table 1. Distance of origin of profunda femoris artery from the midpoint of the inguinal ligament in percentage

Distance (mm)	Right side		Left side	
	No. of cases	Percentage	No. of cases	Percentage
21-30	3	20%	1	6.66%
31-40	2	13.33%	5	33.33%
41-50	8	53.33%	5	33.33%
51-60	1	6.66%	3	20%
61-70	1	6.66%	1	6.66%

Table 2. Site of origin of medial circumflex femoral artery in percentage.

Site of origin	Right side		Left Side	
	No. of cases	%	No. of cases	%
From profunda femoris artery medial aspect	10	66.66%	5	33.3%
From femoral artery lateral aspect	-	-	1	6.66%
From femoral artery as a common stem with profunda femoris artery	1	6.66%	2	13.33%
From femoral artery proximal to profunda femoris artery	4	26.66%	6	40%
From femoral artery distal to profunda femoris artery	-	-	1	6.66%

Table 3. Site of origin of lateral circumflex femoral artery in percentage.

Site of origin	Right side		Left Side	
	No. of cases	%	No. of cases	%
From profunda femoris artery lateral aspect	13	86.66%	14	93.33%
From femoral artery as a common stem with profunda femoris artery	1	6.66%	-	-
From femoral artery proximal to profunda femoris artery	-	-	1	6.66%
From femoral artery distal to profunda femoris artery	1	6.66%	-	-

Table 4. Distance of origin of medial & lateral circumflex femoral artery from the origin of profunda femoris artery in percentage.

Distance (mms)	Medial circumflex femoral artery				Lateral circumflex femoral artery			
	Right side		Left side		Right side		Left side	
	No. of cases	%	No. of cases	%	No. of cases	%	No. of cases	%
0-10	7	46.66%	8	53.33%	4	26.66%	1	6.66%
11-20	4	26.66%	4	26.66%	5	33.33%	5	33.33%
21-30	2	13.33%	2	13.33%	2	13.33%	7	46.66%
31-40	1	6.66%	1	6.66%	2	13.33%	2	13.33%
41-50	-	-	-	-	1	6.66%	-	-
51-60	1	6.6%	-	-	1	6.66%	-	-

REFERENCE

1. Standring S. Pelvic girdle, Gluteal region and hip joint, Profunda femoris artery. In: Gray's Anatomy, The anatomical basis of clinical practice. 40th ed. | 2. Natale A, Belcastro M, Palleschi A, Baldi I. The mid-distal deep femoral artery: few important centimeters in vascular surgery. Ann Vasc Surg. 2007; 21, p.111-6. | 3. Dixit, D.P., Mehta, L.A., Kothari, M.L. Variation in the origin & course of profunda femoris, Journal of the Anatomical Society of India. (2001-1-2001-6), 50(1). | 4. Valdatta L, Tuinder S, Buoro M, Thione A, Faga A, Putz R. Lateral circumflex femoral arterial system and perforators of the anterolateral thigh flap: an anatomic study. Ann Plast Sur. 2002, 49: 145–150. | 5. DC, Kong JM, Zhong SZ. The ascending branch of the lateral circumflex femoral artery. A new supply for vascularized iliac transplantation. SurgRadiol Anat. 1989, 11: 263–264. | 6. G. J. Romanes. Cunningham's Manual of Practical Anatomy. 15th ed. Oxford Medica Publications. Vol. 1 Upper and Lower limbs. p.140-141. | 7. Samarawickrama MB, BG Nanayakkara,KWR Wimalagunarathna, DG Nishantha, UB Walawage. Branching pattern of the femoral artery at the femoral triangle: a cadaver study.Galle Medical Journal. 2009, Vol 14(1): p.31-34. | 8. Daksha dixit, Dharati M. Kubavat, Sureshbhai P. Rathod, Mital M. Patel, TulsibhaiSingel. A study of variation in the origin of profunda femoris artery & its circumflex branches.Int J Biol Med Res.2011,2(4):p.1084-89. | 9. Prakash, Jyoti K, Bhardwaj AK, Jose BA, Yaday SK, Singh G. Variations in the origins of the profunda femoris, medial and lateral femoral circumflex arteries: a cadaveric study in Indian population. Rom J MorpholEmbryol2010; 51(1): 167-170. |