Volume : 3 | Issue : 5 | May 2014 • ISSN No 2277 - 8179

Research Paper

Vein of Galen Malformation - An untimely and unusual presentation

Medical Science

KEYWORDS : Vein of Galen , CHD, Coarctation, AV malformation.

Dr. Suresh Babu	Professor and Head, Department of Pediatrics, Basaveshwara Medical College & Hospital, Chitradurga. – 577501, India
Dr. Basavanthappa.	Associate Professor, Department of Pediatrics, Basaveshwara Medical College & Hospital, Chitradurga. – 577501, India
Dr. Srinivas. V	Associate Professor, Department of Pediatrics, Basaveshwara Medical College & Hospital, Chitradurga. – 577501, India.
Dr. Raghavendra. K	Associate Professor, Department of Pediatrics, Basaveshwara Medical College & Hospital, Chitradurga. – 577501, India.
Dr. Sreenivas. B	Assistant Professor, Department of Pediatrics, Basaveshwara Medical College & Hospital, Chitradurga. – 577501, India.
Dr. Srinivas Murthy	Assistant Professor, Department of Pediatrics, Basaveshwara Medical College & Hospital, Chitradurga. – 577501, India.
Dr. Rajath Pejaver	Post Graduate Student, Department of Pediatrics, Basaveshwara Medical College & Hospital, Chitradurga. – 577501, India.
Dr. Nikil. P. T	Post Graduate Student, Department of Pediatrics, Basaveshwara Medical College & Hospital, Chitradurga. – 577501, India. Corresponding Author

ABSTRACT

Vein of Galen malformation are rare anomalies of the intracranial circulation. These malformations usually present in the neonatal period with congestive cardiac failure. However we a case of a 11 year old girl with congenital heart disease who was presumptively diagnosed to have cerebral abscess .Further evaluation revealed a large vein of Galen malformation. This case demonstrates the unusual and untimely presentation of a rare disease.

Introduction:

Vein of Galen malformations (VOGMs) are rare anomalies of intracranial circulation that constitute 1% of all intracranial vascular malformations. These lesions are characterized by the presence of an aneurysmally dilated midline deep venous structure, fed by abnormal arteriovenous communications.[1] Galen was first to describe the vein that now bears his name in the second century AD when he characterized the deep venous anatomy of the brain in animals.

Here we present a case of cyanotic congenital heart disease with vein of galen malformation.

Case Report:

A 11 year old girl who is a known case of congenital heart disease(Double outlet right ventriclr+hypoplastic Right ventricle+Atrial septal defect+Ventricular septal defect+ interrupted Inferior vena cava) was admitted in our PICU with complaints right sided focal seizures since 3 months , headache since 15 days , fever since 7 days and altered sensorium since 2 days. Her past history was significant for a left sided hemiperesis 1 year ago and aphasia since 8 years. On examination child was stuperous with tachypnoea and tachycardia. Child was febrile and her blood pressure was 110/56 mmHg. Proptosis of both eyes with conjunctival congestion was noted. Left upper and lower limbs were hypoplastic and the left upper limb was flexed, semipronated and externally rotated. Cardiovascular examination revealed a grade 4 pansystolic murmur heard best in the left lower sternal border. Cerebral Abscess and Cavernous sinus thrombosis were considered as the provisional diagnosis. Child was started on IV Cefotaxim, Ampicillin and Metrinidazole. However CT brain revealed features suggestive arteriovenous malformation with hydrocephalous. The nein galen measured 14 mm.

Other investigations: revealed a total count of 14,500 with a neutrophilia,hemoglobin of 15.6g/dl.Platelet counts and serum electrolytes were with normal limits.



Fig.1:

Volume : 3 | Issue : 5 | May 2014 • ISSN No 2277 - 8179

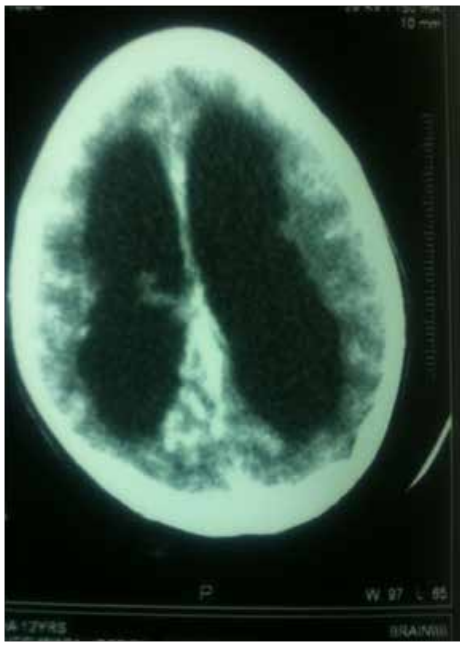

Fig.2:



Fig.3:

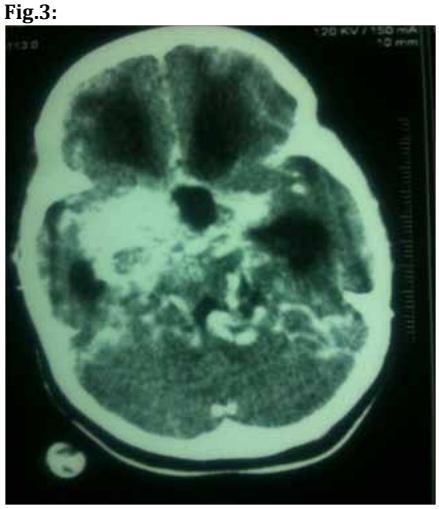

Fig.4:

Fig 1,2,3,4: Shows arteriovenous malformation with hydrocephalus.

Discussion:

Understanding of the VGAM has advanced greatly during the past 2 decades.. Steinheil in 1895, made the first reference to a Galenic malformation-referring to it as a 'varix aneurysm.

It is thought to result from the development of an arteriovenous connection between primitive choroidal vessels and the median prosencephalic vein of Markowski.

By the 11th week (50-mm embryo), the development of the basal ganglia results in the formation of the paired internal cerebral veins, which annex the venous drainage of the choroid plexuses. This results in the regression of the median prosencephalic vein, except for its most caudal part, which joins the internal cerebral veins to form the vein of Galen [3]. Vein of Galen malformations arise as a result of direct arteriovenous communications between the arterial network and the median prosencephalic vein.

There have been several proposed classifications of VGAM, based on complexity, type of supplying arteries, location of fistula, and degree of venous ectasia. One favored classification divides VGAM into choroidal or mural subtypes. The choroidal type is characterized by multiple feeders from the choroidal arteries and other deep midbrain arteries that converge on a fistula site at the anterior aspect of the median vein. Mural lesions, by contrast, are characterized by a fistula or fistulae in the wall of the median prosencephalic vein, often located laterally.

Most of these malformations present in neonatal period or early childhood, often causing congestive heart failure in the neonate. Depending on the size of the shunt, adequacy of venous drainage, complexity of arterial supply and the host response, the cardiac manifestations can range from asymptomatic cardiomegaly to severe cardiac failure that is refractory to medical management. Cyanosis may be seen in these patients and the presentation may be mistaken for congenital cyanotic heart disease.[17] Features of myocardial ischemia may be detected on electrocardiography.[4],[8],[18],[19]

Patients may present with macrocephaly or with hydrocephalus. Patients with longstanding cerebral venous hypertension may also present with delayed milestones. A high proportion of these children present with failure to thrive. Though this could be due to cardiac decompensation, hypothalamic and hypophyseal dysfunction secondary to venous congestion must also be considered as a potential mechanism.[4],[20]

Coarctation of Aorta is commonly associated with VAGM. Decreased forward flow across the aorta in the embryonic period causes the aorta to become hypoplastic . Other CHD's associated with VAGM's are VSD,ASD,PDA.

Any child with coarctation of aorta ideally should be screened for vein of galen malformation. Especially those with convulsion, increasing head circumference.

Interesting in this particular case the child presented at 11 years of life . She also had a double outlet right ventricle with hypoplastic right ventricle, VSD, ASD, interrupted IVC. This combination of CHD and the age of presentation make this case unique.

The treatment of choice is endovascular embolization to occlude the arterial feeders. Embolization during the first few weeks of life is unlikely to result in good outcomes and endovascular treatment should be delayed, if possible, for several months. MR imaging and MR angiography have proved invaluable for the pretreatment analysis of these lesions and are the best imaging tools for the follow-up of incompletely eliminated lesions. Pushable fibered coils are appropriate embolic agents to use in most cases, providing a good combination of control and permanence. There may be a role for the use of radiation therapy in cases in which rapidity of treatment is not essential.

Ventricular drainage for treatment of hydrocephalus should be avoided until all embolization procedures are complete.

Contributors: All authors contributed to the management of the case and drafting of the paper.

REFERENCE

1. | Casasco A, Lylyk P, Hodes JE, Kohan G, Aymard A, Merland JJ. Percutaneous transvenous catheterization and embolization of vein of Galen aneurysms. Neurosurgery 1991;28:260-6. | 2. | Ciricillo SF, Edwards MS, Schmidt KG, Hieshima GB, Silverman NH, Higashida RT, et al. Interventional neuroradiological management of vein of Galen malformations in the neonate. Neurosurgery 1990;27:22-8. | 3. | Raybaud CA, Strother CM, Hald JK. Aneurysms of the vein of Galen: embryonic considerations and anatomical features relating to the pathogenesis of the malformation. Neuroradiology 1989;31:109-28. | 4. | Berenstein A, Lasjaunias P. Arteriovenous fistulas of the brain. In: Surgical Neuroangiography 4. Endovascular treatment of cerebral lesions. Berlin: Springer-Verlag; 1992. pp. 267-317. | 5. | Yasargil MG. Microneurosurgery IIIB. New York: Thieme Medical Publishers; 1988. pp. 323-57. | 6. | Garcia-Monaco R, Lasjaunias P, Berenstein A. Therapeutic management of vein of Galen aneurysmal malformations. In: Vinuela F, Halbach VV, Dion JE, editor. Interventional Neuroradiology: Endovascular therapy of the central nervous system. New York: Raven Press; 1992. pp. 113-27. | 7. | Lasjaunias P, Terbrugge K, Piske R, Lopez Ibor L, Manelfe C. Vein of Galen dilatation: Anatomo-clinical forms and endovascular treatment. Fourteen cases explored and / or treated between 1983 and 1986. Neurochirugie 1987;33:315-33. | 8. | Hoffman HJ. Malformations of the Vein of Galen. In: Edwards MSB, Hoffmann HJ, eds. Current Neurosurgical Practice: Cerebral vascular disease in children and adolescents. Baltimore: Williams and Wilkins; 1989. pp. 239-46. | 9. | Crawford JM, Rossitch E Jr, Oakes WJ, Alexander E 3rd. Arteriovenous malformation of the great vein of Galen associated with patent ductus arteriosus. Childs Nerv Syst 1990;6:18-22. | 10. | Pellegrino PA, Milanesi O, Saia OS, Carollo C. Congestive heart failure secondary to cerebral arterio-venous fistula. Childs Nerv Syst 1987;3:141-4. | 11. | Bhattacharya JJ, Thammaroj J. Vein of Galen Malformations. J Neurol Neurosurg Psychiatr 2003;74:142-4 | 12. | Zerah M, Garcia-Monaco, Rodesh G, Terbrugge K, Tardieu M, de Victor D, et al. Hydrodynamics in vein of Galen malformations. Childs Nerv Syst 1992;8:111-7. | 13. | Sainte-Rose C, La Combe J, Pierre-Kahn A, Renier D, Hirsch JF. Intracranial venous sinus hypertension: Cause or consequence of hydrocephalus in infants? J Neurosurg 1984;60:727-36. | 14. | Lasjaunias P, Garcia-Monaco R, Rodesch G, Ter Brugge K, Zerah M, Tardieu M, et al. Vein of Galen malformation: Endovascular management of 43 cases. Childs Nerv Syst 1991;7:360-7. | 15. | Gulati S, Kalra V. An Uncommon Variety of Vein of Galen Malformation. Indian Pediatr 2002;39:307-8. | 16. | Gold AP, Ransohoff JR, Carter S. Vein of Galen malformation. Acta Neurol Scand 1964;40:5-7. | 17. | Kothari SS, Naik N, Juneja R, Saxena A. Aneurysm of Vein of Galen in the neonates: Report of four cases. Indian Heart J 2001;53:499-502. | 18. | Cumming GR. Circulation in neonates with intracranial arteriovenous fistula and cardiac failure. Am J Cardiol 1980;45:1019-24. | 19. | Garcia-Monaco R, de Victor D, Mann C, Hannedouche A, Terbrugge K, Lasjaunias P. Congestive cardiac manifestations from cerebrocranial arteriovenous shunts: Endovascular management in 30 children. Childs Nerv Syst 1991;7:48-52. | 20. | Lasjaunias P, Terbrugge K, Lopez Ibor L, Chiu M, Flodmark O, Chuang S, et al. The role of dural venous anomalies in vein of Galen aneurysms: report of six cases and review of the literature. AJNR Am J Neuroradiol 1987;8:185-92. |