ORIGINAL RESEARCH PAPER
Volume-6 | Issue-11 | November-2017 | ISSN No 2277 - 8179 | IF : 4.176 | IC Value : 78.46
INTERNATIONAL JOURNAL OF SCIENTIFIC RESEARCH

VITAL PULP THERAPY IN PERMANENT MATURE TEETH WITH BIOACTIVE MATERIAL-BIODENTINE

Dental Science

A P Tikku BDS,MDS Head of the Department and Professor, Department of Conservative Dentistry & Endodontics Faculty of Dental Sciences, King George's Medical University, Lucknow, India

Afsana Ansari* BDS junior resident JR III, Department of Conservative Dentistry & Endodontics Faculty of Dental Sciences, King George's Medical University, Lucknow, India *Corresponding author

Promila Verma BDS,MDS Professor, Department of Conservative Dentistry & Endodontics Faculty of Dental Sciences, King George's Medical University, Lucknow, India

ABSTRACT

Vital pulp therapy is the group of procedures mainly performed on vital permanent teeth affected by caries or trauma to maintain the normal pulp health. It can be performed on both young permanent immature teeth as well as mature teeth with close apices. Vital pulp therapy includes pulp capping (direct or indirect) and pulpotomy (partial or full). Choosing the right material is important, but other factors play a critical role in the success of vital pulp therapy. In this case report, Biodentine was used in the treatment of direct pulp capping and in partial pulpotomy.

KEYWORDS

Biodentine; Direct Pulp Capping; pulpotomy

INTRODUCTION

Today in the fields of endodontics, pediatric dentistry, and dental traumatology there is a new treatment Strategy to preserve and protect the dental pulp with specific bioactive materials[1]. Direct pulp capping is a procedure where a medicated protective dressing is placed directly over the exposed pulp tissue[2]. Pulpotomy is the procedure that consists of surgical amputation of coronal pulp tissue which damage and inflamed due to caries exposure or trauma. Depending upon the level of removal of tissues from the pulp it may be either a partial or full pulpotomy[3].Traditionally $Ca(OH)_2$ has been used for direct pulp caps and pulpotomy from many years[4]. Recently MTA has replaced $Ca(OH)_2$ due to its ability to form an apatite-like layer, its biocompatibility and its lack of cytotoxicity[5]. MTA due to its, biocompatibility and its ability to form cementum attachment has not only been used as a root-end filling material but also has been used as in pulpotomy, apexification, direct pulp capping and as a perforation repair material[6] but has some drawbacks like handling property, high cost, long setting time and discoloration[7]. Now a magical capsule Biodentine, a bioactive material for vital pulp therapy to overcome the limitations of M TA. Now a magical capsule Biodentine ,a bioactive material for vital pulp therapy to overcomes the limitation of M TA.

The following case report illustrates the use of Biodentine in direct pulp capping and pulpotomy by radiographic evaluation.

Case-1 Direct pulp capping

A 24-year-old patient with chief complains of a deep carious lesion in the right lower back region of the mandibular molar. There was no past history of pain, and the tooth pulp tested vital to EPT, coldtest with CO_2 snow was positive and negative on percussion. There was no radiographic evidence of periapical pathology (fig-1). On extraoral examination, there was no swelling and tenderness with respect 46. On clinical examination, there was a deep carious lesion involving the proximal surface. Based on the clinical, radiographic, and vitality examinations, the diagnosis was established as reversible pulpitis. After informing the patient with the procedure, an anesthetic was performed and a rubber dam was applied following cavity preparation, the carious dentin was completely excavated with small spoon excavator or with the help of small round bur. In the process, the pulp cavity was exposed iatrogenically in one site > 1 mm NaOC[l] (2.5%) was used to control the bleeding with damp cotton.BiodentineTM (Septodont Ltd., Saint Maur des Fausse´s, France) is available as a powder in capsule and liquid in ppt. The capsule was then mixed for 30- second automatic mixer (triturator). Thick paste was applied on the cavity as 2mm of thickness after initial setting cavity was filled with permanent restoration with composite at the same visit (fig-2). At the follow-up visit after 7 days, the patient has reported some increased cold and warm sensitivity of the tooth, but no other subjective symptoms. The pulp tests were all positive. At 1 month follow-up, the symptoms had completely disappeared. At 3 and 6 months follow up patient was asymptomatic with no radiographic change and clinically normal and again tested positive for sensitivity and negative on percussion(fig-3).

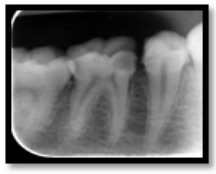

Preoperative x-ray (fig-1)

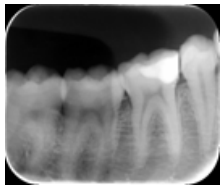

Immediate post operative x-ray (fig-2)



1,3 and 6 month follow up(fig-3)

Case 2 Pulpotomy

A 26-year old male patient reported with the chief complaint of pain in left back tooth region since 1 week. On clinical examination, there was the presence of a large deep carious lesion involving the left mandibular first permanent molar. The patient had a history of mild to moderate pain on the intake of hot and cold fluids. There was no history of swelling or medications. There was no tenderness on percussion and no associated sinus opening adjacent to the involved teeth. Electric pulp testing (EPT) results showed a more intense response in 36 compared to the healthy 46. On radiographic examination radiolucency in the coronal portion of the involved tooth approaching the pulp with normal periodontal ligament space without periapical radiolucency(fig-1). After complete clinical and radiographic examination, a diagnosis of irreversible pulpitis was made in the involved tooth. The patient was treated with complete coronal

pulpotomy with the placement of BiodentineTM (Septodont Ltd., Saint Maur des Fausse´s, France) in the pulp chamber and permanent restoration with composite. An anesthetic was performed and a rubber dam was applied following cavity preparation, The coronal pulpal tissue was then removed with the help of sharp spoon excavator. Bleeding was arrested with the help of cotton soaked NaOCl (2.5%) for 5 minutes. A 2mm layer of freshly mixed Biodentine was placed in the pulp chamber and a permanent restoration was given (fig-2). The patient was recalled after 7 days for evaluation of post-operative pain and swelling. Pain or tenderness to percussion and radiographic examination was done to check at 1, 3 and 6 months with no periapical changes as periodontal ligament space widening (fig-3).

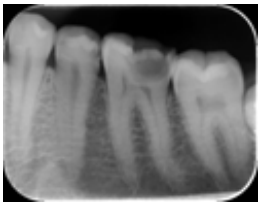

Preoprative x-ray (Fig-1)



Immediate post operative x-ray (Fig-2)

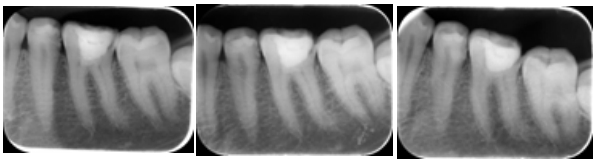

1,3 and 6 month follow up(Fig-3)

DISCUSSION

The aim of vital pulp therapy to preserve and maintain the vitality of teeth and further facilitate reparative dentine formation[8]. Preservation of vital pulp provides protective resistance of masticatory forces of posterior teeth as compared to root canal treated teeth[9]. The healing of the dental pulp may be associated with the placement of an immediate full coronal restoration on the tooth this may reduce the chances of microleakage and bacterial invasion. Massler et al most of the failures in vital pulp therapy and root canal treatment are due to microleakage[10]. Pulpotomy and direct pulp capping can be carried out with various materials based on their sealing ability, biocompatibility, and antimicrobial efficacy. Bioactive materials such as Mineral Trioxide Aggregate (MTA) and Biodentine, Calcium-Enriched Mixture (CEM) have excellent biocompatibility and sealing abilities with the added advantage of inducing proliferation of the pulpal cells11. Limitations of MTA as difficulty in manipulation, longer setting time, discoloration have been noticed[8]. In comparison to MTA, Biodentine provides better sealing ability with a reduced setting time (10-12 minute). Another major advantage of Biodentine is cost-effective over MTA. Biodentine, when placed in direct contact with the dental pulp tissue induces angiogenesis, cell differentiation and mineralization due to TGF- ß1 secretion from the pulp cells[12].The clinical trial evaluating the performance of Biodentine has been used successfully as a permanent restorative material for direct pulp capping and pulpotomy up to 6 months of follow up[13]. Recently authors suggest that vital pulp therapy have a high chance to return to healthy and functional conditions with new bioactive material biodentine[14].

Conclusion

In accordance with the favorable results of cases use of Biodentine seems to be better choices for vital pulp therapy. .However, Case selection, patient age, a status of pulp remains an important factor for long-term success and more clinical studies are required with longer follow-up periods

REFERENCES

1. S. Rajasekharan, LCMartens, R Cauwels, R erbeeck. BiodentineTM material characteristics and clinical applications: a review of the literature. Eur Arch Paediatr Dent 2014;15(3):147-58.
2. Witherspoon DE, Small JC, Harris GZ. Mineral trioxide aggregate pulpotomies: a case series outcomes assessment. J Am Dent Assoc. 2006; 37:610-8.
3. Cvek M. A clinical report on partial pulpotomy and capping with calcium hydroxide in permanent incisors with complicated crown fractures. J Endod.1978;4:232-7
4. C F Cox, et al. "Tunnel defects in dentin bridges: their formation following direct pulp capping". Operative Dentistry 1996;21: 4-11.
5. Whitherspoon D. Vital Pulp Therapy with New Materials: New Directions and Treatment Perspectives—Permanent Teeth. J Endod 2008;30:3,25-28.
6. Parirokh M, Torabinejad M. Mineral Trioxide Aggregate: A Comprehensive Literature Review—Part I: Chemical, Physical, and Antibacterial Properties. J Endod 2010;36:16-27
7. De Souza Costa CA, Duarte PT, de Souza PP, Giro EM, Hebling J. Cytotoxic effects and pulpal response caused by a mineral trioxide aggregate formulation and calcium hydroxide. Am J Dent 2008;21:255–61
8. Torabinejad M, Chivian N. Clinical applications of mineral trioxide aggregate. J Endod. 1999;25(3):197-205.
9 Jamileh G, Maryam F, Iman Parisayb New Approaches in Vital Pulp Therapy in Permanent Teeth. Iran Endod J. 2014:9(1): 15–22.
10. Massler M. Preserving the exposed pulp. J Pedodontics. 1978;2:217–27.
11. Han L, Okiji T. Bioactivity evaluation of three calcium silicate-based endodontic materials. Int Endodon J. 2013;46(3):808–14.
12. Laurent P,Camps J,DeMeo M,et al.Induction of specific cell responses toaCa3SiO5-based posterior restorative material. Dent Mater 2008;24:1486–94.
13 . Koubi G, Colon P, Franquin JC, et al. Clinical evaluation of the performance and safety of a new dentine substitute, Biodentine, in the restoration of posterior teeth: a prospective study. Clin Oral Investig 2013;17:243–9.
14. Anne Raskin., et al. "In vitro microleakage of Biodentine as a dentin substitute compared to Fuji II LC in cervical lining restorations".Journal of Adhesive Dentistry 2012;14(6): 535-542.