ORIGINAL RESEARCH PAPER

Volume-7 | Issue-1 | January-2018 | PRINT ISSN No 2277 - 8179

INTERNATIONAL JOURNAL OF SCIENTIFIC RESEARCH

VITAMIN A DEFICIENCY (VAD) IN PEDIATRIC AGE GROUP: OPHTHALMOLOGICAL VEIW

Ophthalmology

Dr. Jitendra Kumar Associate Professor & Head, Department Of Ophthalmology, Maharani Laxmi Bai Medical College, Jhansi, UP, India.

Dr.Vijay Pratap Singh* Junior Resident, Department Of Ophthalmology, Maharani Laxmi Bai Medical College, Jhansi, UP, India. *Corresponding Author

ABSTRACT

Purpose: The aim of study A).To evaluates the various ocular effect of vita-A deficiency. B).Various factor which increases the VAD susceptibility.
Method: A total of 75 Patients who were diagnosed as a case of vita-A deficiency (any sign or symptoms of VAD), were included in this cross-sectional study. An assessment of present complaints, detailed clinical history, BMI was recorded. Ophthalmological check up as external examination of the eyes, visual acuity, torch light examination, slit lamp examination, Fluorescein eye staining, Schirmer's test, refraction, direct ophthalmoscopy, was done.
Results: In this study, the male female ratio was 1:1.21. Vita-A deficiency was most commonly observed in children with 5-9 years of age group, who belongs to poor socio-economic, rural and illiterate family background. Incompletely immunized and underweight children were more susceptible to VAD
Conclusion: Vitamin A deficiency remains widely prevalent in the developing world. India is currently at a stage when universal vitamin A supplementation must immediately transit to a targeted supplementation programme

KEYWORDS

BMI, direct ophthalmoscopy, Fluorescein eye staining, Schirmer's test, VAD.

INTRODUCTION

Vitamin A deficiency (VAD) is a nutritional deficiency of high magnitude that can be caused by insufficient intake of vita-min A food sources or by vitamin absorption, transport, or metabolism problems. The importance of adequate vitamin A nutritional status is indisputable, as it has very diverse physiological roles in the visual process, in the integrity of epithelial tissue and immune system, as well as in other metabolic functions[1]. Vitamin A deficiency has been recognized as a public-health issue in developing countries and xerophthalmia due to VAD is the leading cause of preventable childhood blindness which presents as night blindness and Bitot's spots (BS) in early stages followed later by keratomalacia [1]. Children are more prone to VAD due to decreased dietary intake and poor absorption leading to depleted vitamin A (VA) stores in the body. Other contributory factors are a high prevalence of infectious diseases such as measles, diarrhea, and respiratory infections; and economic constraints, sociocultural limitations, and lack of education. Children at preschool age, pregnant women, and nurs-ing mothers are regarded as the classic risk group. However, studies have indicated other possible risk groups for the defi-ciency; among these are children and adolescents. Since it is involved in growth and physical development, vitamin A also becomes essential at this stage.[1,2] VAD specifically affects populations subjected to poorliving conditions, in addition to other factors related tomorbidity conditions that also contribute to serum retinoldepletion. Among them are infections that increase thenecessity or stimulate endogenous losses of this nutrient,and protein-energy malnutrition, which affects the synthesisof retinol binding protein (RBP), thereby decreasing retinolavailability.

Globally, 5.2 million and 190 million preschool-age children have night blindness and low serum retinol concentration (<0.70 µmol/L), respectively [1]. Nearly, 44-50% preschool children in South Asian regions were affected by severe VAD and 85% of these children with xerophthalmia reside in India [1]. In a survey conducted by National Nutrition Monitoring Bureau (NNMB) in eight states, the prevalence of BS in rural preschool children of India was 0.8% indicating its public health significance [4]

The term “xerophthalmia” refers to the spectrum of ocular manifestations due to vitamin A deficiency. Such signs include those involving impaired sensitivity of the retina to light (night blindness), and (in order of their appearance and severity) epithelial disruptions of the cornea and conjunctiva, such as conjunctival xerosis, Bitot spots, corneal xerosis and keratomalacia.[5,6] These ocular symptoms are related to vitamin A deficiency and vary according to the severity of the deficiency, and age. The first symptoms of vitamin A deficiency are characterized by impaired adaptation to the dark, which can begin when serum retinol concentrations fall below 1.0 µmol/L, but occurs more often when they fall below 0.7 µmol/L. Strict xerophthalmia is more frequent and severe at serum retinol concentrations below 0.35 µmol/L.[7,8] Night blindness generally responds rapidly to vitamin A therapy, within 1–2 days [9,10,11], and prompt treatment of xerophthalmia generally results in the full preservation of eyesight up to the stage of corneal xerosis.

Historically, the most characteristic sign of ocular problems related to vitamin A deficiency has been Bitot spots – opaque whitish deposits on the scleral conjunctiva [9]. At this point, conjunctival xerosis is already present, with the conjunctiva appearing dry and dull. Spots of keratinized epithelial cells with the appearance of foam are also present [6, 9]. If vitamin A deficiency continues, corneal xerosis may set in, with the appearance of a hazy cornea, followed by keratomalacia where there is liquefaction of part or the entire cornea [6]. Corneal scars are not considered to be part of active vitamin A deficiency, but are considered a result of a previous bout of the deficiency [6]. With prolonged vitamin A deficiency, there is an increase in morbidity and mortality from common infections, and blindness can occur [12].

Classification of xerophthalmia (ocular signs).

1. Night blindness (XN)
2. Conjunctival xerosis (X1A)
3. Bitot spots (X1B)
4. Corneal xerosis (X2)
5. Corneal ulceration/keratomalacia <⅓ corneal surface (X3A)
6. Corneal ulceration/keratomalacia ≥⅓ corneal surface (X3B)
7. Corneal scar (XS)
8. Xerophthalmic fundus (XF)

MATERIALAND METHOD

A total of 75 Patients who were diagnosed as a case of vita-A deficiency, were included in this cross-sectional study conducted in the Department of Ophthalmology, Maharani Laxmi Bai Medical College, Jhansi, Uttar Pradesh, India over a period of 12 months from Nov. 2016 to Oct. 2017. The procedures followed were in accordance with the ethical standards committee on human experimentation (institutional or regional) and with the Helsinki Declaration of 1975, as revised in

2000. The necessary permission from the Ethical and Research Committee was obtained for the study.

Inclusion criteria:

1. Patients with any sign or symptoms of Vita.-A deficiency with or without affected visual acuity.
2. Both male and female patients were included in the study.
3. The age group of the patients to be studied was between 1 month to 14 years

Exclusion criteria:

1. Patients with Vita.-A deficiency already on medications, were not included in the study.
2. Patients above the 14 years of age were excluded from the study.
3. Patients, who had previous history of any ocular surgery, were excluded from the study.
4. Patients with history of corneal ulcer, trauma, and other ocular pathology, were excluded from the study.

An assessment of present complaints, detailed clinical history (present and past), and history of any ocular surgery, Age, sex, occupation, socio-economic status, immunization status, antenatal, intranatal, postnatal history and BMI were recorded. Ophthalmological check up as external examination of the eyes, visual acuity, torch light examination, slit lamp examination, Fluorescein eye staining, Schirmer's test, refraction, direct ophthalmoscopy, was done.

RESULT

A total of 75 Patients which was diagnosed as a case of Vita-A deficiency, were included in this cross-sectional study.

Table 3.1 Gender ratio of patients with corneal opacity (n=75)

	Male	Female
No. of patients	34	41
Percentage (%)	45.33	54.67

Table 3.2 Age and sex wise distribution of patients (n=75)

Age groups (in years)	No. of patients	Percentage (%)
0-4	13	17.33 (%)
5-9	48	64.00 (%)
10-14	14	18.67 (%)
Total	**75**	**100 (%)**

Table 3.3 BMI distribution of patients (n=75)

BMI	No. of patients	Percentage (%)
Less than 18.5	41	54.67 (%)
18.5 to 24.9	28	37.33 (%)
More than 25	05	6.67 (%)
Total	75	100 (%)

Table 3.4: Immunization status of patients (n=75)

Immunization status (Including MMR vaccine & Vita-A suppl.)	No. of patients	Percentage (%)
Fully immunised	13	17.33 (%)
Not completely immunized	62	82.67 (%)
Total	75	100 (%)

Table 3.5: Family Socioeconomic status of patients (n=75)

Revised Kuppuswamy's Socioeconomic Status	Number of patients	Percentage (%)
Upper class	03	4 %
Upper middle class	07	9.33 %
Lower middle class	13	17.33%
Upper lower class	15	20 %
Lower class	37	49.33 %
Total	**75**	**100%**

Fig 1- Showing, rate of vita-A deficiency in literate and illiterate family (n=75)

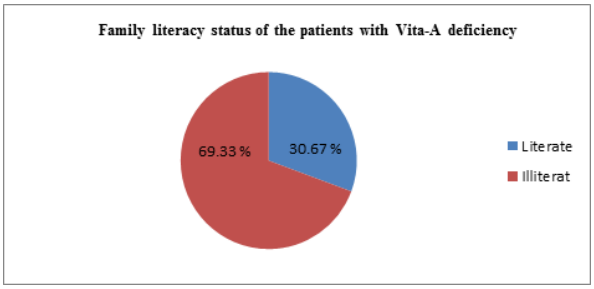

Fig-2: Vita-A deficiency in rural and urban children (n=75)

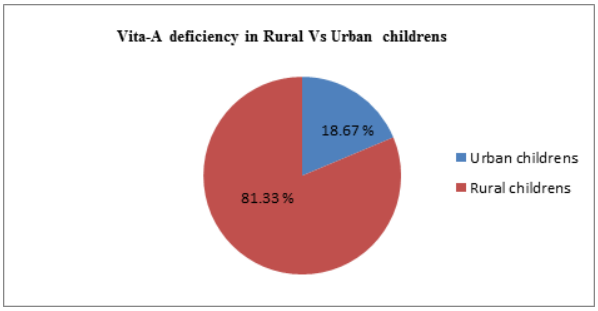

Table 3.6: Patients presented with xerophthalmic ocular sign and symptoms

Xerophthalmia by ocular signs.	No. of patients	Percentage (%)
1. Night blindness (XN)	07	9.33 %
2. Conjunctival xerosis (X1A)	59	78.67 %
3. Bitot spots (X1B)	09	12.00 %
4. Corneal xerosis (X2)	15	20.00 %
5. Corneal ulceration/keratomalacia <⅓ corneal surface (X3A)	07	9.33%
6. Corneal ulceration/keratomalacia ≥⅓ corneal surface (X3B)	03	4.00 %
7. Corneal scar (XS)	03	4.00 %
8. Xerophthalmic fundus (XF)	00	0 %

DISCUSSION

In this study, the male female ratio of vita-A deficiency was 1:1.21, which was most commonly observed in children with 5-9 years of age group (64%), who were belongs to poor socio-economic (almost 70%), rural (81.33%) and illiterate (69.33%) family background. The most common sign of vita-A deficiency was conjunctival xerosis (78.67%) and most common cause of blindness (economical or social blindness) in vita-A deficiency was corneal scar (4%). In this study it was also observed that underweight (54.67%) and incompletely immunized (82.67%) children were more susceptible to vita-A deficiency. Though the prevalence of severe forms of vitamin A deficiency such as corneal ulcers/ Keratomalacia has in general become very rare, the milder forms such as Bitot spots, conjunctival xerosis and night blindness are prevalent in varying magnitudes in different region of the country

CONCLUSION

Vitamin A deficiency can be controlled as a public health problem by maintaining adequate intakes of the nutrient in high-risk groups through direct supplementation, fortification, agronomic programs, marketing, and educational efforts to improve diet. The prevalence of severe vitamin A deficiency is Widespread in children aged 6–9 years in rural areas. vitamin A deficiency in younger children to a level not considered to be of public health significance are encouraging but a challenging task remains in countries where the number of children affected is larger than previously expected. Nutrition education, social

marketing, and other food-based approaches can be equally developed from epidemiologic evidence. Guiding mothers to breast-feed infants through the third year of life rests on a consistent association of protection against xerophthalmia.

Vitamin A deficiency remains widely prevalent in the developing world. India is currently at a stage when universal vitamin A supplementation must immediately transit to a targeted supplementation programme.

REFERENCES

[1]. World Health Organization (WHO). Global prevalence of vita-min A deficiency in populations at risk 1995-2005. WHO Global Database on Vitamin A Deficiency. Geneva: WHO; 2009.
[2]. Ramalho A, Padilha P, Saunders C. Critical analysis of Brazilian studies about vitamin A deficiency in maternal-child group. Rev Paul Pediatr. 2008;26:392---9
[3]. Lee RD, Nieman DC. Nutritional assessment. London: WCBMcGraw Hill; 1993.
[4]. National Nutrition Monitoring Bureau (NNMB). Prevalence of vitamin A deficiency among rural pre-school children. Hyderabad: National Institute of Nutrition: 2006.
[5]. Vitamin A deficiency and xerophthalmia. Report of a joint WHO/USAID meeting. Geneva: World Health Organization; 1976 (WHO Technical Report Series, No. 590
[6]. McLaren DS, Kraemer K, editors. Manual on vitamin A deficiency disorders (VADD), third edition. Basel: Sight and Life Press; 2012
[7]. Natadisastra G, Wittpenn JR, West KP Jr, Muhilal, Sommer A. Impression cytology for detection of vitamin A deficiency. Arch Ophthalmol. 1987;105:1224–8.
[8] Sommer A. Nutritional blindness: xerophthalmia and keratomalacia. New York: Oxford University Press; 1982.
[9]. Spence JC. A clinical study of nutritional xerophthalmia and night-blindness. Arch Dis Child. 1931;6:17–26.
[10]. Sommer A. Vitamin A deficiency and its consequences. A field guide to detection and control, 3rd ed. Geneva: World Health Organization; 1995.
[11]. WHO/UNICEF/IVACG Task Force. Vitamin A supplements. A guide to their use in the treatment and prevention of vitamin A deficiency and xerophthalmia, 2nd ed. Geneva: World Health Organization; 1997.
[12]. Indicators for assessing vitamin A deficiency and their application in monitoring and evaluation intervention programmes. Geneva: World Health Organization; 1996.