Volume : 3 | Issue : 4 | April 2014 • ISSN No 2277 - 8160

Research Paper | Medical Science

A Case of Lipoleiomyoma of Uterus

*** Prashant Gupta**	K. C. Prashant Path. Lab, New Sohna Road, Palwal 121102, Haryana. * Corresponding author
Pawan Kumar Goel	Assiociate Professor, Department of Community Medicine, SHKM Govt Medical College Nalhar (Mewat) Haryana India.
Kulbhushan Bhartiya	K. C. Prashant Path. Lab, New Sohna Road, Palwal 121102, Haryana.

ABSTRACT

A lipoleiomyoma is a rare benign uterine tumour. The reported incidence varies from 0.03% to 0.2%. Around 90% of patients are older than 40yrs of age. Lipoleiomyoma arises from metamorphosis of smooth muscle cells of leiomyoma into adipose tissue.

A 50 yrs old woman presented with mass per abdomen for last 6months. Preoperatively Ultrasound and CT scan diagnosed it as a fatty tumour or adnexal dermoid in pelvic region. Postoperatively, the tumour was bisected and showed a yellowish well circumscribed, encapsulated intramural mass compressing on the endometrial cavity. There are multiple white areas seen. Microsocopy showed adipose tissue mixed with smooth muscle cells.

Hence, lipoleiomyoma should always be considered in a postmenopausal pelvic lump.

KEYWORDS : lipoleiomyoma, uterine tumour, adipose tissue, endometrial cavity

Introduction: Lipoleiomyoma of uterus is rare benign neoplasm with its incidence variously reported as 0.03- 0.2%. (Surase G 2012) it arises primarily in obese perimenopausal and postmenopausal patients. (Manjunatha H 2010) The origin of lipomatous lesions of the uterus have different pathological causes including misplaced embryonic fat cells, metaplasia of muscle or connective tissue cells into fat cells, lipocytic differentiation of a specific primitive connective tissue cell, perivascular fat cells accompanying the blood vessels into the uterus, inclusion of fat cells into the uterine wall during surgery, or fatty infiltration or degeneration of connective tissue. (Alper M 2005) Differentiation of this tumour from other diagnosis such as cystic ovarian teratoma by radiology is important as teratoma is usually excised surgically while lipoleiomyoma doesnot require any treatment.

Case report: A 50 yrs old woman presented with vague pain abdomen along with mass per abdomen for last 6months. She was menopausal for last 2 yrs and she also had increased frequency of micturation. She had no other complaints. Her pelvic ultrasound was done which demonstrated an hyperechoic mass of around 12x11 cm with hypoechoic periphery. CT scan showed heterogenous well demarcated mass of fatty density around 13x11 cm. Adnexal dermoid in pelvic region was suggested and laprotomy was done. Total abdominal hysterectomy with bilateral salphingoophorectomy was done. On gross examination, uterus measures 18cm weighing 1.46 kg . There was a large intramural well circumscribed, encapsulated tumour measuring 16 cm in dia with central pale yellow area having soft consistency on cut section FIGURE-1. The tumour was compressing the endometrial cavity to one side.



tFig 1 Cut surface of uterus showing yellowish adipose tissue with gray white areas in between.

Microscopically the fatty tumour composed of adult adipose tissue divided into lobules by thin connective tissue septae. Inbetween were interspersed single or small clusters of smooth muscle cells without nuclear atypia FIGURE-2,3.. The adipose components were entirely mature without any lipoblasts FIGURE-4.. No necrosis or haemorrhage were seen. Based on these findings, the tumour was diagnosed as a benign lipoleiomyoma.

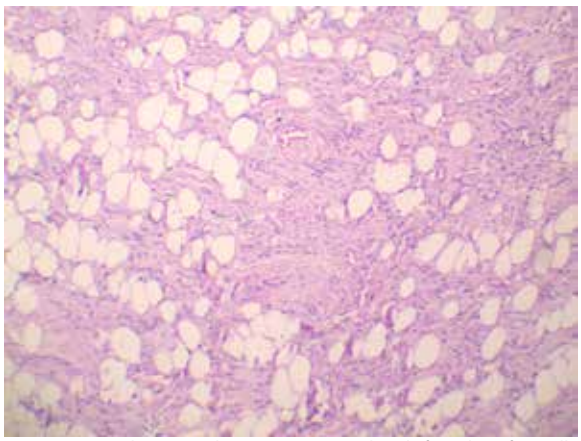

Fig 2: Section showing adipose tissue mixed with fascicles of spindle shaped cells.

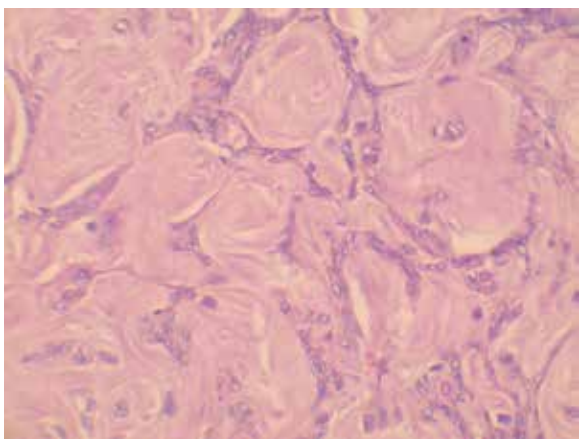

Fig 3: Section showing compression of spindle shaped cells by hyaline change.

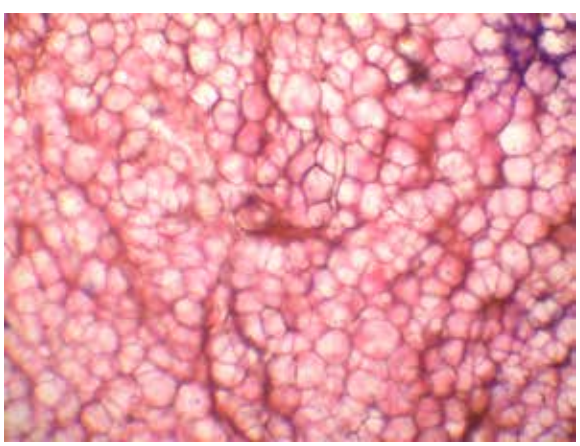

Fig 4: Section showing pure adipose tissue area.

Discussion: Lipoleiomyoma is an unusual fatty tumour of uterus. Myolipoma of soft tissue was firstly described in 1991 by Meis and Enzinger. Since lobstein's first description of lipoleiomyoma in 1816, appx 181 cases have been reported in the literature. (Alper M 20009). Uterine lipoleiomyoma are most frequently found in uterine corpus and are unusually intramural but can be found anywhere in the uterus or cervix and can be subserosal in location. (1) The tumour has been reported to range in size from 3cm to 32 cm in dia and our tumour is around 16 cm. It is well circumscribed encapsulated tumour. It is most frequently located in the posterior wall of uterine corpus whereas our tumour was also located intramurally. (Alper M 20009)

Pathologically, lipomatous tumours of the uterus can be categorized in three groups: pure lipomas, which are encapsulated and composed of mature fat cells, lipoleiomyomas which are mixed tumour containing varying portions of mesodermal tissue such as fat, muscle and connective tissue and the rarest group is the malignant neoplasm which consist of less differentiated fat cells that have undergone sarcomatous change. (Alper M 2009) The pathogenesis of these benign tumour is unknown, with explanations including a tumour arising from misplaced embryonic remains of lipoblasts, perivascular extension of peritoneal or retroperitoneal fat, neometaplasia of lipomatous components derived from immature perivascular cells, lipocytic differentiation of primitive connective or mesenchymal tissue or fatty metamorphosis of smooth muscle cells or connective tissue into adipose cells. (Chan HHL 2003**,** Pounder J Derrick 1982**,** Frankowiak L 2011) This last theory is the most widely accepted mechanism underlying the development of lipoleiomyoma.

The differential diagnosis includes benign cystic teratoma, malignant degeneration of cystic ovarian teratoma, nonteratomatous lipomatous ovarian tumour by pelvic lipoma, liposarcoma, extradermal myelolipoma in a pelvic location, lipoblastic lymphadenopathy and retroperitoneal cystic hamartoma. USG, CT scan and MRI are helpful in diagnosing uterine lipomatous tumour as asymptomatic lipoleiomyoma doesnot require any treatment.

Conclusion: Lipoleiomyoma is a rare benign uterine tumour. Lipoleiomyoma patients are often overweight and menopausal. So, Lipoleiomyoma should always be considered as differential diagnosis in pelvic mass in postmenopausal woman.

Acknowledgment: I am indebted to all my study subjects, who were the basis of this work and who permitted me to let undergo to tremendous task of completing my work successfully.

REFERENCES

1. Alper M, Aksay KA; Lipoleiomyoma of the uterus- Case Report; Malta Medical Journal, 2005, March; Vol 17, issue 01, 40-41. | 2. Chan HHL, Chau MT, Uterine Lipoleiomyoma; Ultrasound and Computed Tomography findings- Case Report: J HK Coll Radiol 2003; 6: 30-32. | 3. Frankowiak L, Shafie D; Lipoleiomyoma of the uterus- A case Report; Pol. Ann Med; 2011; 18(1); 139-145. | 4. Kim HG, Lee DH; A case of LIpoleiomyoma in utero; Case Report, Journal of Women's Medicine, 2009 December; Vol 2 No.4,; 165-167 | 5. Manjunatha H. K, Ramaswamy A. S., Lipoleiomyoma of uterus in a postmenopausal woman, J. Midlife Health, 2010, Jul- Dec; 1 (2). 86-88. | 6. Pounder J Derrick; Fatty tumour of the uterus; J. Clin Pathol 1982; 35: 1380- 1383. | 7. Surase G, Sisodia S, S Redge Rakesh. Lipoleiomyoma of uterus; Bombay Hospital Journal, 2012, vol 54 No. 2, 352-353. |