Volume : 2 | Issue : 12 | Dec 2013 • ISSN No 2277 - 8160

Research Paper | Medical Science

Atypical Intercommunication in the Roots of Median Nerve- a Rare Variation

Singh Bindu	Department of Anatomy, BRD Medical college ,Gorakhpur
Gupta Shalini	Department of Anatomy, BRD Medical college ,Gorakhpur
Mittal Anupama	Department of Anatomy,Subharti Medical College,Meerut

ABSTRACT

Median nerve is normally formed by the union of medial and lateral root arising from the medial and the lateral cords of the brachial plexus respectively. However, variations in the formation and its relation with the axillary artery are not uncommon. Therefore, knowledge of the variations in the nerve formation and course is useful for the clinicians during surgery. During the routine dissection in the department of anatomy, BRD Medical College, Gorakhpur, U.P,India we found unique anatomical variations in the two roots of median nerve forming the neural loops over the third part of axillary artery .

KEYWORDS : Median Nerve, Intercommunication, Axillary artery

INTRODUCTION

The median nerve is a mixed motor and sensory nerve; The nerve is usually formed by two roots, the lateral (C5, 6, 7) and medial (C8, T1) roots arising from the lateral and medial cords of brachial plexus respectively. These roots embrace the third part of the axillary artery, and join together anterior or lateral to the axillary artery to form the median nerve (Standring S,2005)1. The median nerve passes in the arm at first lateral to brachial artery and near the insertion of coracobrachialis, it crosses in front of (rarely behind) the artery, descending medial to it in cubital fossa where it passes posterior to the bicipital aponeurosis and anterior to brachialis. In forearm, it passes between the heads of pronator teres and crosses lateral to the ulnar artery. Median nerve descends after that between flexor digitorum superficialis and flexor digitorum profundus. Near flexor retinaculum the nerve descends lateral to flexor digitorum superficialis, and passes to the palm between the muscle and flexor retinaculum. In arm, the nerve passes without giving out any branches, but in forearm and palm it gives motor branches for the flexors and sensitive branches to the skin of lateral side of the palm. Nerve variations of the upper limb are very important in routine surgery and during radical neck dissections where these variations are more prone to injury(Gacek, RR,1990)[2]. These variations may also help in interpretation of a nervous compression having unexplained clinical symptoms.

MATERIAL AND METHODS

During routine cadaveric dissection in department of anatomy, we noted an unusual pattern of communication in the roots of median nerve over the 3rd part of axillary artery. Median nerve , its branches and its entire course was traced , and appropriate photographs were taken for proper documentation.

CASE REPORT

During routine dissection classes of first year MBBS students of BRD Medical College, Gorakhpur a variant formation of median nerve was observed in the left axilla of a 45-year-old male cadaver. The median nerve was formed by union of two roots, lateral root from lateral cord and medial root from medial cord. But in addition to these two roots there were accessory communications between the lateral and medial roots of median nerve. A common accessory communication trunk arose from lateral root of median nerve at a distance of 5.2 cm from the tip of coracoid process and passed distal and medially superficial to axillary artery to meet the medial root of median nerve. At its junction with the medial root it splits into two branches. Another communicating branch arising from the medial root looping the second part of axillary artery from below passes over the third part of artery laterally towards the lateral root ,its fibres merge with the lateral root opposite the commencement of musculocutaneous nerve. The fibers arising from both the roots made a criss-cross pattern over the third part of axillary artery. [fig1]

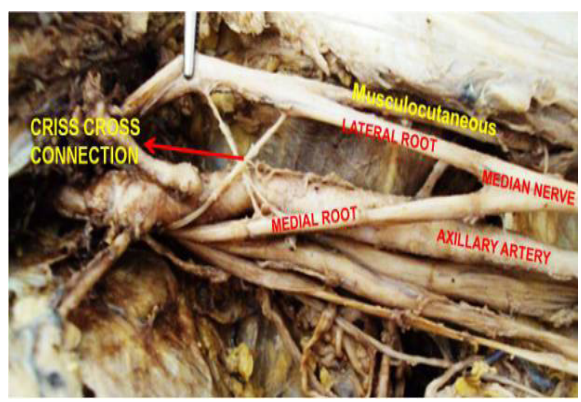

Fig 1:- Showing formation of median nerve and the communication.

DISCUSSION

Variations in the formation of median nerve are known to occur (Chitra R,2007)[3] , (Nene AR et al,2010)[4].

Earlier, Pandey (Pandey SK, 2007)[5] and his group found, an abnormal formation and course of the median nerve in 7% of the cadavers. Goyal and his co-worker found the median nerve to be formed by three roots; the additional root was from the anterior division of the middle trunk (Goyal N et al ,2005)[6]. Sargon et al. reported that the median nerve was formed of three branches. Two branches originated from lateral cord of brachial plexus and one branch originated from the medial cord (Sargon MF et al,1995)[7]. Eglseder and Goldman also found that the median nerve was formed of two lateral roots in 14% of their specimens (Eglseder WA et al,1997)[8]. Uzun et al. found that the median nerve was formed by three branches coming from the lateral cord of brachial plexus and one branch coming from medial cord of brachial plexus (Uzun A et al,2001)[9]. Anrkooli et al., in their case report observed formation of median nerve by fusion of three roots in both the arms of the same cadaver. There were two lateral roots and one medial root (Anrkooli J et al,2007)[10].Different types of variations and communications of median nerve have been reported in the literature by various authors yet there was no case found similar to the case which we have presented above which make this variation among the rare one.

EMBRYOLOGICAL BASIS

Understanding the embryological stages in development of brachial plexus is important for explaining possible anatomical variants. The upper limb bud appears at 26–27 days in the developing embryo and motor axons from the spinal cord enter the limb bud

during the fifth week (. Moore KL,2003)[11]. During histogenesis of peripheral nerves, the normal development of peripheral nerve network depends upon ability of axons to locate and recognize their appropriate target. Developing axons choose specific routes in the embryos during path finding stage followed by growth cones navigating towards their targets. Reacting to some chemical stimulators the axon navigates over long distances to find the correct target (Kaplan S et al,2009)[12]. Axons reach distant targets in a series of discrete steps, making decisions at relatively frequent intervals along the way. The axons take variety of paths to reach their destination. Some grow directly to their termination site; but others make a variety of apparent 'decision mistakes' and then change course or extend new branches. This is because different axons respond differently to a particular chemical molecule. (Jassell TM,2000)[13] . This probably explains why variations do occur in the course of a nerve and also that the nerve fibers ultimately reach their destination. In doing so, they give rise to many such branches which are not seen usually and are regarded as variations.

CONCLUSION

A detailed knowledge of the variations is desired to examine a case appropriately for correct diagnosis and treatment. Variations in formation of median nerve are reported. Knowledge of the variations will be of great help to understand the effects of a lesion if one does occur. It will also be helpful to explain a particular pattern of paralysis in the event of such a nerve being damaged. Also it may explain affection on surrounding blood vessels. Knowledge of such anatomical variations is of interest to the anatomist and clinician alike. Variations assume significance during surgical exploration of the axilla .In our case due to looping of one communicating branch from medial root around the axillary artery may cause compression of the artery as well as may be damaged during surgery in axilla leading to paresis in the respective muscles.

Surgeons who perform procedures involving neoplasm or repairing trauma needs to be aware of these variations.

REFERENCES

1. Standring S: Gray's Anatomy 39th edition. Edinburgh: Elsevier/Churchill | Livingstone; 2005:846-848. | 2. GACEK, RR. Neck dissection injury of a brachial plexus anatomical variant. Archives of Otolaryngology - Head & Neck Surgery, 1990,vol. 116, p. 356-358. PMid:2306357. | | 3. Chitra R. A rare variant formation of the median nerve: a case report. The Internet Journal of Neurology 2007;8 (2). | 4. Nene AR, Gajendra KS, Sarma MVR. Variant formation and course of the median nerve. International Journal of Anatomical Variations 2010;3:93-4. | 5. . Pandey SK, Shukla VK: Anatomical variations of the cords of brachial plexus and the median nerve. Clin Anat 2007, | 20:150-156. | 6. Goyal N, Harjeet , Gupta M: Bilateral variant contribution in the formation of median nerve. Surg Radiol Anat 2005, 8:1-4. | 7. Sargon MF, Uslu SS, Celik HH, Aksit D. A variation of the median nerve at the level of brachial plexus. Bull Assoc Anat (Nancy). 1995; 79: 25–26. | | 8. Eglseder WA Jr, Goldman M. Anatomic variations of the musculocutaneous nerve in the arm. Am J Orthop (Belle Mead NJ). 1997; 26; 777–780. | | [9] Uzun A, Seelig LL Jr. A variation in the formation of the median nerve: communicating branch between the musculocutaneous and median nerves in man. Folia Morphol (Warsz). 2001; 60: 99–101. | | [10] Anrkooli J, Mahmoudian AR, Karimfar MH. A rare bilateral variation in the formation of median nerve. J Iran Anat Sci. 2007; 4: 383–387. | | [11]. Moore KL, Persaud TVN. The developing human: Clinically oriented embryology. 7th Ed., Philadelphia, W.B. Saunders Company. 2003; 410, 458. | | [12]. Kaplan S, Odaci E, Unal B, Sahin B, Fornaro M. Chapter 2: Development of the peripheral nerve. Int Rev Neurobiol. 2009; 87: 9–26. | | [13] Jassell TM, Sanes JR. The guidance of axons to their targets. In: Principles of neural sciences. 4th Ed., Columbia, McGraw-Hill. 2000; 1063–1084. | | Note- Sir kindly send certificate and copy of journal of all the author's to the given corresponding address mentioned in the paper. |