Volume : 2 | Issue : 11 | Nov 2013 • ISSN No 2277 - 8160

Research Paper | Medical Science

Bronchogenic Cyst: clinical presentation in a 3 month old child as congestive heart failure

Gauri Chauhan	Junior Resident, Department of Pediatrics, M.M. Institute of Medical Sciences and Research, Mullana-133-207, Ambala, India
Kshitij Dhuria	Junior Resident, Department of Radiology, M.M. Institute of Medical Sciences and Research, Mullana-133-207, Ambala, India
Dr. Prateek bhatia	Assistant professor, Department of pediatrics, Room no.4104 level 4A, Advanced pediatric centre, Sector 12 PGIMER, Chandigarh 160012
AK Bhardwaj	Professor, Department of Pediatrics, M.M. Institute of Medical Sciences and Research, Mullana-133-207, Ambala, India
PD Sharma	Professor and Head, Department of Pediatrics, M.M. Institute of Medical Sciences and Research, Mullana-133-207, Ambala, India

ABSTRACT

Introduction: Bronchogenic cysts are small, solitary cysts or sinuses, most typically located in the region of the suprasternal notch or over the manubrium sterni. These are found most often in young adults and are rare in infancy. The usual symptoms result from compression by the cyst and include dyspnoea, dysphagia, cough and chest pain. Case brief: Here we present a case of Bronchogenic cyst in a 3 month infant, manifesting clinically as congestive heart failure. The baby presented with excessive crying, sweating on crying and refusal to feed since 15 days. Vitals revealed tachycardia and tachypnoea. On systemic examination a precordial bulge was present and moderate hepatomegaly was noted. A chest X-ray done was suggestive of cardiomegaly. A lateral view on chest X-ray revealed a mass in posterior mediastinum which on CT thorax was confirmed to be a cystic mass causing cardiac compression, consistent with a diagnosis of bronchogenic cyst. The congestive heart failure was managed immediately with fluid restriction, oxygen inhalation, I/v furosemide and digitalization. Case discussion: Bronchogenic cysts in infancy are rare and as in our index case, when they arise in posterior mediastinum, they are known to cause cardio-respiratory compromise. However, an oblique or lateral chest X-ray view is very helpful to pick up the posterior mediastinal mass early. Hence, detailed radiological examination in suspected cases is necessary, to detect cysts timely for early resection or aspiration, so that further complications can be avoided.

KEYWORDS : Bronchogenic cyst, Congestive heart failure, Chest X-ray, Mediastinum

INTRODUCTION

Bronchogenic cysts are small, solitary cysts or sinuses most typically located in the region of the suprasternal notch or over the manubrium sterni. They are the lesions of congenital origin derived from the primitive gut[1]. Complications occur due to compression of adjacent structure, as was noted in our case, wherein the child presented with dyspnoea and tachycardia mimicking congestive heart failure (CHF) with suggestive findings of cardio-respiratory distress with hepatomegaly. Although some bronchogenic cysts are asymptomatic, even these can eventually threaten life by producing compression, infection, hemorrhage and rupture[2].

CASE DETAILS

A 3 month old male infant presented to the Intensive Care Unit of a tertiary care hospital with complaints of excessive crying, sweating on crying and refusal to feed since fifteen days. No specific history of illness since birth was given by the mother. He was a breast fed baby with small amounts of diluted cow's milk also been given along. Deterioration in the condition of the baby was noticed since last few days with mother's main concern being infant's refusal of feed with inconsolable cry and profuse sweating on crying/feeding. The mother even noticed increased heart rate on physical activity. No history of cyanosis or recurrent respiratory infection could be elicited. He was a full term normal vaginal delivery at hospital, cried immediately, with no history of any significant post natal events. No significant family history was present.

Clinical examination at the time of presentation revealed tachycardia with a heart rate (HR) - 152bpm, tachypnoea with a respiratory rate (RR)-76/ min and oxygen saturation by pulse oximeter maintained at 98% on room air. Blood pressure recordings separately in all four limbs showed no significant finding. Pallor was present, however no clubbing or cyanosis was noted. Systemic examination of the cardiovascular system revealed a precordial bulge with asymmetry towards right side, apical impulse in the epigastrium and well audible heart sounds without murmur or added sounds. Abdominal examination revealed hepatomegaly of 5cm below right costal margin. No specific findings in the chest or nervous system were noted. Considering the clinical presentation and examination findings, a provisional diagnosis of CHF was made and child was put on fluid restriction, given injection furosemide, nutrition via feeding tube, oxygen inhalation via mask and started on initial digitalization.

Investigations in form a chest X ray (AP view) revealed cardiomegaly with a suspicion of some mediastinal pathology. However, a chest X ray lateral view revealed a posterior mediastinal mass compressing upon the airway. These findings were confirmed on CECT thorax which showed a large cystic mass in posterior mediastinum measuring 4.6 x 7.5 x 5.2 cm and originating superiorly from the three vessel level and extending inferiorly to the level 4 cm proximal to the gastro-esophageal junction. The cystic mass was noted pushing the mediastinal structures anteriorly and compressing the carina. The child was later referred to a higher centre for oncological/surgical treatment and consultation. The case was hence lost to further follow up.

DISCUSSION

Bronchogenic cysts usually present clinically after the newborn period. They arise as a result of anomalous supermammary budding of the tracheal diverticulum of the ventral gut[3]. Most frequently they are unilocular containing clear fluid, hemorrhagic secretions or air[4]. Trachea-bronchial compression and pulmonary infections occur in children because of relatively soft tracheobronchial tree. Symptoms frequently encountered include cough, fever, pain and dyspnoea. Our index case also presented with tachypnoea with use of accessory muscles and associated sweating, indicating a respiratory compromise. The hepatomegaly could be a normal finding as a result of the thoracic mass shifting to right and downwards and could also be due to a component of CHF. Chest X ray, especially a lateral or oblique view helps in detecting a posteriorly located cyst in the mediastinum, as was noted in our

case. CT scan is needed to detail the size and origin of the cyst and to confirm the diagnosis. Radiologically, the cysts appear as spherical or oval masses with smooth outlines and are usually unilocular and non calcified[5]. Multiple cysts if present can at times cause severe respiratory compromise and may result in death, shortly after birth. Treatment is usually surgical and the prognosis after complete excision is excellent. Incomplete excision is associated with a high recurrence rate. Transtracheal and percutaneous cyst aspiration have been proposed as alternatives to operation, but these methods are not widely accepted because of possible cyst recurrence, which carries a substantial morbidity rate[6].

Fig 1 (a): CECT thorax showing a large cystic mass in posterior mediastinum measuring 4.6 x 7.5 x 5.2 cm
(Case details-3rd para; 6th line)

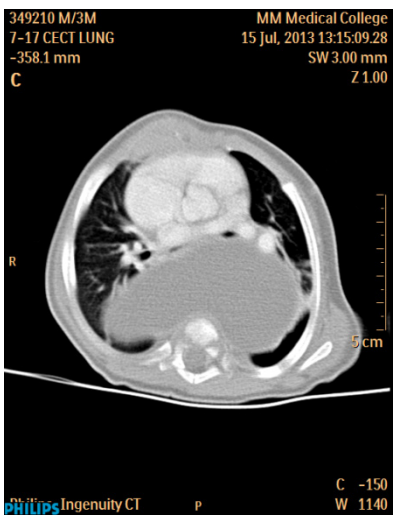

Fig 1 (b): CECT thorax and abdomen view showing the cystic mass originating superiorly from the three vessel level and extending inferiorly to the level 4 cm proximal to the gastro-esophageal junction. The mass is noted pushing the mediastinal structures anteriorly and compressing the carina
(Case details-3rd para; 6th line)

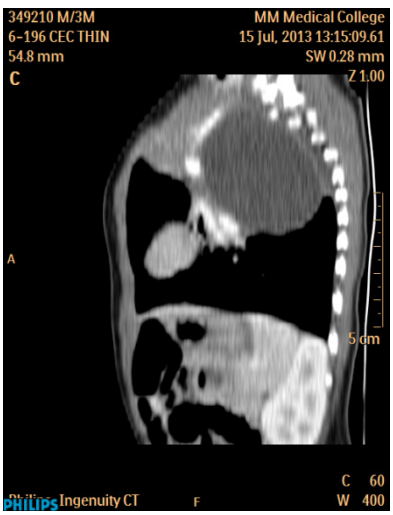

TAKE HOME MESSAGE

1. Bronchogenic cysts can be medically notorious and usually present with cardio respiratory comprise, especially in infants and young children.
2. Detailed radiological examination in suspected cases is necessary, to detect cysts timely for early resection or aspiration, so that further complications can be avoided.

REFERENCES

1. Maier HC. Bronchogenic cysts of the mediastinum. Ann Surg 1948; 127: 476-502. | 2. Sarper A, Aiyten A, Golbasi I, Demircan A and Isin E. Bronchogenic cyst. Texas Heart Inst. J 2003; 30 (2): 105-8. | 3. A K Gupta, V Choudhary, N Khandelwal. Pediatric imaging. Textbook of diagnostic radiology. Section 2, chapter 7; 89. | 4. Rapado F, Benett JD, Stringfellow JM. Bronchogenic cyst: an unusual cause of lump in the neck. J Laryngol Otol 1998; 112: 893-4. | 5. Suen HC, Mathisen DJ, Grillo HC, Leblanc J, Mcloud TC, Moncure AC, Hilgenberg AD. Surgical management and radiological characteristics of bronchogenic cysts. Ann Thorac Surg 1993; 55: 476-81. | 6. De Lorenzo M, Collin PP, Vaillancourt R, Duranceau A. Bronchogenic cysts. J Pediatr Surg 1989; 24: 988-91.