Volume : 3 | Issue : 1 | Jan 2014 • ISSN No 2277 - 8160

Research Paper | Medical Science

Dentigerous Cyst Involving Permanent Maxillary Central Incisor: Role of trauma

Dr. Jitendra V. Kalburge — Professor, Dept. of Oral and Maxillofacial Pathology, Govt. Dental College & Hospital, Jamnagar

Dr. Vaishali Kalburge — Assistant Professor, Dept. of Conservative Dentistry & Endodontics, Siddhapur Dental College & Hospital, Siddhpur

ABSTRACT

A dentigerous cyst is a developmental odontogenic cyst which develops from the reduced enamel epithelium in an impacted tooth. It is a jaw cyst with benign clinical presentation but has potential complications in the form of development of ameloblastoma, squamous cell carcinoma and mucoepidermoid carcinoma from its lining epithelium. This article highlights the clinical presentation, surgical management and histopathological features of a rare case of trauma induced dentigerous cyst involving permanent maxillary central incisor in an eight year old boy.

KEYWORDS : Dentigerous Cyst, Permanent Central Incisor, Trauma, Enucleation

INTRODUCTION

Dentigerous cyst or follicular cyst is defined as an odontogenic cyst surrounding the crown of an impacted or an unerupted tooth. This is one of the most common types of developmental odontogenic cyst, estimated to about 20% of all jaw cysts. It has been found that about 10% of impacted teeth developed dentigerous cyst. The common sites of this cyst are the mandibular and maxillary third molar and maxillary canine areas, since these are the most commonly impacted teeth.[1,2]

Cases of dentigerous cyst affecting maxillary anterior segment are abundant in the literature but very few cases involving a permanent maxillary central incisor are reported.[3,4,5,6] Dentigerous cysts associated with impacted permanent teeth are not uncommon but the cysts which are induced by trauma are uncommon. The objective of this paper is to discuss a rare case of trauma induced dentigerous cyst involving permanent maxillary central incisor.

CASE REPORT

An eight year, male patient reported with extraoral and intraoral swelling in the region of upper anterior teeth since six months. The dental history of the patient revealed history of trauma to anterior teeth approximately one year back and he had visited a dental practitioner because of bleeding in the mouth. Patient had laceration of lips and treatment received in the form of wound cleaning & medications for the same. He was apparently all right since then till he observed the swelling which is present now.

Clinical examination

Extraoral examination revealed a soft to firm diffuse swelling elevating the upper lip and nostril on left side of the midline. The overlying skin appeared normal. The lips had become incompetent. The swelling could be palpable and was slightly tender. The size of the swelling was 3x3cms.

Intraoral examination showed deciduous anterior teeth with grade-I mobility. Swelling could be palpated in the labial vestibule extending from right deciduous maxillary lateral incisor to left permanent first molar. Swelling was also seen over the palatal aspect in the same region. Overlying mucosa appeared normal.

Considering the history, age of the patient and clinical findings, a periapical cyst, dentigerous cyst, ameloblastoma, and adenomatoid odontogenic tumor were considered as differential diagnosis. An intraoral periapical radiograph and orthopentamogram was taken to confirm the clinical diagnosis and to assess the extension of the lesion. Radiographic examination revealed a unilocular radiolucency encircling the crown of impacted tooth, the permanent maxillary central incisor. These features confirmed the diagnosis of dentigerous cyst and the treatment was planned.

Surgical procedure

Under all aseptic conditions and general anesthesia an incision was made in the gingival crevice extending from right deciduous maxillary canine to distal of left permanent maxillary first molar. Mucoperiosteum was reflected and the cystic lesion was exposed. The weakened labial plate was then removed and complete cyst was enucleated along with the impacted tooth. The deciduous teeth on affected side were also extracted as the roots were resorbed and no bone support was left after removal of cyst (Fig.1).

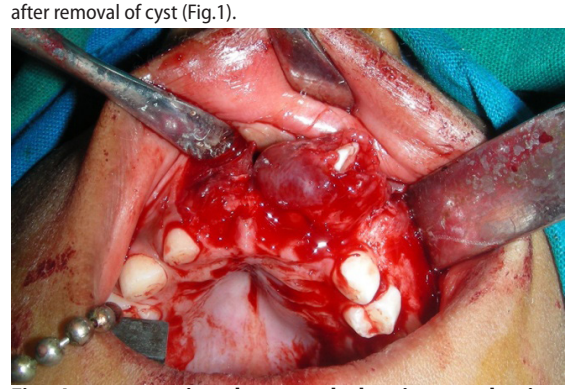

Fig.1 Inter-operative photograph showing enucleation of cyst with involved tooth.

After enucleation of the cyst, the cyst cavity was irrigated with saline and cleaned. Complete closure of the wound was done and the patient was kept on antimicrobials and anti-inflammatory agents for seven days. The tissue was then submitted for histopathologic examination.

Histopathology

Macroscopic examination showed a cyst attached to the neck of permanent maxillary central incisor encircling the crown. (Fig.2)



Fig.2 Macroscopic examination shows a cyst attached to the neck of maxillary central incisor encircling the crown and extracted deciduous teeth.

Complete specimen was subjected for tissue processing and histopathologic examination. Multiple tissue sections were studied to rule out any possibility of neoplastic transformation.

Microscopic examination revealed a thin nonkeratinized stratified squamous epithelium. The epithelium was 3 to 4 cell layer thick without rete ridges. At places the epithelium was separated from the connective tissue. The connective tissue was immature with stellate shaped fibroblasts, delicate collagen fibers and few blood vessels. These features were consistent for dentigerous cyst. (Fig.3)

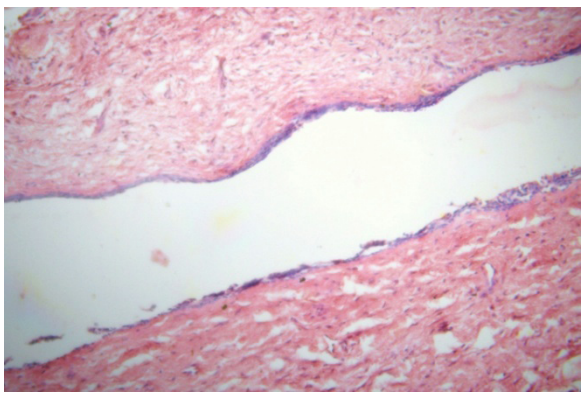

Fig.3 Photomicrograph showing cystic lumen lined by non-keratinized stratified squamous epithelium and supporting connective tissue. (H&E Stain, 20X)

After six months healing was assessed by clinical and radiographic examination of the surgical area. The healing was uneventful and a removable partial denture was constructed. The patient and relatives were explained about future treatment plan i.e. construction of fixed partial denture or implants in the future.

DISCUSSION

Pathology in the form of an odontogenic cyst, an odontogenic tumor or abnormal tooth development can occur at any stage of tooth development. Dentigerous cysts occur after the crown formation is complete. There are two proposed theories for the pathogenesis of dentigerous cysts; extrafollicular theory and intrafollicular theory. The later is widely accepted and states that the dentigerous cyst develops because of fluid accumulation in between the completely formed crown and the layers of reduced enamel epithelium. It has also been suggested that the permanent tooth's crown may erupt in a periapical cyst related to the respective deciduous tooth giving an impression of dentigerous cyst.[2]

The literature findings were true for this clinical entity; the important finding in our case was the involvement of permanent maxillary central incisor by the cyst. Most lesions present in second and third decades of life with slight male predilection. In our case the patient's age was eight years and as there was history of trauma in the anterior region, trauma could be the reason for development of cyst encircling the crown of permanent central incisor. Trauma to deciduous teeth can lead to disturbances in the odontogenesis of the respective permanent teeth. Such disturbances may usually give rise to hypoplastic defects or crown/ root disruption in the permanent teeth, or even deviations from the normal eruption pathway. But development of dentigerous cyst in succedeneous teeth is rarely seen.[5] Thus in our case trauma played an important role in development of cyst. It leads to periapical inflammation of deciduous maxillary incisors and the inflammatory exudates will spread to involve the follicle of unerupted permanent successor, and results in dentigerous cyst formation.[6]

The Dentigerous cyst is potentially capable of becoming an aggressive lesion. The possible complications include extensive bone destruction, resorption of roots of adjacent teeth, displacement of teeth and neoplastic transformation i.e. development of ameloblastoma, squamous cell carcinoma and mucoepidermoid carcinoma. The neoplastic transformation is believed to be because of metaplasia of lining epithelium of the cyst. [1-7] Keeping in mind the chances of neoplastic transformation we did histopathologic evaluation of complete enucleated tissue specimen and found no such change in the cyst epithelial lining.

Selection of proper surgical technique depends on the dimension of the osteolytic region and its relationship with anatomical structures observed radiographically. Enucleation is the technique of choice for small cysts. In the present case, it was possible to enucleate the entire lesion, despite the extensive bone destruction. Complete enucleation was preferred due to the need for complete tissue examination to exclude the possibilities of potential complications. The reported recurrence rate of this cyst is negligible but neoplastic transformation in this cyst can have impact on treatment offered and its outcome.

CONCLUSION

Dentigerous cyst affecting anterior segment of the jaws have great psychological impact on patient after its complete removal. Reassurance to the patient and future esthetic concerns has to be dealt successfully. It is also important to have complete histopathological examination of the tissue to avoid potential complications.

REFERENCES

1. Rajendran R, Sivapathasundharam B (Eds). Shafer's textbook of oral pathology, 6th Ed, 2006, Elsevier, pg. 358-62. | 2. Shear M & Speight P. Cysts of the Oral and Maxillofacial Regions, 4th Ed, 2007, Wiley-Blackwell, Pg 59-76 | 3. Desai RS, Vanaki SS, Puranik RS, Tegginamani AS. Dentigerous cyst associated with permanent central incisor: A rare entity J Indian Soc Pedo Prev Dent, March 2005, 49-50 | 4. Naclerio H, Simoes WA, Zindel D, Chilvarquer I, Aparecida TA. Dentigerous cyst associated with an upper permanent central incisor: case report and literature review J Clin Pediatr Dent, 27 (2) 2002 | 5. Sannomiya E.K, Nogueira M Q, Diniz M C et al. Trauma induced dentigerous cyst involving the anterior maxilla J Dent Child 2007;74;161-4 | 6. Kalaskar R R, Tiku A, Damle S.G. Dentigerous cyst of anterior maxillain a young child: A case report. J Indian Soc Pedod Prevent Dent 2007; Dec: 187-190