Volume : 2 | Issue : 12 | Dec 2013 • ISSN No 2277 - 8160

Research Paper | Medical Science

Histological Features of Carotid Kinking

Bianca Voicu	Emergency Institute for Cardiovascular Diseases and Transplantation, University of Medicine and Pharmacy Targu Mures
Anca Sin	Department of Cellular and Molecular Biology, University of Medicine and Pharmacy Targu Mures
Mariana Tilinca	Department of Cellular and Molecular Biology, University of Medicine and Pharmacy Targu Mures

ABSTRACT

Among other vascular systems, the carotid artery represents a special interest for medical professionals involved in diagnosis and management of vascular disease. The present study was undertaken to observe the histological changes of a group of extracranial internal carotid anomalies, specifically kinking. Our observations include 20 patients with internal carotid kinking, admitted, diagnosed and treated in Clinic of Cardiovascular Surgery, Tirgu Mures, Romania, over a period of five years (2009-2013). The macroscopic and microscopic study of the carotid fragments revealed many changes in vessel wall and caliber. The findings of the microscopic aspects of internal carotid kinking are important in clinical practice because this could compel the surgeon to modify the revascularization techniques of carotid artery.

KEYWORDS : internal carotid artery, kinking, atheromatous plaque

Introduction

Among other vascular systems, the carotid artery represents a special interest for medical professionals involved in diagnosis and management of vascular disease. The internal carotid artery usually runs straight in the neck. Morphological variations of its course are often found in ultrasound and angiography studies and are reported in the literature as tortuosity, kinking and coiling [1].

The reports in the literature focus on clinical signs, surgical treatment and postoperative results. The present study was undertaken to observe the histological changes of a group of extracranial internal carotid anomalies, specifically kinking.

Materials and methods

Our observations include 20 patients with internal carotid kinking, admitted, diagnosed and treated in Clinic of Cardiovascular Surgery, Tirgu Mures, Romania, over a period of five years (2009-2013). The mean age of the patient was 65,6 years (range 52-79 years).

The operations were performed under general anesthesia and in all the cases was necessary an intravascular shunt. The purpose was to straighten the course of affected carotid artery and to remove any stenotic or ulcerative plaques when it was present. The most common surgical intervention was segmental resection and then the reconstruction of carotid axis by end-to-end anastomosis or end-to-side, depending the carotid lumen diameter. Some of the patients had an atherosclerotic plaque and it was necessary a concomitent eversional endarterectomy of the carotid artery.

According to the Committee of Ethics and informed consent, we collected biological material from operated patients.

Immediately after the surgery, the resection samples were formalin fixed and paraffin embedded, using the classic histological technique. The circumferential sections obtained from each specimen were stained with Hematoxilyn-Eosin, van Gieson and Masson trichromic stain in order to evaluate histological parameters.

Results

The macroscopic and microscopic study of the carotid fragments revealed many changes in vessel wall and caliber.

First of all, during the surgery, handling the internal carotid artery segment affected by anomaly, it could be observed a thin arterial wall without a muscular consistency.

Macroscopic examination of the inner side of internal carotid fragments obtained from segmental resection, showed an irregular aspect of intimal surface with an atherosclerotic plaque in most of cases.

Histological examination of the internal carotid artery segment with anomaly showed us a significant reduction of elastic fibers and muscular cells substituted by loose connective tissue. (Figure 1)

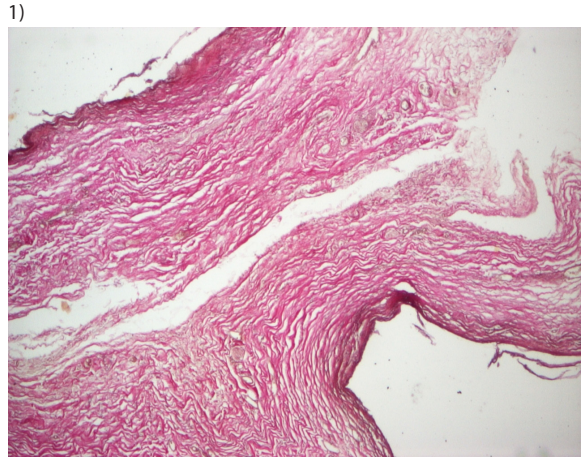

Fig. 1. Carotid artery wall with unorganized elastic fibers and lesion of endothelium (Van Gieson stain, x20).

We found in 75% of patients the presence of atheromatous plaque, involving up to 2/3 of vascular wall. As it can be seen on our images, the atheromatous plaque developed in the arterial intima and consisted of fibers of collagen, hyaline material, foamy cells (represented by macrophages) and cholesterol crystals. (Figure 2)

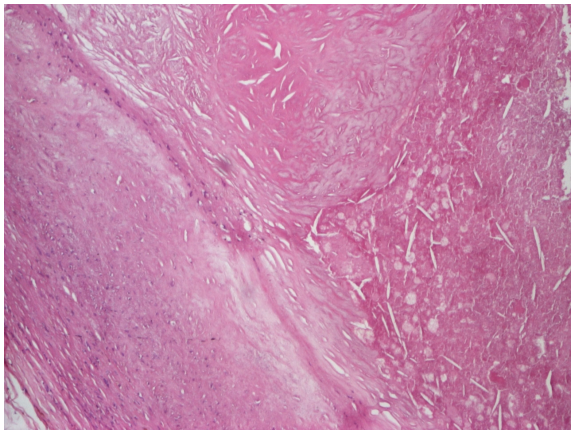

Fig 2. Atheromatous plaque with foam cells, cholesterol crystals and scarcely inflammatory infiltrate (Hematoxilyn-Eosin, x4)

Discution

Internal carotid artery kinking may be the cause of neurological symptoms or may complicate an endarterectomy performed for the treatment of an atherosclerotic carotid stenosis [2].

Kinking is described as an angulation of one or more segments of internal carotid artery associated with stenosis in the affected segment and it can be mild (≥60º), moderate (30º-60º) or severe (<30º), according the angle formed between the two segments of the artery [3,4].

Concerning the origin of the internal carotid kinking, it is belived that this form of arterial anomaly is acquired and most commonly associated with aging, hypertension and traditional risk factors for atherosclerosis [1,4-6].

Only few studies described the histological characteristics of carotid kinking and it's coexistence with atherosclerotic plaque [2,7,8].

The macroscopic and microscopic features of artery with kinking may depend on the adaptation of the arterial wall to the anomaly. In a study performed on ten patients with extracranial internal carotid anomalies, Barbera related that tunica media of the vessels presents areas of loose connective tissue, associated with reduction of elastic fibers and muscular cells like our study [2].

Pauliukas also described gross pathological changes in the arterial wall in the region of loops and kinks like destruction of the smooth muscle and elastic fibrils and fragmentation of the internal elastic membrane.

All this alteration in the structure of the carotid artery wall can lead to trombembolism, dissection or intramural hematoma and can be responsible for hemodynamic impairment at this level [2].

The findings of the microscopic aspects of internal carotid kinking are important in clinical practice because this could compel the surgeon to modify the revascularization techniques by excluding the affected segment and subsequent establishment of an end-to-end anastomosis or replacement of the whole pathologically changed arterial segment by a graft of autologous vein.

Conclusion

Because internal carotid artery kinking is a quite common vascular anomaly, with a great clinical significance, it is important to know histological changes of the affected segment in order to applied the best surgical treatment.

REFERENCES

1. Metz H, Murray-Leslie RM, Bannister RG, Bull JW, Marshall J. Kinking of the internal carotid artery. Lancet 1961, 1(7174):4246. | 2. G. La Barbera, G. La Marca, A. Martino, et al., Kinking, Coiling, and Tortuosity of Extracranial Internal Carotid Artery: Is It the Effect of Metaplasia? Surgical and Radiologic Anatomy, Vol. 28, No. 6, 2006, pp. 573-580. | 3. Desai B, Toole JF. Kinks, coils, and carotids: a review. Stroke 1975; 6(6): 64953. | 4. Radak D, Babic S, Tanaskovic S, et al. Are the carotid kinking and coiling underestimated entities? Vojnosanit Pregl. 2012 Jul, 69(7):616-9. | 5. Del Corso L, Moruzzo D, Conte B, Agelli M, Romanelli AM, Pastine F, et al. Tortuosity, kinking, and coiling of the carotid artery: expression of atherosclerosis or aging? Angiology 1998; 49(5): 36171. | 6. Pancera P, Ribul M, De Marchi S, Arosio E, Lechi A. Prevalence of morphological alterations in cervical vessels: a colour duplex ultrasonographic study in a series of 3300 subjects. Int Angiol 1998; 17(1): 227. | 7. Ballotta E, Abbruzzese E, Thiene G, et al. The elongation of the internal carotid artery: early and long-term results of patients having surgery compared with unoperated controls. Ann Vasc Surg 1997, 11(2):1208. | 8. Schenk P, Temmel A, Trattnig S et al. Curents aspects in diagnosis and therapy of carotid artery kinking. HNO 1996, 44:178-185. | 9. Pauliukas, P.A., Matskevichus, Z.K., Barkauskas, E.M. (1989) Changes in the internal carotid artery in its loop-shaped kinking and their clinical significance. Khirurgiia (Mosk), (9): 47-51. |