Volume : 2 | Issue : 12 | Dec 2013 • ISSN No 2277 - 8160

Research Paper Zoology

Histopathological Alterations occurred Due to Chromium Intoxication in the Tissues of an Indian Common Carp, Labeo rohita (Ham.)

M. Praveena Department of Zoology, Sri Venkateswara University, Tirupati-517502, A. P. INDIA

K. Jayantha Rao Department of Zoology, Sri Venkateswara University, Tirupati-517502, A. P. INDIA

ABSTRACT

Chromium is one of the heavy metals present in the Tannery effluent. Chromium is known to cause various health effects. The present investigation was carried out to study the effect of Chromium on histological alterations in the kidney of a fresh water fish Labeo rohita. The fishes were exposed to sub-lethal concentration (1/10th of LC50/96 hrs) of chromium for 7days and 30 days respectively. Histological changes like Necrosis in Glomerulus, Moderate Necrosis in Bowman's capsule, Necrosis in Collecting Tubule, Degenerative changes in Glomerulus and Necrosis in Haemopoietic tissue were observed in the fishes exposed to chromium in both acute and chronic periods. All these changes were more pronounced in 30 days chromium exposed fish, Labeo rohita.

KEYWORDS : Chromium, Labeo rohita, kidney, Necrosis

INTRODUCTION

Increasing industrialization leads to continuous addition of pollutants in the environment.

Pollution of aquatic environment with metals is common worldwide and under certain conditions aquatic fauna may concentrate large amount of some metals from water in their tissues (Kaoud et al, 2011). Tannery industries produce great amounts of effluents of a different nature, most of them are highly pollutants. Tannery effluent is a major source of aquatic pollution with high chemical and biological oxygen demand. The effects of water pollution are not only devastating to people but also to animals, birds and fish (Gottrfired, 1993). Industrial effluents contain chromium, cadmium, lead, sulphides, ammonia, chlorides and other salts, in addition to a large quantity of organic compounds. The toxic compounds discharged into air, water and soil get into food chain. When toxic substances accumulate in the environment and in food chains, they can greatly disrupt biological processes (Gupta, 1998).

Chromium is one of the heavy metal present in the tannery effluent. It is widely distributed in both terrestrial and aquatic environments. It occurs predominantly in two valences (Cr6+ and Cr3+). Hexavalent chromium compounds are extensively used in diverse industries, whereas trivalent chromium salts, including chromium chloride, niacin bound chromium or chromium polynicotinate, and chromium picolynate, are used as micronutrients and dietary supplements (Bagchi et al., 2002).As with other heavy metals, chromium does not biodegrade but remains in ecosystems. Hexavalent chromium may cause much pathology, being toxic and carcinogenic to animals and humans. Heavy metal contamination of the aquatic environment has drawn increasing attention as it may have devastating effects on the ecological balance of the recipient environment and a diversity of aquatic organisms.

The organisms present in the aquatic environment may accumulate the toxic metals, which ultimately affect not only the productivity and reproductive capabilities of the organisms, but also the health of the human beings that depend on the organisms as a major source of protein. In aquatic animal species, fish are the inhabitants that cannot escape from the detrimental effects of the pollutants (Gottrfired, 1993). Studies carried out on various fish species have revealed that heavy metals may alter the biochemical parameters both in tissues and in the blood (Usha Rani, 2000 and Ashraf, 2000). Histology acts as an integrated parameter, providing a more complete evaluation of the organism's health, effectively mirroring the effects of exposure to environmental pollutants. Histopathological changes have also been widely used as biomarkers in the evaluation of the health of fish exposed to contaminants, both in laboratory and in field studies (Das and Mukherjee, 2000). One of the advantages of using histopathological biomarkers in environmental monitoring is that this category of biomarkers allows examining specific target organs including gills, liver, kidney, brain that are responsible for vital functions, such as respiration, detoxification, excretion and coordination. Hence, the present study aims to investigate the histological alterations of kidney of fresh water fish *Labeo rohita*, exposed to sub lethal concentrations of chromium.*

MATERIALS AND METHODS:

Healthy live specimens of *Labeo rohita* (average length 10±2cms and average weight 15±2gms) were obtained from local ponds and transported to the laboratory treated with 0.05% $KMnO_4$ solution for 2 minutes to avoid dermal infection, kept in large cement tanks and supplied with clean de-chlorinated tap water and were acclimatized for about 2 weeks prior to the experiment with a photoperiod of 12:12 light and dark cycle with constant aeration and filtration. During the period of acclimatization, the fish were fed with commercial fish feed to satiety twice daily. Analytical grade Chromium as Potassium dichromate supplied by BDH (India) was used as a metal toxicant throughout the experiment. Fishes were divided into 3 groups containing 10 fishes each with the I group serving as control without any treatment, the group II, III fish were exposed to sub lethal concentration ($1/10^{th}$ of LC_{50} 96hrs, 10ppm) of Potassium dichromate for 7days and 30 days after determining LC50 value (Finney, 1964). After stipulated time, the animals were sacrificed and the tissues were isolated from each treated and untreated fish, sliced and fixed in fixative solution (containing ethanol, formaldehyde and glacial acetic acid: 1:3:7) followed by dehydration in ethanol, clearing in Cedar wood oil and embedding in Paraffin (Iqbal et al., 2005). Sections of 2 µm were then cut at a microtome and stained with hematoxylin-eosin. Light microscopy was performed and stained section was photographed.

RESULTS

Figure 1

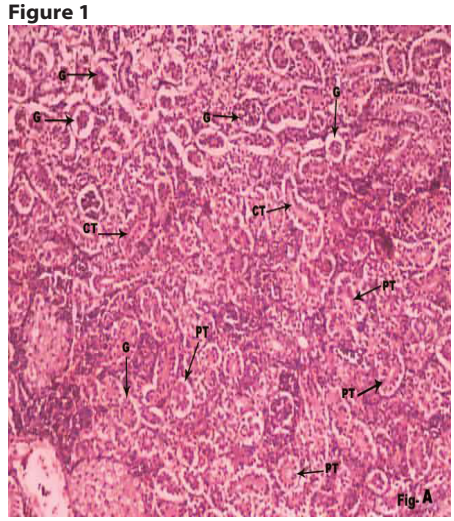

Fig - A – Microphotograph of normal structure of Kidney of Control fish, showing Glomerulus (G), Proximal Tubule (PT), and Convoluted Tubule (CT). (10X).

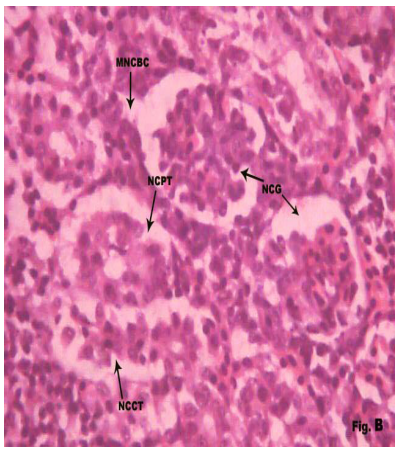

Fig – B – Microphotograph of 7days exposed kidney of fish to chromium showing Necrosis in Glomerulus (NCG), Moderate Necrosis in Bowman's capsule (MNCBC),and Necrosis in Collecting Tubule (NCCT)(45X).

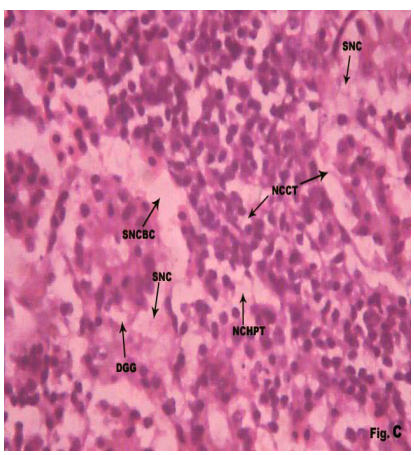

Fig – C – Microphotograph of 30days exposed kidney of fish to chromium showing Severe Necrosis in Bowman's capsule (SNCBC), Degenerative changes in Glomerulus (DGG) and Necrosis in Haemopoietic tissue (NCHPT) (45X).

DISCUSSION

Chromium is an important pollutant from tannery effluent and causes deleterious effects on non-target organisms resulting imbalance of an ecosystem. Heavy metals caused the serious impairments in the metabolic, physiological and structural system which is present in high concentration. The severity of damage depends on the toxic potentiality of a particular compound or toxicant accumulated in the tissue and therefore, exposure to this heavy metal may adversely affect various organs/ systems in fish which ultimately could lead to overall toxic impact on organs like gill, kidney and liver may seriously affect the metabolic as well as physiological activities and could impair the growth and behavior of fish.

Histological studies helps to understand the pathological conditions of the fish. In the present investigation, histological alterations was clearly exhibited in the kidney of the fish, *Labeo rohita* exposed to sub lethal concentration of chromium were represented in figures A to C. The kidney is an organ of excretion. The toxic impurities present in the filtrate will affect the structure of organ itself. The chromium exposure exhibited marked degenerative changes in the histology of kidney tissue in the present investigation. Due to the chromium exposure the kidney tissue was much more damaged in 30 days when compared with 7 days. Many cytoarchitectural changes were observed like shrinkage, destruction of tubular epithelium, Necrosis in glomerulus, Moderate Necrosis in Bowman's capsule, Necrosis in Collecting Tubule, Degenerative changes in Glomerulus and Necrosis in Haemopoietic tissue.

The histological alterations noticed in the present study are in accordance with the chronic exposure to chromium. Iqbal et al.(2004) also reported similar results like degeneration of glomeruli, increase in Bowman's space, shrinkage of proximal tubule cells with pycnotic nuclei, increase tubular lumen and increased in intra-tubular hematopoietic tissue were observed in fish kidney after nitrate exposure. Similar observations were made by Csepai (1978) and Dickman (1998) in *Cyprinus carpio* chronically exposed to the organochlorine and organophosphate compounds include shrinkage, destruction of tubular epithelium, vacuolarization and damage of glomerulus.

The renal corpuscles of the kidney in the present study were scattered resulting in their disorganization and consequently obstruction to their physiological functions. Some of the kidney cells were found Necrotic. The results also agreed with the previous findings (Navaraj and Yasmin (2012), Abdul Latif, (2012) and K. Parvathi et al,.(2011)**.** Similar observations were made by Mohanta et al., (2010) like Shrinkage of Bowman's capsule, vacuolation formed around the capsule and enlargement of tubular lumen and distal and proximal tubules. Our results are corroborated by the similar findings of kidney pathology in Chinook salmon and Gold fish exposed to chromium (Farag, 2006 and Venkatramreddy Velma and Paul B. Tchounwou, 2010). Thus the study proves that the heavy metal chromium caused severe alterations in the histology of kidney of a fresh water fish, *Labeo rohita*. Hence it is concluded that the heavy metal contamination definitely causes certain cytoarchitectural changes in the tissues of the exposed fish.

REFERENCES

1. Kaoud H. A., Zaki M. M., El-Dahshan A. R., Saeid S. and El Zorba H.Y(2011). Amelioration the toxic effects of Cadmium-Exposure in Nile Tilapia (Oreochromis Niloticus) by using Lemna gibba L. Life Science Journal.;8(1):185-195. | 2. Gottrfired, S.S. (1993). Biology Today. Mosby-Year Book inc., p. 22-26. | 3. Gupta P. (1998). Cadmium toxicity and thyroid function with special reference to 5' | monodeiodinase enzyme activity a comperative study in birds and mammal. Ph.D.Thesis. | 4. Bagchi, D., Stohs, S.J., Downs, B.W., Bagchi, M., Preuss, H.G., (2002). Cytotoxicity | and oxidative mechanisms of different forms of chromium. Toxicology, 180, 5–22. | 5. Usha Rani, A.: Cadmium-induced bioaccumulation in the selected tissues of freshwater | Teleost, Oreochromis mossambicus (Tilapia). Ann. N.Y. Acad. Sci., 2000; 919: 318-320. | 6. Ashraf, W.(2006): Levels of selected heavy metals in Tuna fish. Arab.J. Sci. Engineer., | 31: 89-92. | 7. Das BK, Mukherjee SC (2000). A histopathological study of carp (Labeo rohita) exposed | to hexachlorocyclohexane. Veterinarski Arehiv. 70(4):169-180. | 8. Iqbal F, Qureshi IZ, Ali M (2005). Histopathological changes in liver of farmed Cyprinid | fish, Cyprinus carpio, following nitrate exposure. Pak. J. Zool. 37(4): 297-300. | 9. Iqbal, F., Qureshi, I.Z. and Ali, M. (2004). Histopathological changes in the kidney of | common carp, Cyprinus carpio, following nitrate exposure. J. res. Sci., 15 (4): 411-418. | 10. Csepai, F. (1978). Histological detectable dystrophies in the carps kidney exposed to | chronic effect of some pesticides. Magy Allatorv. Lapja., 33: 55-58. | 11. Dickman, M.D., Leung, K.M.(1998): Mercury and organochlorine exposure from fish | Consumption in Hong Kong. Chemosphere, 1998; 37: 991-1015. |