GLOBAL RESEARCH ANALYSIS

ISSN No 2277 - 8160

Listed & Indexed with

ISSN Directory, Paris



Multi-Subject Journal

Volume : 1 | Issue : 2 | July 2012 | ₹ 250/-

GLOBAL RESEARCH ANALYSIS

ISSN No 2277 - 8160

GLOBAL RESEARCH ANALYSIS

Editor In-Chief :

Dr. Khansa Memon
SARA Publishing Academy

Dr. Ashok S. Pawar Associate Professor, Dept. of Economic Dr. Babaasaheb Ambedkar Marathwada.University, Aurngabad.(MS-India)-431004	**Dr.(Prof) Vijay Kumar Soni** Principal, Jai Meenesh College, Phagi, Jaipur, Rajasthan	**Dr. A.R. Saravankumar** Assistant Professor in Education DDE, Alagappa University, Tamilnadu
Dr. R. Ramachandran Commerce DDE Annamalai University Tamilna	**Dr. R Ganpathy** Assistant Professor in Commerce Directorate of Distance Education Alagappa University Karaikudi.	**Dr. Amit Bandyopadhyay** Assistant Professor Department of Physiology University of Calcutta
Dr. V. Kumaravel Professor and Head Vivekanandha Business School for Women Tiruchengode, Namakkal Dist	**Dr. K. Prabhakar** Professor, Department of Management Studies, Velammal Engineering College, Chennai - 600 066.	**Dr. Sunita J. Rathod** Maharashtra Education Service Group-B DIET Dist. Jalna

SUBSCRIPTION DETAILS

Period	Rate	Discount	Amount Payable
One Year (12 issues)	3000/-	Nil	3000/-
Two Years (24 issues)	6000/-	200/-	5800/-
Three Years (36 issues)	9000/-	300/-	8700/-
Five Years (60 issues)	15000/-	600/-	14400/-

You can download the Subscription form from website www.theglobaljournals.com. You will require to print the form. Please fill the form completely and send it to the Editor, GLOBAL RESEARCH ANALYSIS along with the payment in the form of Demand Draft/Cheque at Par drawn in favour of GLOBAL RESEARCH ANALYSIS payable at Ahmedabad.

- Thoughts, language, vision and examples in published research paper are entirely of author of research paper. It is not necessary that both the editor, and editorial board agrees with the author. The responsibility of the matter of research paper/article is entirely of author.
- Editing of the Global Research Analysis is processed without any remittance. The selection and publication is done after recommendations of atleast two subject expert referees.
- In any condition if any National/International University denies accepting the research paper published in GRA, then it is not the responsibility of Editor, Publisher and Management
- Only the first author is entitle to receive the copies of all co-authors
- Before re-use of published paper in any manner, it is compulsory to take written permission from the Editor-GRA unless it will be assumed as disobedience of copyright rules
- All the legal undertaking related to Global Research Analysis is subject to Ahmedabad Jurisdiction.
- The research journal will be send by normal post. If the journal is not received by the author of research paper then it will not be the responsibility of the Editor and publisher. The amount for registered post should be borne by author of the research paper in case of second copy of the journal.

Editor,
GLOBAL RESEARCH ANALYSIS
3, SUHANA, Near. Ruby Apartment, B/h NID, Rajnagar Road, Paldi Ahmedabad – 380007. Gujarat (INDIA)
Cell : +91 98247 02127, 8866 00 3636

INDEX

Sr. No.	Title	Author	Subject	Page No.
1	Application of One Way ANOVA and Tukey's HSD Post Hoc test to Ecological Data	T B Mruthunjay, Dr. Shankar P Hosmani	Biotechnology	1-3
2	"New Area and Management Through Value Based"	Dr. Pankaj. K. Trivedi	Commerce	4-5
3	E-Supply Chain Strategies	Dr. Vipul Chalotra	Commerce	6-7
4	Socio-economic and Cultural factors in health, health services and prevention: An over view	Jaibarath Mageshkar	Economics	8-9
5	A Discriminant Analysis on Demographic Factors and Satisfaction Level of Credit Card Users in Coimbatore City	Dr.Malarvizhi.V	Economics	10-12
6	Effects of Socio-Cultural Determinants on Fertility	Prof. Dr. K.J. Thankachan	Economics	13-15
7	"Need of Effective Communication Model in Teaching Learning Process"	Dr. Mujibul Hasan	Education	16-18
8	Awarness on Special Education for B.Ed Students	Dr. S. K. Panneer Selvam	Education	19-20
9	Quality Improvement in Elementary Teacher Education	Ramesh B. Sakhiya	Education	21-22
10	Mobile operating system: A Case study on Symbian and Android	Vidyasagar S.D.	Engineering	23-25
11	IIR Filter Design to remove noise from ECG signal	Aarti J Patel	Engineering	26-28
12	Assessment of Godavari River Water For Sustainable Utilization.	I. B. Ghorade, S. S. Patil, M.D. Wagh	Environment Science	29-32
13	Shiksha, Saksharta aur Media	Dr Subodh Kumar	Journalism	33-34
14	Television Viewing Behaviour of Rural Women	Dr. H.Ramakrishna	Journalism	35-36
15	Female Foeticide and PNDT Act: Issues and Challenges	Dr. Anu, Dr. Pawan Kumar	Law	37-38
16	Product Invasion from foreign Competitors Whether Indian Product will win this Competition?	Dr. Ashish Singh	Management	39-40
17	"Role of State Wise Employment Exchanges on Condition That Employment In India."	Mr. Vimal P. Jagad	Management	41-43
18	A Study for The Growth of Micro, Small, Medium Service Enterprises Thorugh Tourism Development	Prof. Nikita Gupta, Prof. Parag Gadve, Prof. Farha Hussain	Management	44-45
19	To Study The Need of Capacity Building for Rural Tourism	Prof. Parag Gadve, Prof. Nikita Gupta, Prof. Farha Hussain	Management	46-47
20	CRM and Information Technology	Prof KVSN Jawahar Babu	Management	48-49
21	Strategies for Seizing Rural Markets- A Checklist for Fmcg Firms	Prof KVSN Jawahar Babu, N Meena Rani	Management	50-52
22	Implementation of Adaptive Controller based on FPGA for Flow System	Ankit V Bhaiya, Prof. Vandana V. Patel	Management	53-55
23	"A Study of Evaluation of Operating Performance of Selected Mutual Fund in Global Era"	Mital R Menapara, Bhavesh P Chadamiya	Management	56-57
24	"Remarks on the Measurement, Valuation and Reporting of Intangible Assets"	Dinesh C. Dhoniya	Management	58-59

Sr. No.	Title	Author	Subject	Page No.
25	Corporate Social Responsibility: Micro and Macro level	Parul Jain	Management	60-61
26	Role of Management Schools in Transformation of Rural India	Dr. H.Ramakrishna	Management	62-64
27	A Study on Customer Experience in Modern Retail Stores with Reference to Big Bazaar, Hyderabad	N Meena Rani	Management	65-67
28	Impact of Satellite Television on Adolescent Girls of Silchar Town in Southern Assam	Dr Partha Sarkar	Mass Communication	68-70
29	Quality Assurance Procedure for Computerised Tomography Scanners(Test Followed In India)	Suresh Sukumar, Sushil Yadav	Medical Science	71-74
30	Magnetic Resonance Imaging of Routine shoulder protocols	Suresh Sukumar, Sushil Yadav	Medical Science	75-76
31	A Simple Teaching Module for Brain Sections: Integration of Traditional Teaching Methods and Modern Computer Technology.	Dr. Archana U. Shekokar, Vandana A. Tendolkar	Medical Science	77-78
32	Effects of Mand Training on Negative Behaviours and Verbal Behaviour Development: A Case Study	Prasanna V, Sunila John, B Rajashekhar	Medical science	79-81
33	Effectiveness of Videotaped/Photographs in Teaching Handling Techniques for Caregivers of Children with Spastic Cerebral Palsy	V.Guruprasad, KR.Banumathe, T. BalaKrishnan	Medical Science	82-84
34	Comparision of Thresholds of Single Frequeny and Muti Frequency Auditory Steady State Responses in Normal Hearing Adults	Sadanand Gore, Hari Prakash P	Medical Science	85-87
35	Clinical applications of Speech Evoked Cortical Auditory Potentials (SECAPs) in Pediatric Hearing assessment & Aural habilitation- A case report	Ayas Muhammed, Archana, Kishan, Hariprakash, Prajakta Prabhu	Medical science	88-89
36	Rudimentary horn pregnancy: A Case Report	Dr Ashwini Avinash Yelikar , Dr Vidya Vijender Ambatkar, Dr Kishore Hol, Dr G S Shekhawat	Medicine Science	90-91
37	A rare case: Typhoid fever with ARDS	Dr. Ramakrishna Ghubde, Dr. Archana Shekokar	Medicine Science	92-93
38	Motivation, Well-Being & Adjustment of Economic Downturn Survivors: An Empirical Study in a Manufacturing Industry	Vijaya.R, Dr.M.Y.Manjulat	Psychology	94-96
39	Diversity of cladocerans, copepods and ostracods of Kapsi Lake Kapsi, Akola (MS) India	P. P. Ade	Zoology	97-100
40	Study of macromolecular contents of different tissues of Channa punctatus under stress condition	Pooja S. Thakur	Zoology	101-102
41	Spider diversity of Katepurna Sanctuary District Akola (MS) India	Shegokar M.M.	Zoology	103-106

Volume : 1 | Issue : 2 | July 2012 • ISSN No 2277 - 8160

Research Paper | Medical Science

Magnetic Resonance Imaging of Routine shoulder protocols

Suresh Sukumar Department of Medical Imaging Technology, Manipal University

Sushil Yadav Department of Medical Imaging Technology, Manipal University

ABSTRACT

Our aim is to review several shoulder abnormalities that are difficult to detect accurately on shoulder MRI, describe the technical reasons that limit their detection, and suggest imaging protocol modifications that may improve radiologists' accuracy.This article provides a brief overview of magnetic resonance imaging (MRI) of the shoulder for the clinician. A basic review of MRI shoulder protocols is followed by a discussion of the most common imaging sequences.

KEYWORDS: Shoulder joint , Magnetic resonance imaging, protocol

Introduction

The shoulder is composed of three joints: glenohumeral, acromioclavicular and scapulothoracic articulations. A fourth joint, the sternoclavicular joint is associated with shoulder and joint mechanics (John V Crues III et al., 1999). The glenohumeral joint allows a greater range of movement than any other joint in the body. This is facilitated by deepening of the shallow glenoid fossa by the fibrocartilaginouslabrum. The capsule is strengthened anteriorly by several thickenings, namely the anterior and posterior bands of the inferior glenohumeral ligament, the variable middle glenohumeral ligament and the smallest superior glenohumeral ligament. The tendon for the long head of the biceps originates from the supraglenoid tubercle, passes intra -articularly and extends into the bicipital groove between the supraspinatus and subscapularis tendon. A synovial sheath surrounds the tendon, which is an extension of the synovial lining of the glenohumeral joint.

The coracoacromial arch has a fundamental role in stabilizing the unstable glenohumeral joint. The arch is formed by the humeral head posteriorly, the acromion superiorly and by the coracoid process and coracoacromial ligament anteriorly (Kaplan et al, 2001). Located within the coracoacromial arch from superior to inferior are the subacromial/subdeltoid bursa, the supraspinatus tendon and muscle, and the long head of the biceps tendon. The coraco acromial ligament is an important structure as it limits anterior and superior motion of the humeral head and overlying tendons. Anything that decreases the space within the coracoacromial arch could lead to impingement symptoms. Different planes of imaging must evaluate these structures that form or are contained in the arch.

The Acromioclavicular joint is a fibrocartilaginous synovial joint reinforced superiorly and inferiorly by the acromioclavicular ligament.

The rotator cuff is a thick tendinous sheet that surrounds the humeral head. The cuff is a confluence of four tendons, which are the insertions of the subscapularis, supraspinatus, infraspinatus and teres minor muscles. These are well delineated on MR images as black structures on all pulse sequences. The rotator cuff and associated muscles are important for synchronous rotation of the humerus. The subscapularis, infraspinatus and teres minor also provide internal and external rotation. The cuff is important for the stability and normal function of the shoulder joint (Resnick& Kang, 1997)

Clinical Indications

- Shoulder Impingement syndromes
- Rotator Cuff Tears
- Calcific Tendonitis
- Glenohumeral Joint Instability
- Adhesive capsulitis (Frozen shoulder)
- Arthritis
- Shoulder pain
- Shoulder instability
- Shoulder mass, lump or bump

Guidelines:

First aske patient

1. Have you recently injured the shoulder? Date of injury?
2. Did you have X-rays? Please bring your shoulder X-rays if not at New York Hospital.
3. Did you ever dislocate the shoulder?
4. Ever have surgery on the shoulder? Date of surgery?
5. Ever have cancer? Type? Date diagnosed?
6. Is there a shoulder mass?

If patient has history of cancer or if there is a mass, of if there has been prior surgery then schedule during the morning, preferably before 11am. Otherwise you may schedule anytime.

Patient preparation:

Positioning: supine with arm at side and palm facing up. It is useful to tuck the hand under the hip to help keep the shoulder motionless. It is important to shift the patient to one side of the magnet so the shoulder being imaged is closer to the center, "sweet spot" of the magnet. This is especially helpful for fat saturation. Place a vitamin E capsule at the site of any mass or symptoms. A wide strap over the shoulder cinched down tight to the table can help reduce shoulder motion during breathing.

Magnetic resonance imaging machine model :- GE 1.5T HDxT

Coil: shoulder coil

Choice of coil is critical to shoulder MRI because it must provide good signal to noise ratio. Because noise is inherent in the tissue being imaged, it is important that a coil adequately covers the area of interest but cover as little unwanted tissue as possible. Image quality of shoulder MRI depends significantly on improvements in radio frequency coils. Four-channel shoulder array has become available that permit imaging with high resolution, small fields of view and thinner sections. Phased array coils consist of two or more resonating loops. The output signal of each loop is fed into an independent channel of the MRI system. Thus coils do not share noise as long as they remain electrically isolated from each other. Combining quadrature configuration with phased array will achieve good SNR at the required depth and image quality with image homogeneity with the benefits of phased array coils (Zlatkin, 1996)

Landmark: mid-coil

Routine shoulder protocols



Figer 1 -Axial plan

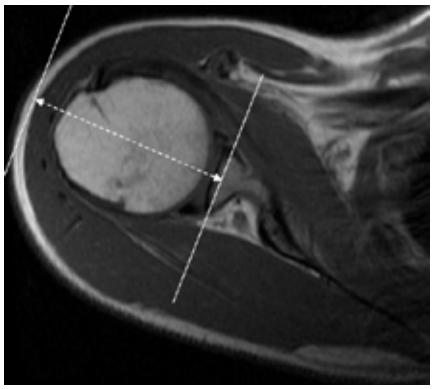

Figer - 2sagital plan

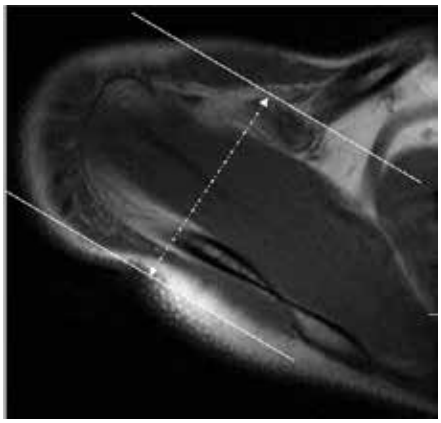

Figer – 3 coronal plan

1.Coronal oblique imaging
Shoulder Coronal Proton density FSE:

The coronal plane is oblique, paralleling the central tendon of the Supraspinatus muscle. Occasionally, magic angle artifact can cause an increase in signal in the distal Supraspinatus tendon, mimicking a tear or tendonosis

Shoulder Coronal T2 fat suppresssed FSE:

T2 fat suppressed sequencing is used for sensitive detection of abnormal fluid of the distal Supraspinatus tendon. In contrast to an inversion recovery sequence, potential magic angle artifact is eliminated due to the long TE of theT2 sequence.

Magic angle artifact can occur on short TE sequences and can result in tendons/ligaments having erroneous areas of high T2 signal. Normally, transverse magnetization decay is enhanced (and therefore T2 is shortened) in non-random structures such as the parallel fibers of tendons and ligaments. But when tendons/ligaments are oriented at 55 degrees to the magnetic field, magnetization decay is hindered, increasing T2 signal intensity. Longer TE sequences are required to allow for full decay of transverse magnetization/T2 signal.

2.Sagital rotator cuff imaging
Sagittal Proton density FSE:

The sequence evaluates the acromial arch, including acromial inferior cortex, acromioclavicular joint, and coraco-acromioligament.

Shoulder Sagittal Proton density, fat suppressed FSE:

This sequence is a 'second look' at the distal rotator cuff tendons. The plane can also be angled obliquely to be more perpendicular to the tendons at insertion.

3..Axialglenoid labrum imaging
Shoulder Axial Proton density, fat suppressed FSE and Axial GRE:

The sequences allow for evaluation of the labrum and glenohumeral ligaments, as well as the glenohumeral cartilage.

4..Shoulder arthrogram
Although T1 fat suppressed post arthrogram sequences have excellent SNR and spatial resolution, their real utility in the shoulder is distention of the joint. Distention allows evaluation of structures that are often too crowded to see adequately, such as the labrum, glenohumeral ligaments and biceps anchor. Partial, articular surface (undersurface) tears of the distal supraspinatus tendons are also particularly well seen

SHOULDER	TR	TE	THICK-NESS	INTER-VAL	FOV
AX PD FS	4000	16	3	1	16 ×16
T2 COR PD FS	2960	16	3	1	16×16
T2 SAG WITH OUT FAT SAT	5020	78	3	1	16×16
PD FS COR	4480	78	3	1	16×16
MERGE IF REQUIRED	848	16	3	1	16×16

Table 1 shows the parameter of Magnetic Resonance Imaging Protocols of shoulder in our Medical College.

CONCLUSION
Although MRI is an excellent tool for detecting some abormalities, there are a number of subtler abnormalities of clinical significance that give radiologists greater difficulty. By understanding the reasons for limited detection and modifying protocols accordingly, radiologists may be able to improve identification, allowing more accurate clinical decision making.

REFERENCES

·Brenner M.L., Morrison W.B., Carrino J.A., Nusser C.A., Sanders T.G., Howard R.F., Meier P. (2000) Direct MR Arthrography: is exercise prior to imaging beneficial or detrimental, Radiology, 215(2):491-496 | ·Creus III J.V., Stoller D.W., RYU R.K.N. (1999) IN:Magnetic Resonance Imaging (eds:Stark DD Bradley WG Jr), 3rd ed., St.Louis, USA, Mosby, | ·Lee S.E. & Lang P. (2000) MR and MR arthrography to identify degenerative and posttraumatic diseases in the shoulder joint, European Journal of Radiology, 35:126-135. | ·Guckel C. &Nidecker A. 1997, Diagnosis of tears in rotator cuff injuries, European Journal of Radiology 25, 168-176. | | ·Jaovisidha S., Jacobson J.A., Lenchi K.L., Resnick D. (1999) MR imaging of rotator cuff tears: is there a diagnostic benefit of shoulder exercise prior to imaging, Clinical Imaging, 23(4):249-253 (abstract). | ·Masciocchi C., Michel C., Barile A., MauriziEnrici R., (1997) The Shoulder: MR Technique, La RadiologiaMedica, 93:143-144. | ·Mirowitz S.A. (1993) Imaging Techniques, Normal Variatios and Diagnostic Pitfalls in Shoulder Magnetic resonance Imaging, MRI Clinics of North America, 1(1): 19-36. | ·Reinus W.R., Shady K.L., Mirowitz S.A., Totty W.G., (1995) MR diagnosis of rotator cuff tears of the shoulder: value of using T2-weighted fat saturated images. American journal of Roentgenology, 164(6):1451-1455. | ·Resnick D. & Kang H.S., (1997) Internal Derangements of Joints, Philadelphia, USA, WB Saunders Company | ·Sahin-Akyar G., Miller T.T., Staron R.B., McCarthy D.M., Feldman F., (1998) Gradient Echo versus Fat suppressed Fast spin echo MR Imaging of rotator cuff tears, American Journal of Roentgenology, 171(1): 223-227. | ·Singson R.D., Hoang T., Dan S., Friedman M. (1996) MR Evaluation of Rotator Cuff Pathology using T2-weighted fast spin echo with and without fat suppression, American Journal of Roentgeonology, 166(5): 1061-1065 | ·Soohoo F.N & Rosen (1996) Diagnosis & Treatment of Rotator Cuff tears in the Emergency Department, The Journal of Emergency Medicine, 14(3): 309-317. | ·Tsao L.Y. &Mirowitz S.A. (1997) MR Imaging of the Shoulder, Imaging techniques, Diagnostic pitfalls and normal variants, MRI Clinics of North America, 5(4):683-704. | ·Tuite M, "Shoulder, Rotator cuff injury (MRI)".online. emedicine.com. July, 2002. Available:http://www.emedicine.com/radio/topic894.htm (25/09/2002). | ·Uri D.S. (1997) MR Imaging Shoulder Impingement and Rotator Cuff Disease, Radiologic Clinics of North America, 35(1): 77-94. | ·Zanetti M. &Hodler J. (2000) Imaging of degenerative and post traumatic disease in the shoulder joint with US, European Journal of Radiology, 35: 119-125. | | ·Zlatkin M.B. (1996) Shoulder IN: Clinical Magnetic Resonance Imaging (Eds: Edelman R.R., Hesselink J.R., Zlatkin M.B.) 2nded, Philadelphia, USA, WB Saunders,



Sara Publishing Academy

GLOBAL RESEARCH ANALYSIS

Multi-Subject Journal

Editor,

GLOBAL RESEARCH ANALYSIS

3, SUHANA, Nr. Ruby Apartment,
B/h NID, Rajnagar Circle, Paldi, Ahmedabad - 380007

Printed at Unique Offset, Novatsing Rupam Estate, Opp. Abhay Estate, Tavdipura, Shahibaug, Ahmedabad

Designed By : AdVoice Inc. +91 9824484447