Volume : 3 | Issue : 6 | June 2014 • ISSN No 2277 - 8160

Research Paper | Medical Science

Mesentric Cyst lymphangioma- A case report

Dr. Amit Garud	PG student in Dept of Surgery, D.Y.Patil Medical College and Hospital, Deemed to be University, Kadamwadi,Kolhapur.
Dr. Abhay Chougale	Professor, Dept of Surgery, D.Y.Patil Medical College and Hospital, Deemed to be University, Kadamwadi,Kolhapur.
Dr. Mrs. Vaishali Gaikwad	Associate Professor, Dept of Surgery, D.Y.Patil Medical College and Hospital, Deemed to be University, Kadamwadi,Kolhapur.
Dr. Sheetal Murchite	Associate Professor, Dept of Surgery, D.Y.Patil Medical College and Hospital, Deemed to be University, Kadamwadi,Kolhapur.
Dr. R. M. Kulkarni	Head of Dept of Surgery, D.Y.Patil Medical College and Hospital, Deemed to be University, Kadamwadi,Kolhapur.

ABSTRACT

Abdominal cystic lymphangiomas are rare congenital benign malformations of the lymphatic system that are usually located in the mesentric area of small intestine. Intraabdominal and retroperitoneal cystic lymphangiomas are cystic benign tumours of congenital origin and thought to occur as a result of the proliferation and dilatation of the lymphatic sacs due to developmental defects of lymphatic vessels. Here we present a case report of a 48 year old female, diagnosed with a mass in abdomen and complaining of abdominal discomfort. The patient was operated and the cyst excised. The cyst was histopathologically diagnosed as mesentric cyst lymphangioma. The patient had no complaints post-operatively and was discharged on 7th day after surgery.

KEYWORDS : Mesentric cyst, cystic lymphangiomas, mesentry

INTRODUCTION-

Mesentric cystic lymphangiomas are rare lesions. They are uncommon benign tumour of congenital origin which presents either with chronic abdominal distension or acute bowel obstruction [1]. They arise as congenital benign malformations of the lymphatic system that are commonly located on small bowel mesentry and less typically on the omentum, mesocolon and retroperitoneum [2, 3, 4]. They are localized or generalized and regarded as congenital malformations that arise from the sequestration of lymphatic tissue failing to communicate with the lymphatic system [5, 6]. The lymphangiomas are often discussed in conjunction with mesentric cysts [5, 7, 8]. However, their histology, location and age of presentation differ significantly [9, 10].

Most lymphangiomas are found in head, neck and axilla of infants [11]. In 90% cases they occur in children below 2yrs, while in adult population they have the incidence of 0.4-1 cases every 100,000 hospitalizations [12, 13, 14]. Abdominal cystic lymphangiomas are more frequent in boys (5:2) with a mean age at presentation of 2yrs.

Here we report a case of mesentric cyst with lymphangiomas occurring in the ileal mesentry of an adult female.

CASE REPORT-

A 61 years old female came in casualty presenting with the complaints of severe abdominal pain since last 15 days. Pain was continuous and was mostly on the left side of abdomen. Patient also complained of continuous vomiting but there were no signs and symptoms of bowel obstruction. The patient had same history of abdominal mass 20 years back and was treated symptomatically. She was brought in D.Y.Patil Hospital for further management.

A per abdominal examination revealed lump and tenderness in the central abdominal quadrant and left flank. USG abdomen revealed a cystic lesion at the root of mesentry. A CT scan of abdomen revealed a vascular malformation-lymphangioma along the central and left side of abdomen.

The patient underwent the exploratory laparotomy; during which a yellowish, ovular cystic mass measuring about 8 x 4cm in diameter showing increased vascularity with smooth contour and was arising from the mesentry of ileum with partial adhesion to the small intestine. The lesion had cystic appearance and was fluid filled. (FIG-1)

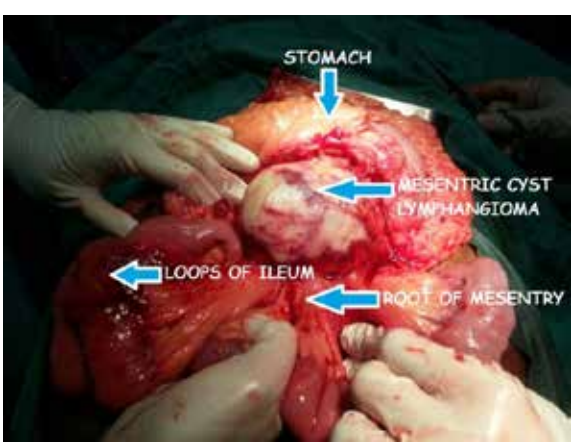

FIG-1

Cyst was excised along with some adhesions with the small intestine. Anterior cystic wall was excised leaving behind the posterior adherent wall. About 200 ml of yellowish to white milky coloured fluid and inspissated material was aspirated. Omentum was placed in remaining cyst wall i.e. marsupialisation was done. The dissected and removed segment was sent for histopathological examination. (FIG-2)



FIG-2

Histopathological examination was consistent with the diagnosis of mesentric cyst lymphangioma. The report revealed that the cyst was lined by flattened mesothelium lining epithelium. Cystic wall was fibrocollageneous with proliferation of blood vessels along with clusters of chronic inflammatory cells which were plasma cells and lymphoid follicles. The bits showed many lymphoid follicles with follicular hyperplasia at few places. (FIG-3)

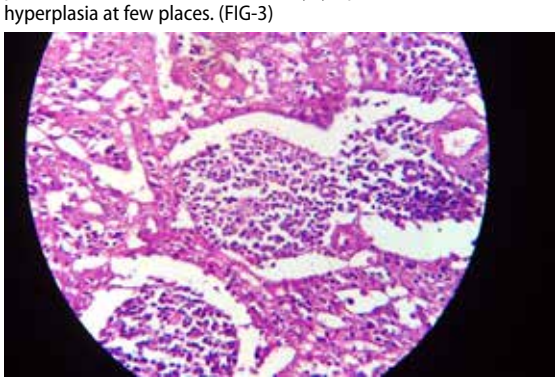

FIG-3 Cyst wall lined by flattened endothelial cells. Wall shows smooth muscles and aggregation of lymphocytes (H & E x 40)

DISCUSSION-

Mesentric cyst lymphangiomas are one of the rare intraabdominal lesions [1]; but occur at all ages, although most 65% are present at birth. Mesentric cyst lymphangiomas are encountered only rarely in surgical practice. The frequency is less than 1/ 100,000 hospital admissions. They occur in children and are commonly i.e. about 95% are located in head, neck and axillary region. The remaining 5% are located in the mesentry, retroperitoneum, abdominal viscera, lung and mediastinum. They are rare especially in adults. [2, 3, 11].

Mesentric cyst lymphangiomas in the abdominal cavity were previously considered as the mesentric cyst; the histological difference between lymphangiomas and mesentric cyst was recently established [11]. In contrast with mesentric cyst which originate from mesothelium, lymphangiomas are composed of alternating lymphoid tissue, lymphatic space and foam cells; thus at the most lymphangiomas in the abdominal cavity originate from the mesentry and form multi-lobular cyst, we refer to them as mesentric cyst lymphangiomas [11].

Most of the patients with mesentric cyst lymphangiomas are initially asymptomatic with vague and obscure abdominal symptoms emerging earlier or late, depending on the size and location of the cyst. The clinical symptoms are pain in abdomen, nausea, vomiting or alteration in bowel habits [2, 16].

Our patient had history of this lesion for last two years but was treated symptomatically and since last 15 days the she complained of severe pain.

Ultrasonography and computed tomography are considered as the most appropriate radio diagnostic procedures to evaluate the cysts of mesentry, although usually ultrasonography alone will suffice [2, 17, 18]. These investigations were also carried out in our patient.

The mode of treatment for mesentric cyst lymphangiomas is exclusively surgical, with complete excision of cystic wall to avoid any recurrence. Due to benign nature, there is no trend to infiltrate the surroundings and lesion is completely removable [12, 19]. In case of involvement of mesentric vascular structures and ileal loops, it might be necessary to resect a loop with restoration of intestinal continuity. In some cases due to extensive involvement of mesentric root, the radical surgical excision is not possible [12].This was revealed in our case also; the lesion invaded extensively the root of mesentry and complete removal was not possible due to severe inflammation and vascular involvement, hence we had to keep intact the posterior wall and excise the anterior wall; thus marsupialisation was done.

A 10% incidence of recurrence had been reported with incomplete resection [20, 21, 22, 23]. Due to these reasons the patient is kept under follow up every 6 months with ultrasonography examination and computed tomography of the abdomen, which is sufficient for the definite diagnosis of recurrence and prognosis of the patient.

CONCLUSION-

Mesentric cyst lymphangiomas are uncommon benign lesions that may rarely present as cystic lesions in the abdomen and usually do not regress. Hence use of ultrasonography with vague and recurrent abdominal pain is highly advisable for the diagnosis of mesentric cyst lymphangioma. The surgeon should be aware of such lesion while evaluating the intraabdominal cystic masses.

REFERENCES

1) Tendon K Rakesh, Darad Dimple, Bindra Ankur, Bhuva Vishal; Giant Mesentric Cyst- Mesentric Cyst Lymphangioma- A Case Report; National Journal of Medical Research; 2012; vol-2,issue-1;105-106. | 2) Yavuz Albayrak, Fatih Albayrak, Serdar Arslan, Ilknur Calik; Mesentric calcified cystic lymphangiomas in an adult patient; Turk J Gastroenterol 2011;22 (3):341-343. | 3) Alqahanti A, Nguyen LT,Flageole H, et al. 25 years of experience with lymphangiomas in children. J Pediatric Surg 1999: 34: 1164-8. | 4) RajiniKudva, AnnappaKudva; Cystic Lymphangioma of Mesentry-A Case Report:International Journalof Scientific and Research Publications, Vol-3, Issue-4, April 2013. | 5) Chih-cheng Luo MD; Chen-Sheng Huang, MD; Hsun-Chin Chao, MD; Shih-Ming Chu. MD; Chuen Hsueh, MD; Intra-Abdominal Cystic Lymphangiomas in Infancy And Childhood; chang Gung Med J Vol.27 No 7; July 2004. | 6) Sun CJ, Tang CK,Hill JL. Mesentric lymphangioma. Arch Pathol Lab Med 1980; 104:316-8. | 7) Farell WJ, Grube P. Intra-abdominal cystic lymphangiomas. Am J Surg 1964; 108:790-3. | 8) Kurtz RJ, Heimann TM, Holt J. Mesentric and retroperitoneal cysts. Ann Surg 1986; 203: 109-11. | 9) Morphis LG, Arcinue EL, Krause JR, generalized lymphangioma in infants with chylothorax. Pediatrics 1970: 4: 566-75. | 10) Sprague NF, Mesentric cysts. Am Surg 1960;26: 42-9. | 11) Byung Hee Kang, Hoon Hur, Yong-Sik Joung, Do Kyung Kim, Young Bae Kim, Chang Wook Ahn, Sang-UK Han and Yong Kwan Cho; j Gastric Cancer 2011; 11 (4): 243-247. | 12) L. IZZO,G. GALATI, Ph.C. SASSAYANNIS, B.BINDA, D.D' ARIELLI, A.STASOLLA, Z.KHARRUB, M.MQRINI, V.D' ALESSANDRO, M.CAPUTO; Mesentric cystic lymphangioma causing intestinal obstruction in an adult patient; G chir Vol.24-n,10-pp.347-349. | 13) Rekhi BM, esselstyn CB Jr, Levi I: Retroperitoneal cystic lymphangioma: report of two cases and review of literature Cleve Q 1972; 39: 125-128. | 14) Kurtz RJ, Heimann TM, Bech AR, I Iolt J: Mesentric and retroperitoneal cysts. Ann Surg 1986; 203: 109-112. | 15) Roberto Mendez- Gallart, MD,PhD, Alfonso Solar-Boga,MD, PhD, Manuel Gomez-Tellado, MD, Phd, Ivan Somoza-Argibay, MD: Giant mesentric cystic lymphangioma in an infant presenting with acute bowel obstruction, J can chir, Vol 52, N 3, jun 2009. | 16) Takiff H, Calabria R, Yin L, Stabile BE, Mesentric cysts and intra-abdominal cystic lymphangiomas. Arch Surg 1985; 120: 1266-9. | 17) Konen O, Rathaus V, Dlugy E, et al.Childhood abdominal cystic lymphangioma. Pedistr Radio 2002:32:88-94. | 18) Traubici j, Daneman A, Wales P et al, Mesentric lymphatic malformation associated with small bowel volvulus- two cases and review of literature. Pediatr Radio 2002; 32: 362-5. | 19) Vezzoi M, Ottini E, Montagna M, La Fiana A, Palli M, Rosso R, Mazzone A: Lymphangioma of the spleen In elderly patient. Hematologica 2000; 85 (3):314-317. | 20) Hisham Fayad Aly; Abdominal Cystic Lymphangioma in Children; Annals of Pediatric Surgery Vol %, April 2009, PP 132-136. | 21) Steyart H, Guitard J, Moscovici j, et al. Abdominal Cystic lymphangioma in children benign lesions that can have a proliferative cours. J Pediatr Surg 31; 677-80, 1996. | 22) Kosir MA, Sonnino RE, Gauderer MW, Pediatric abdominal lymphangiomas; a plea for elderly recognition. J Pediatr Surg 26: 1309-13, 1991. | 23) Mevriye Serpil Diler, Abdurrahim Colak, Munacettin Ceviz, Ugur Kaya, Gurkan Ozturk, Hikmet Kocak; Paraaortic Primary cystic Lymphangioma: A Case Report; CausaPedia 2013; 2; 448. |