Volume : 2 | Issue : 11 | Nov 2013 • ISSN No 2277 - 8160

Research Paper | Medical Science

Neurohistopathological Effects of Gentamycin on Auditory Cortex of Adult Albino Rat

Dr S M Dawar Husain	Associate Professor, Jawaharlal Nehru Medical College Aligarh Muslim University Aligarh-202002, U.P., INDIA
Dr. M. Rehan Asad	Associate Professor, Jawaharlal Nehru Medical College Aligarh Muslim University Aligarh-202002, U.P., INDIA
Dr. S.M. Yunus	Associate Professor, Jawaharlal Nehru Medical College Aligarh Muslim University Aligarh-202002, U.P., INDIA

ABSTRACT

Getamicin, an aminoglycosidic antibiotic, is ototoxic,nephrotoxic and causes neuromuscular blockade as well. A total of twenty albino rats (10 males and 10 females) were used in the present study, and they were equally divided into control and experimental groups. Experimental group rats received gentamicin intramuscularly for 21 days. Control group rats received normal saline. Then rats of both the groups were anaesthetized with nembutol, 35 mg/kg body wt. and perfused with 10% formalin. 10µ thick sections of auditory cortex were stained with H&E and Thionine. Observation under light microscope revealed degenerative changes.

KEYWORDS : Albino rats, Auditory cortex, Gentamicin, Toxic effects

Introduction

Gentamicin is among the group of aminoglycosides that are used to treat aerobic gram negative bacterial infections. Amikacin, kanamycin, neomycin, streptomycin , paromomycin and tobramycin are other antibiotics in this group. The toxicity of these agents is dose related. Aminoglycosidic antibiotics block neuromuscular junction1. Gentamicin was introduced in 1958 by Weinstein. It is nephrotoxic, neurotoxic and ototoxic and it's side effects include ringing in ears, hearing loss, tinnitus, dizziness and anuria. Study was conducted on pharmacokinetics and dosage requirement of gentamycin in 1640 patients receiving treatment of gram-negative infections (daily dose ranged from 0.5 to 25.8 mg/kg2 The effects of gentamycin were studied on 1327 patients, of which 31 patients (2.3%) had significant ototoxicity3 The average frequency of cochlear toxicity for gentamycin was reported to be 8.3% and exact incidence of vestibule-ototoxicity as about 3%4. Disequilibrium and ataxia were noted as main symptoms of vestibulotoxicity5. The chronic toxicity was related to aminoglycoside-phosphoionositol binding6. Evidence of neurotoxicity due to gentamicin and other aminoglycosides is available7. A biochemical basis for the inherited susceptibility to aminoglycoside ototoxicity, has also been reported8. Greater sensitivity of the auditory cortex to aminoglycosidic antibiotics as compared to the periphery (cochlea) was reported9 Gentamycin toxicity was reported to depend on other factors like: dose and kidney function, other potentiating medications, genetic susceptibility and age10.

Though the effects on auditory pathway have been reported along with ototoxic effects but the neurohistological effects of gentamycin on auditory cortex have less well been documented.

So, the present study is aimed to have further insight into the effects of gentamicin on the histology of the auditory cortex, which may explain central cause of ototoxicity.

Material and methods

20 adult albino rats, with equal number of males and females and weighing approximately 130 gms, were used in the present study. They were divided into control and experimental groups. Each group was comprised of 10 rats with equal male and female ratio. Experimental group rats were injected with gentamycin, 135mg/kg of body weight, intramuscularly for 21days (Gentamycin WHO food Additives series 34, www.inchem.org/documents). Control group rats were treated with normal saline in same volume by intramuscular route for 21 days. After this duration, rats were anaesthetized by injecting nembutol, 35 mg/kg body wt and perfused with buffered 10% formalin. Auditory cortex tissue samples were obtained from the floor of lateral sulcus. Tissue samples were processed for paraffin embedding. Then 10µ thick sections were obtained with rotatory microtome. Sections were stained with H&E and Thionine stains for observation under light microscope.

Observations

Compared to control (Figs 1), the histological changes were well marked in the experimental group rats like cytoplasmic swelling and eccentric nucleus with mild degenerative changes in external granular and pyramidal layers (Fig 2)„marked cytoplasmic vacuolation of neurons in ganglionic layer (Fig 3), nuclear changes (irregular margins, chromatin clumping and karyorrhexis) and cytoplasmic (vacuolation) degenerative changes in ganglionic layer (Fig 4). showed cells which were swollen and their Nissl substance showing generalized dispersion (Fig 5),

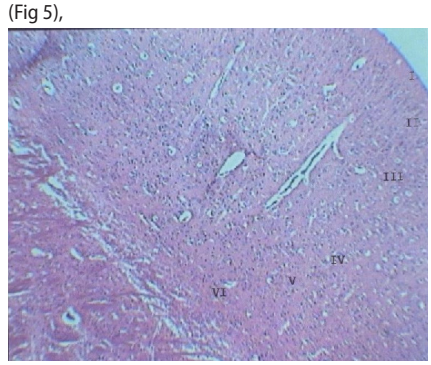

Fig.1 Photomicrograph of the auditory cortex of adult albino rat (control) showing all six layers: 1 (outer molecular), 11 (external granular), 111 (pyramidal), 1V (inner granular), V (ganglionic), V1 (multiform). H&E x 100

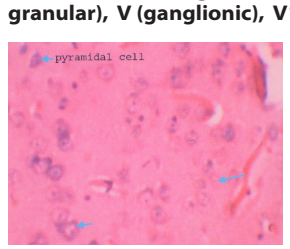

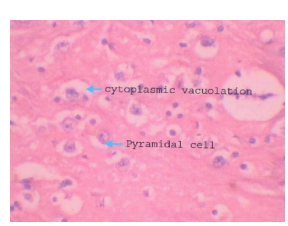

Fig.2 Fig. 3

Photomicrographs of the auditory cortex of adult albino rat (Experimental). Fig.2 showing cytoplasmic swelling and eccentric nucleus with mild degenerative changes in

external granular and pyramidal layers.H&E x400.

Fig.3 showing marked cytoplasmic vacuolation of neurons in ganglionic layer. H&E x 400

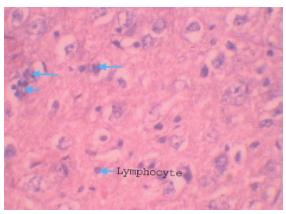

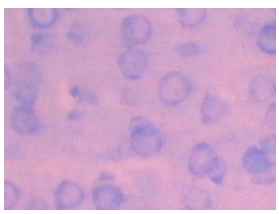

Fig.4 **Fig. 5**

Photomicrographs of the auditory cortex of adult albino rat (Experimental).

Fig.4 showing nuclear (irregular margins, chromatin clumping and karyorrhexis) and cytoplasmic (vacuolation) degenerative changes in ganglionic layer. H&E x 400.

Fig.5 showing cells which are swollen and their Nissl substance showing generalized dispersion. Thionin stain x 400

Discussion

Histological findings in present study were suggestive of degenerative changes in various layers of auditory cortex of experimental group rats. These findings are in conformity with other neurohistological studies like Faruqi et al which showed degenerative changes in the auditory cortex. It was also stated that neurotoxic injury induces changes in nerve cell body in the form of swelling and vacuolation11. It was also reported that prominent nuclear changes with increased size, irregular outline and dispersion of chromatin are characterstic features of neurotoxic injury12. The histological findings observed in our study confirmed the central neurotoxicity as an additional factor in ototoxicity along with well known peripheral toxicity.

Conclusion

Exposure of rat to gentamicin for three weeks produces demonstrable microscopic changes in various layers of auditory cortex.

Acknowledgement: We acknowledge the cooperation of technical and other supporting staff, Department of Anatomy, J.N. Medical college, AMU Aligarh.

REFERENCES

1. C Pittenger, R Adamson. Antibiotic blockade of neuromuscular function. Annual review of pharmacology. 1972; 12, 169-184. | 2. DE Zaske, RJ Cipolle, JC Rotschafer, DL Solem and RJ Strate. Gentamycin pharmacokinetics in 1640 patients: method for control of serum concentration. Antimicrobial agents and chemotherapy. 1982; 407-411. | 3. G Arceiri, GG Jackson Ototoxicity of gentamycin in man: a survey and controlled analysis of clinical experience in the United States. J Inf Dis. 1971; 124 (suppl0, 130-137). | 4. G Kahlmeter, JI Dahlager. Aminoglycoside toxicity: a review of clinical studies published between: 1975 to 1982. J Antimicrob Chemother. 1984; 13 Suppl A, 9-22. | 5. A Takada and J Schacht. Calcium antagonist and reversibility of gentamycin induced loss of cochlear microphonics in the guinea pig. Hear Res. 1982; 8, 179-186. | 6. MG Ganesan, ND Weiner, J Schacht. Effects of calcium and neomycin on phase behaviour of phospholipids bilayers. J pharma Sci. 1983; 72,1465-1466. | 7. NA Faruqi, HS Khan. Effect of streptomycin and kanamycin on central nervous system: an Experimental Study. Indian Journal of Experimental Biology. 1986; 24, 97-99. | 8. M Guan, N Fischel-Ghodsian, G Attardi. A biochemical basis for the inherited susceptibility to aminoglycoside ototoxicity. Human Mol Gen. 2000; 9, 12, 1787-93 | 9. VP Fissenko and NM Gusseinov. Electrophysiological study of the ototoxic effect of aminoglycoside antibiotics in freely moving animals. Vestin Otorhinolaryngol, Moscow Sachenov Medical Academy. 2003. | 10. TC Hain. Gentamycin toxicity. Dizzness and Blance.com. 1999 | 11. AS Fix Ultrastructural pathology of the nervous system. V111 international symposium of the society of toxicologic pathologists meeting abstracts: " toxicologic pathology of nervous system". Toxicologic pathology of nervous system. Toxic pathol. 1999; 27, 690-704. | 12. M Aschners, LG Costa. The reactive astrocytes. The role of Glia in Neurotoxicity. 2004; 2nd edition, 74. |