Volume : 2 | Issue : 4 | April 2013 • ISSN No 2277 - 8160

Research Paper | Medical Science

Non Syndromic Paucity of Interlobular Bile Ducts: A Rare Cause of Neonatal Cholestasis

Sanjay A Natu	Associate Professor, Dept of Pediatrics, Smt Kashibai Navale Medical College, Off Mumbai-BangloreBypass, Narhe, Pune-411041
Ujjwala S Keskar	Associate Professor, Dept of Pediatrics, Smt Kashibai Navale Medical College, Off Mumbai-BangloreBypass, Narhe, Pune-411041
M K Behera	Professor, Dept of Pediatrics, Smt Kashibai Navale Medical College, Off Mumbai-BangloreBypass, Narhe, Pune-411041

ABSTRACT *A one month male baby presented with cholestatic jaundice of recent onset. Ultrasound was normal and TC99 HIDA scan showed no excretion. Liver biopsy revealed paucity of bile ducts. In absence of other features of Alagille syndrome, a diagnosis of non syndromic paucity of interlobular bile ducts was made. Patient was started on supportive management but developed severe pruritis and eventually succumbed to liver cell failure.*

KEYWORDS: Paucity of bile ducts, Alagille syndrome, Neonatal cholestasis

Introduction

Bile Duct Paucity (syndromic – Alagille and non-syndromic) is a well recognized, although uncommon cause of neonatal cholestasis. As the clinical presentation can closely resemble extra hepatic biliary atresia, bile duct paucity will be missed unless an infant with neonatal cholestasis undergoes a comprehensive work up including a liver biopsy (1). We present here a one month baby with non-syndromic paucity of interlobular bile ducts.

Case Report

One month male baby was brought to our tertiary care centre with complaints of yellowish discolouration of eyes and high coloured urine since the previous five days. The baby had no history of pale stools or neonatal jaundice. The baby was delivered vaginally with a birth weight of 3.4 kg and had an uneventful neonatal period. He was exclusively breast fed from birth and had received BCG and OPV on 2nd day of life.

On examination the baby's weight was 4.4 kg. He did not have any dysmorphic features. He was hemodynamically stable and had icterus. His liver was palpable 1 cm below the right costal margin (span 6 cm) and he did not have splenomegaly. His cardiovascular and other systemic examination was normal.

The initial laboratory tests showed haemoglobin of 10.5 g% and normal complete blood count. The prothrombin time was deranged and total bilirubin was 16.3mg% with a direct component of 10.3mg%. Aspartate transaminase was 341 IU/lit (Normal upto 46g IU/lit) and Alanine transaminase was 551 IU/lit (Normal upto 46g IU/lit). Serum alkaline phosphatise was raised to 548 IU/lit (Normal 145-420 IU/lit). Total proteins were 5 g% with albumin of 3 g%. C reactive protein and blood and urine culture were negative. Thyroid function tests were normal. Ultrasound of the abdomen was normal including a normal gall baldder. Hence a primary diagnosis of neonatal hepatitis was made. TC-99m HIDA scan showed no tracer activity in the duodenum even after 24 hours.

Figure 1: Liver biopsy histopathology under high power showing paucity of bile ducts

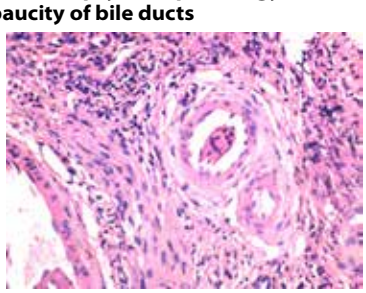

A liver biopsy performed showed portal tract fibrosis with paucity of bile ducts (Figure 1). There was no evidence of cirrhosis on biopsy. An ophthalmological examination, 2D echocardiography and radiographs of the spine were normal. In view of these features a diagnosis of non syndromic paucity of interlobular bile ducts was made. A thorough search was done to find out the aetiology. The metabolic screen was negative and there was no evidence of Cytomegalovirus or other congenital infections. Hence the case was diagnosed as idiopathic non syndromic paucity of interlobular bile ducts.

The child was subsequently discharged with nutritional supplements, cholestyramine and ursodeoxycholic acid and kept on regular follow up. He was readmitted once in the next three months and had progressive worsening of liver function as well as severe pruritis. At the age of 11 months, the child eventually succumbed to liver cell failure and overwhelming sepsis.

Discussion

In children, intrahepatic cholestasis may have a viral, metabolic, or toxic origin or due to structural abnormalities of the intrahepatic bile ducts, which has been described under various names (intrahepatic biliary hypoplasia, hypoplasia of interlobular bile ducts, ductular hypoplasia, ductopenia, paucity of interlobular bile ducts). Paucity of interlobular bile ducts (PILBD) is the generally accepted term (2). Interlobular biliary hypoplasia is a rare cause of infantile obstructive cholangiopathy. It is characterised by paucity of interlobular bile ducts and small but grossly visible and radiologically patent extrahepatic biliary ductal system (3). Bile duct paucity can be defined only histologically and requires a biopsy specimen that contains at least five portal tracts with a ratio of bile ducts to portal tracts of less than 0.9 (4).

The clinical entity occurs in syndromic and non syndromic forms, the former is called Alagille's syndrome. Presence of atleast three of the following features is essential for diagnosis of Alagille syndrome: cholestasis, characteristic facies, peripheral pulmonic stenosis or hypoplasia, posterior embryotoxon in the eye, and complete or incomplete butterfly vertebrae. Other features that may be associated are retarded mental, physical and sexual development. The disease is transmitted by autosomal dominant mode. Patients usually present with jaundice and pruritis in the first year of life (3). The gene involved is JAG 1, located in the short arm of chromosome 20(5). Morbidity and mortality are linked to the severity of liver and/or cardiac involvement. Currently no cure exists for AGS, and medical management is directed at treating disease in each affected organ system (6).

In the non syndromic form, the bile duct pathology is identical; however, there are no extrahepatic findings and currently there is no clinical, biochemical, radiological, or histological test specific for Alagille syndrome and diagnosis is based solely on the clinical phenotype (6). Por-

tal changes before 90 days of age appear to be sufficiently distinctive to microscopically distinguish non-syndromic from syndromic paucity. Electron microscopic findings suggest that paucity in non-syndromic patients may result from a primary ductal insult (7).

Non-syndromic paucity of bile ducts (NSPILBD) has been reported in various conditions, including infections, metabolic disorders, structural disorders, toxic insults, and chromosomal abnormalities. Even after thorough investigation, most cases of NS-PILBD remain idiopathic (4). While Alagille's syndrome is recognized as an important and relatively common cause of neonatal cholestasis, reports about non-syndromic PILBD are quite rare (2).

Treatment is supportive and symptomatic. Patients with the non-syndromic variant have a worse outcome and 50 % of them die at the end of the first year due to liver failure (3). Complete clinical and histopathological resolution of non-syndromic form has been described (5).

The present case had direct jaundice and lack of excretion from the biliary tract in the Tc99 HIDA scan, features which are seen in extrahepatic biliary atresia. The diagnosis of bile duct paucity would have been missed if liver biopsy had not been performed. Thus in conclusion, bile duct paucity needs to be identified early by performing liver biopsy so as to avoid unnecessary surgery.

REFERENCES

1. Sibal A, Mishra U. Bile duct paucity – making a case for liver biopsy in the investigation of neonatal cholestasis. Indian Pediatr 2001;38:1430-1. | 2. Koçak N, Gürakan F, Yüce A, Cağlar M, Kale G, Göğüş S. Nonsyndromic paucity of interlobular bile ducts: Clinical and laboratory findings of 10 cases. J Pediatr Gastroenterol Nutr 1997;24:44-8. | 3. Harish J, Iyer VK, Narasimhan KL. Non-syndromic paucity of interlobular bile ducts. Indian J Gastroenterol 2001;20:155-6. | 4. Yehezkely-Schildkraut V, Munichor M, Mandel H, Berkowitz D, Hartman C, Eshach-Adiv O, Shamir R. Nonsyndromic paucity of interlobular bile ducts: Report of 10 patients. J Pediatr Gastroenterol Nutr 2003;37:546-9. | 5. De Tommaso AM, Kawasaki AS, Hessel G. Paucity of intrahepatic bile ducts in infancy--experience of a tertiary center. Arq Gastroenterol 2004;41:190-2. | 6. Figiel SC, Franco A, Pucar D, Lewis KN, Lee JR. Paucity of biliary ducts: A rare etiology of neonatal cholestasis. J Radiol Case Rep 2012;6:29-38. | 7. Kahn E, Daum F, Markowitz J, Teichberg S, Duffy L, Harper R, Aiges H. Nonsyndromatic paucity of interlobular bile ducts: light and electron microscopic evaluation of sequential liver biopsies in early childhood. Hepatology 1986;6:890-901. |