VOLUME-8, ISSUE-6, JUNE-2019 • PRINT ISSN No. 2277 - 8160

Original Research Paper

Dental Science

ORAL VERRUCOUS CARCINOMA: A CASE REPORT AND REVIEW OF LITERATURE

C.Saravanan	Professor, Department or Oral and Maxillofacial Surgery, SRM Kattankulathur Dental College, Potheri
M.Sandhya	CRI, SRM Kattankulathur Dental College, Potheri
M. Sathya Kumar*	Reader, Department of Oral Pathology, SRM Kattankulathur Dental College, Potheri *Corresponding Author
R.Aravindhan	Reader, Department of Oral Pathology, SRM Kattankulathur Dental College, Potheri
K.T.Magesh	Professor and Head, Department of Oral Pathology, SRM Kattankulathur Dental College, Potheri
A.Sivachandran	Senior Lecturer, Department of Oral Pathology, SRM Kattankulathur Dental College, Potheri.

ABSTRACT Oral verrucous carcinoma is a rare, non-metastasizing, warty- variant of squamous cell carcinoma with a multifactorial etiology. As the verrucous lesions bear clinical resemblances, it poses a diagnostic dilemma. The article highlights the paramount importance of histopathologic examination in accurate diagnosis and differentiation between the verrucous lesions. The significance of molecular approaches and IHC are also illustrated. Here, we report a case of a 68 year old male with a malignant growth in the buccal mucosa with clinical resemblance to squamous cell carcinoma along with a review of the scientific literature.

KEYWORDS : Verrucous carcinoma, verrucous lesions, papillary growth

INTRODUCTION:

Oral Verrucous Carcinoma (VC) is defined as a rare, non-metastasizing, well-differentiated variant of oral squamous cell carcinoma [1]. The synonyms used to describe this tumour include Ackerman's tumour, Snuff-Dipper's cancer, Buschke-Lowenstein tumour, florid oral papillomatosis, epithelioma cuniculatum and oral cuniculatum.The incidence of verrucous lesions account for 3% of all biopsied oral lesions [2]. But, 75% of all cases of Verrucous Carcinoma have been reported to occur in oral cavity.In spite of the slow and continuous local growth; VC has excellent prognosis [1, 2].This case report highlights the clinic-pathologic behaviour of the tumour and its resemblance to squamous cell carcinoma.

CASE REPORT:

A 68 year old male patient reported to the hospital with a chief complaint of ulcer and growth in the right corner of lip and cheek for the past six months. History revealed that the patient is diabetic for the past 40 years and is under medication for the same. Patient gave history of pan chewing habit for the past 15 years.Patient was already diagnosed with candidiasis in the same region.

Extra oral examination revealed an ulcer extending from the lower lip involving the commissure (Figure 1). There were no palpable lymph nodes. On intra-oral examination, an exophytic growth was seen involving the right side buccal mucosa, measuring about 5x4cm extending anteriorly from the right commissure of the lipto the posterior buccal mucosa(Figure 2).The surrounding mucosa was erythematous. A provisional diagnosis of malignant growth was made.

Incisional biopsy was performed in the buccal mucosa under local anesthesia and was sent for histopathological examination. The microscopic examination of the hematoxylin and eosin stained section revealed a parakeratotic stratified squamous surface epithelium that showed broad and elongated reteridges that appear to be pushing into the underlying connective tissue (Figure 3). The epithelium showed abundant parakeratin within focal areas that the keratin fills the clefts between the surface projections and shows minimal or no cytological atypia. The stroma was collagenous in nature and shows intense chronic type of inflammatory cell infiltration with increased vascularity. Based of clinical and histopathological correlation, diagnosis of "Verrucous carcinoma" was made.

Wide local excision of the gingiva, alveolar ridges and buccal mucosa was done.The excised specimen contained both hard and soft tissue (Figure 4) that revealed exophytic growth involving buccal mucosa, vestibule, gingiva, lip and skin. Buccal pad fat with upper alveolar bone and teeth are also seen. Multiple bits were taken and all were subjected to histopathological processing. The microscopic examination confirmed the findings of incisional biopsy (Figure 5). All borders were clear and free of neoplastic cells.

DISCUSSION:

Oral verrucous carcinoma is a rare, aggressive, warty variant of oral squamous cell carcinoma, that is characterized by a predominantly exophytic overgrowth of well-differentiated keratinizing epithelium[1, 3].It occurs at numerous sites like paranasal sinuses, larynx, esophagus, lacrimal duct, nasal cavity, external auditory meatus, penis, cervix, vagina, rectum, bladder and skin from the breast, axilla and sole of the feet. It has a strong male preponderance with male: female ratio of 8:2. It is predominantly seen in sixth and seventh decade [1,2].

The most common oral sites of occurrence for VC are buccal mucosa, vestibular mucosa, retrocommissural area, gingiva, alveolar mucosa and lower lip. The sites are attributed to the site of quid placement[2,4]

The etiology of VC is not clear. Tobacco in smoked and smokeless forms, areca nut and betel nut chewing, human papillomavirus (HPV) infection, poor dental hygiene, ill-fitting denture, immunosuppression,low socioeconomic status, alcohol consumption, chronic inflammation, ultraviolet

radiation have been implicated as risk factors in the development of Verrucous carcinoma [1, 5, 6].It is found that 15-51% of oral VCs are found in individuals who are devoid of these habits [1].The role of HPV in oral VC is a matter of debate.However, a synergistic action between chemical carcinogen and viral carcinogen is hypothesized[2]. But,the likelihood of detecting HPV in VC was found to be 29.5% [6].

VC shows marked clinical variations. Initially, a thin, white keratotic plaque is seen which progressively thickens and forms surface projections [2]. The lesions are seen as painless, diffuse, superficially spreading, well-circumscribed, broad-based, largely exophytic growth which resembles a cauliflower. They may be pink or white or erythematous. Lymph node involvement is uncommon. If lymph nodes are palpable, they are usually secondary to the inflammatory reaction to the invasive front of the tumour. The tumour evades bone and destroys the bony tissue but seldom infiltrates the marrow spaces [7].

The clinical differential diagnosis for verrucous carcinoma includes squamous papilloma, Proliferative verrucous leukoplakia, chronic candidiasis, Condyloma acuminatum, Squamous Cell Carcinoma[1].

Papilloma occurs as a painless, pedunculated, exophytic lesion, with finger-like surface projections, white in colour, with pebbled surface occurring at any surface of the oral cavity, that is associated with Human papilloma virus type 6,11[1].

PVL develops as a homogenous leukoplakia initially, which later exhibits exophytic, proliferative, wart-like with multi-focal characteristics, frequently affecting the gingiva, alveolar ridges and buccal mucosa. It unlikely has a female predominance with female: male ratio of 4:1[8]. The diagnostic criteria proposed by Carrad et al includes:

1. Leukoplakia presenting verrucous or wart like areas involving more than two oral sub-sites.
2. Minimum size of all involved site should be at least 3cm
3. History of lesion for minimum 5 years characterized by spreading and enlarging along with recurrences in the previously treated area
4. At least one biopsy to rule out the presence of verrucous carcinoma/hyperplasia or SCC[9].

Verrucous carcinoma does not fulfill the clinical criteria of PVL which helps in the differentiation.

Oral verrucous carcinoma is closely related to lesions like squamous papilloma, PVL and has considerable clinical resemblance. Henceforth, it cannot be distinguished clinically. Precise diagnosis of these lesions could be challenging and requires an adequate biopsy.

Microscopically, VC reveals well-differentiated epithelial overgrowth with wide and elongated rete ridges exhibiting a pushing border invasion into the connective tissue with little pleomorphism, hyperchromatism and mitotic activity. Parakeratin lining of clefts with parakeratin plugging is also noted. Chronic inflammatory cell infiltration in the underlying connective tissue may or may not be present [1, 3]. The level of verrucous projections or epithelial hyperplasia with respect to the adjacent normal epithelium play the key role [4]. It is proved that 20% of the cases of Verrucous Carcinoma have foci of Squamous Cell Carcinoma within the same microscopic field, which are termed as Hybrid Verrucous Carcinoma [3,7].

The histopathological differential diagnosis includes, verrucous hyperplasia, SCC, especially those showing "verrucoid" features, proliferative verrucous leukoplakia, reactive keratosis, epithelial hyperplasia, verruca vulgaris, verruciform xanthoma, keratocanthoma and pseudoepitheliomatous hyperplasia [7].

Verrucous Hyperplasia shows epithelial hyperplasia which is entirely superficial to the adjacent normal epithelium, with no invasion of the hyperplastic epithelium into the connective tissue. Hyperkeratosis or parakeratosis with verrucous surface is noted [3]. Marked inflammatory cell infiltration is seen in the sub-epithelial connective tissue [4].Therefore, the ideal site of biopsy would be the periphery of the lesion along with the surrounding epithelium.

Papilloma shows blunt or pointed finger-like projections as similar to Verruca vulgaris. But the cupping effect produced by the long rete ridges approaching towards the centre as seen in the verruca vulgaris, along with the presence of prominent granular layer helps in the differentiation[9].

PVL shows exophytic verruciform growth with bulbous rete ridges, showing dysplastic changes in the later stage, whereas VC does not exhibit dysplasia. But, at a certain stage VC shows dysplastic changes which shows its progression to SCC[9].

Histologically, the individual cell keratinisation, minimum basal cell atypia, squamous pearl formation, koilocytosis and the tumour cells showing acidophilic, ample cytoplasm and minimum basal atypia are the key features helps to differentiate VC other verrucous lesions [9].

IHC markers have been used to provide a differentiation between VH and VC microscopically, but were unsuccessful as positive staining for p53 have been found in the basal and parabasal cells in both VH and VC [4]. Connective tissue markers like MMP-2, 9, CD31 and CD8 have been found to be useful in differentiating VC from OSCC. CK10 can be useful in differentiating VC from benign squamous lesions.[5].

However, molecular approach provides the best solution to accurately diagnosis and differentiate between VC and squamous cell carcinoma. It is noted that the cell kinetics in VC coincides with normal epithelium and differs from conventional SCC. The S-phase is limited to the basal layer, unlike any invasive cancer. It also confirms that verrucous carcinoma is a diploid lesion, whereas squamous cell carcinoma exhibits aneuploidy [10].

VC in association with other white lesions like oral sub-mucous fibrosis, leukoplakia or PVL has higher recurrence rate, which can be attributed to "field cancerization". Hence long term follow-up of such patients is necessary[6,11].

Verrucous carcinoma is treated by surgery, radiotherapy or a combination of both. However, anaplastic transformation of the lesion treated by ionizing radiation has been reported. Pre-operative chemotherapy has also been proved effective in some advanced cases of VC[1]. The recommended treatment of choice is complete wide local excision with reconstruction. However, there is higher incidence of recurrence when there is an incomplete excision or positive margins. Despite local invasiveness and recurrence, distant metastasis is rarely observed. Recently, intra-arterial infusion of methotrexate and topical 5-aminolevulinic acid-mediated photodynamic therapy has been reported[1].

The prognosis is better than other life-threatening malignant tumours. They are usually slow-growing tumours with good prognosis as there is seldom regional or distant metastasis. The overall prognosis of VC is excellent with survival rates more than 80%. [12]. Higher recurrence rate is observed with hybrid VCs [2].

CONCLUSION:

Verrucous carcinoma represents a rare group of lesion in the

oral cavity. Our case is of clinical interest because it provides useful information on the clinical and pathological aspects of the uncommon lesion. The clinical diagnosis is often challenging, because of similar clinico-pathologic features with other verrucous lesions. Hence, a close collaboration between the surgeon and pathologist is necessary. Care should be taken for long-term follow-up because of the higher degree of malignant transformation and recurrence rate.

Figure 1: Clinical photograph (Extra-oral) showing the exophytic growth



Figure 2: Clinical photograph (Intra-oral) showing exophytic growth on the right buccal mucosa extending o to the lips



Figure 3: Histopathological examination revealing the broad and elongated reteridges of the epithelium that appear to be pushing into the underlying connective tissue.

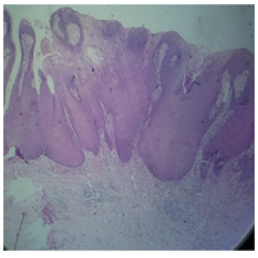

Figure 4: Macroscopic examination of the resescted specimen showing the soft tissue verrucous growth and hard tissues



Figure 5: Excisional biopsy of the resected specimen showing microscopic features of epithelium with abundant parakeratin and the collagenous stroma

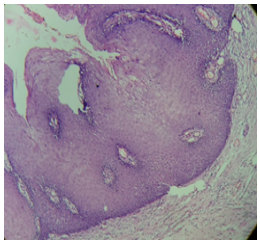

REFERENCES:

1. Alan H, Agacayak S, Kavak G, Ozcan A. Verrucous carcinoma and squamous cell papilloma of the oral cavity: Report of two cases and review of literature. Eur J Dent 2015; 9:453-6
2. Sonalika WG, Anand T. Oral verrucous carcinoma: A retrospective analysis for clinicopathologic features. J Can Res Ther 2016;12:142-5
3. Sharma P, Wadhwan V, Aggarwal P, Sharma A. Oral verrucous hyperplasia versus oral verrucous carcinoma: A clinicopathologic dilemma revisited using p53 as immunohistochemical marker. J Oral Maxillofac Pathol 2016;20:632-8
4. Hazarey VK, Ganvir SM, Bodhade AS. Verrucous hyperplasia: A clinic-pathological study. J Oral Maxillofac Pathol 2011;15:187-91
5. Hosseinpour S, Mashhadiabbas F, Ahsaie MG. Diagnostic biomarkers in Oral Verrucous Carcinoma: A systematic review. Pathol Oncol Res 2017; 23(1):19-32
6. Rao DS, Kalappanavar AN, Ali IM, Annigeri RG. Verrucous carcinoma-an enigma: Case report and review. Contemp Clin Dent 2016; 7:391-3
7. Shergill AK, Solomon MC, Carnelio S, Kamath AT, Aramanadka C, Shergill GS. Verrucous Carcinoma of the Oral Cavity: Current concepts. Int J Sci Stud 2015;3(3):114-115-8
8. Munde A, Karle R. Proliferative verrucous leukoplakia: An update. J Can Res Ther 2016; 12: 469-73
9. Swetha P, Supriya NA, Kumar GN. Characterization of different verrucous mucosal lesions. Indian J Dent Res 2013; 24:642-4
10. Mehrotra D, Goel M, Kumar S, Pandey R, Ram H. Oral verrucous lesion: Controversies in Diagnosis and management. J Oral Biol Craniofac Res 2012; 2(3): 163-69
11. Issrani R, Prabhu N, Keluskar V. Oral proliferative verrucous leukoplakia: A case report with an update. Contemp Clin Dent 2013; 4:258-62
12. Franklyn J, Janakiraman R, Tirkey AJ, Thankachan C, Muthusami J. Oral Verrucous Carcinoma: Ten Year Experience from a Tertiary Care Hospital in India. Indian J Med Paediatr Oncol. 2017;38(4):452–455