GLOBAL RESEARCH ANALYSIS

ISSN No 2277 - 8160

Listed & Indexed with

ISSN Directory, Paris



Multi-Subject Journal

Volume : 1 | Issue : 2 | July 2012 | ₹ 250/-

GLOBAL RESEARCH ANALYSIS

ISSN No 2277 - 8160

GLOBAL RESEARCH ANALYSIS

Editor In-Chief :

Dr. Khansa Memon
SARA Publishing Academy

Dr. Ashok S. Pawar Associate Professor, Dept. of Economic Dr. Babaasaheb Ambedkar Marathwada.University, Aurngabad.(MS-India)-431004	**Dr.(Prof) Vijay Kumar Soni** Principal, Jai Meenesh College, Phagi, Jaipur, Rajasthan	**Dr. A.R. Saravankumar** Assistant Professor in Education DDE, Alagappa University, Tamilnadu
Dr. R. Ramachandran Commerce DDE Annamalai University Tamilna	**Dr. R Ganpathy** Assistant Professor in Commerce Directorate of Distance Education Alagappa University Karaikudi.	**Dr. Amit Bandyopadhyay** Assistant Professor Department of Physiology University of Calcutta
Dr. V. Kumaravel Professor and Head Vivekanandha Business School for Women Tiruchengode, Namakkal Dist	**Dr. K. Prabhakar** Professor, Department of Management Studies, Velammal Engineering College, Chennai - 600 066.	**Dr. Sunita J. Rathod** Maharashtra Education Service Group-B DIET Dist. Jalna

SUBSCRIPTION DETAILS

Period	Rate	Discount	Amount Payable
One Year (12 issues)	3000/-	Nil	3000/-
Two Years (24 issues)	6000/-	200/-	5800/-
Three Years (36 issues)	9000/-	300/-	8700/-
Five Years (60 issues)	15000/-	600/-	14400/-

You can download the Subscription form from website www.theglobaljournals.com. You will require to print the form. Please fill the form completely and send it to the Editor, GLOBAL RESEARCH ANALYSIS along with the payment in the form of Demand Draft/Cheque at Par drawn in favour of GLOBAL RESEARCH ANALYSIS payable at Ahmedabad.

- Thoughts, language, vision and examples in published research paper are entirely of author of research paper. It is not necessary that both the editor, and editorial board agrees with the author. The responsibility of the matter of research paper/article is entirely of author.
- Editing of the Global Research Analysis is processed without any remittance. The selection and publication is done after recommendations of atleast two subject expert referees.
- In any condition if any National/International University denies accepting the research paper published in GRA, then it is not the responsibility of Editor, Publisher and Management
- Only the first author is entitle to receive the copies of all co-authors
- Before re-use of published paper in any manner, it is compulsory to take written permission from the Editor-GRA unless it will be assumed as disobedience of copyright rules
- All the legal undertaking related to Global Research Analysis is subject to Ahmedabad Jurisdiction.
- The research journal will be send by normal post. If the journal is not received by the author of research paper then it will not be the responsibility of the Editor and publisher. The amount for registered post should be borne by author of the research paper in case of second copy of the journal.

Editor,
GLOBAL RESEARCH ANALYSIS
3, SUHANA, Near. Ruby Apartment, B/h NID, Rajnagar Road, Paldi Ahmedabad – 380007. Gujarat (INDIA)
Cell : +91 98247 02127, 8866 00 3636

INDEX

Sr. No.	Title	Author	Subject	Page No.
1	Application of One Way ANOVA and Tukey's HSD Post Hoc test to Ecological Data	T B Mruthunjay, Dr. Shankar P Hosmani	Biotechnology	1-3
2	"New Area and Management Through Value Based"	Dr. Pankaj. K. Trivedi	Commerce	4-5
3	E-Supply Chain Strategies	Dr. Vipul Chalotra	Commerce	6-7
4	Socio-economic and Cultural factors in health, health services and prevention: An over view	Jaibarath Mageshkar	Economics	8-9
5	A Discriminant Analysis on Demographic Factors and Satisfaction Level of Credit Card Users in Coimbatore City	Dr.Malarvizhi.V	Economics	10-12
6	Effects of Socio-Cultural Determinants on Fertility	Prof. Dr. K.J. Thankachan	Economics	13-15
7	"Need of Effective Communication Model in Teaching Learning Process"	Dr. Mujibul Hasan	Education	16-18
8	Awarness on Special Education for B.Ed Students	Dr. S. K. Panneer Selvam	Education	19-20
9	Quality Improvement in Elementary Teacher Education	Ramesh B. Sakhiya	Education	21-22
10	Mobile operating system: A Case study on Symbian and Android	Vidyasagar S.D.	Engineering	23-25
11	IIR Filter Design to remove noise from ECG signal	Aarti J Patel	Engineering	26-28
12	Assessment of Godavari River Water For Sustainable Utilization.	I. B. Ghorade, S. S. Patil, M.D. Wagh	Environment Science	29-32
13	Shiksha, Saksharta aur Media	Dr Subodh Kumar	Journalism	33-34
14	Television Viewing Behaviour of Rural Women	Dr. H.Ramakrishna	Journalism	35-36
15	Female Foeticide and PNDT Act: Issues and Challenges	Dr. Anu, Dr. Pawan Kumar	Law	37-38
16	Product Invasion from foreign Competitors Whether Indian Product will win this Competition?	Dr. Ashish Singh	Management	39-40
17	"Role of State Wise Employment Exchanges on Condition That Employment In India."	Mr. Vimal P. Jagad	Management	41-43
18	A Study for The Growth of Micro, Small, Medium Service Enterprises Thorugh Tourism Development	Prof. Nikita Gupta, Prof. Parag Gadve, Prof. Farha Hussain	Management	44-45
19	To Study The Need of Capacity Building for Rural Tourism	Prof. Parag Gadve, Prof. Nikita Gupta, Prof. Farha Hussain	Management	46-47
20	CRM and Information Technology	Prof KVSN Jawahar Babu	Management	48-49
21	Strategies for Seizing Rural Markets- A Checklist for Fmcg Firms	Prof KVSN Jawahar Babu, N Meena Rani	Management	50-52
22	Implementation of Adaptive Controller based on FPGA for Flow System	Ankit V Bhaiya, Prof. Vandana V. Patel	Management	53-55
23	"A Study of Evaluation of Operating Performance of Selected Mutual Fund in Global Era"	Mital R Menapara, Bhavesh P Chadamiya	Management	56-57
24	"Remarks on the Measurement, Valuation and Reporting of Intangible Assets"	Dinesh C. Dhoniya	Management	58-59

Sr. No.	Title	Author	Subject	Page No.
25	Corporate Social Responsibility: Micro and Macro level	Parul Jain	Management	60-61
26	Role of Management Schools in Transformation of Rural India	Dr. H.Ramakrishna	Management	62-64
27	A Study on Customer Experience in Modern Retail Stores with Reference to Big Bazaar, Hyderabad	N Meena Rani	Management	65-67
28	Impact of Satellite Television on Adolescent Girls of Silchar Town in Southern Assam	Dr Partha Sarkar	Mass Communication	68-70
29	Quality Assurance Procedure for Computerised Tomography Scanners(Test Followed In India)	Suresh Sukumar, Sushil Yadav	Medical Science	71-74
30	Magnetic Resonance Imaging of Routine shoulder protocols	Suresh Sukumar, Sushil Yadav	Medical Science	75-76
31	A Simple Teaching Module for Brain Sections: Integration of Traditional Teaching Methods and Modern Computer Technology.	Dr. Archana U. Shekokar, Vandana A. Tendolkar	Medical Science	77-78
32	Effects of Mand Training on Negative Behaviours and Verbal Behaviour Development: A Case Study	Prasanna V, Sunila John, B Rajashekhar	Medical science	79-81
33	Effectiveness of Videotaped/Photographs in Teaching Handling Techniques for Caregivers of Children with Spastic Cerebral Palsy	V.Guruprasad, KR.Banumathe, T. BalaKrishnan	Medical Science	82-84
34	Comparision of Thresholds of Single Frequeny and Muti Frequency Auditory Steady State Responses in Normal Hearing Adults	Sadanand Gore, Hari Prakash P	Medical Science	85-87
35	Clinical applications of Speech Evoked Cortical Auditory Potentials (SECAPs) in Pediatric Hearing assessment & Aural habilitation- A case report	Ayas Muhammed, Archana, Kishan, Hariprakash, Prajakta Prabhu	Medical science	88-89
36	Rudimentary horn pregnancy: A Case Report	Dr Ashwini Avinash Yelikar , Dr Vidya Vijender Ambatkar, Dr Kishore Hol, Dr G S Shekhawat	Medicine Science	90-91
37	A rare case: Typhoid fever with ARDS	Dr. Ramakrishna Ghubde, Dr. Archana Shekokar	Medicine Science	92-93
38	Motivation, Well-Being & Adjustment of Economic Downturn Survivors: An Empirical Study in a Manufacturing Industry	Vijaya.R, Dr.M.Y.Manjulat	Psychology	94-96
39	Diversity of cladocerans, copepods and ostracods of Kapsi Lake Kapsi, Akola (MS) India	P. P. Ade	Zoology	97-100
40	Study of macromolecular contents of different tissues of Channa punctatus under stress condition	Pooja S. Thakur	Zoology	101-102
41	Spider diversity of Katepurna Sanctuary District Akola (MS) India	Shegokar M.M.	Zoology	103-106

Volume : 1 | Issue : 2 | July 2012 • ISSN No 2277 - 8160

Research Paper | Medicine Science

Rudimentary horn pregnancy: A Case Report

Dr Ashwini Avinash Yelikar	Resident ,Dept of Obst & Gyn ,Smt Kashibai Navale Medical College, Pune
Dr Vidya Vijender Ambatkar	Resident ,Dept of Obst & Gyn ,Smt Kashibai Navale Medical College, Pune
Dr Kishore Hol	Resident ,Dept of Obst & Gyn ,Smt Kashibai Navale Medical College, Pune
Dr G S Shekhawat	Associate Professor- Dept of Obst & Gyn ,Smt Kashibai Navale Medical College, Pune

ABSTRACT

We report a primigravidae with pre rupture diagnosis at 09 weeks of gestation, where timely diagnosis and successful management avoided the catastrophe of eventual rupture. Unicornuate uterus with rudimentary horn occurs due to failure of complete development of one of the Mullerian ducts and incomplete fusion with the contra lateral side. Pregnancy in a non communicating rudimentary horn is extremely rare and usually terminates in rupture during first or second trimester of pregnancy.

KEYWORDS: Rudimentary Horn Pregnancy

Introduction

A unicornuate uterus accounts for 2.4%–13% of all Mullerian anomalies. [2] 72–85% of the rudimentary horns are noncommunicating with the cavity [3]. Unicornuate uterus with rudimentary horn associated with rupture as the most dreaded complication which can be life threatening to the mother.

Case Report

A 22-year-old primigravidae with 09 weeks of pregnancy was reported to our ANC OPD with pain in lower abdomen. The ultrasound examination showed a gestational sac in the right uterine horn. An embryo with a heartbeat and crown-rump length corresponding to 9 weeks 3 days was observed (Figure 1).

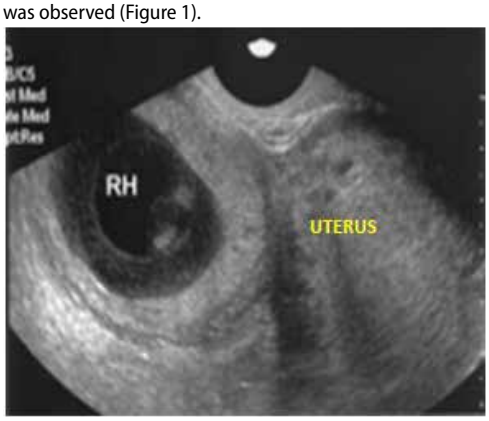

Figure 1- ultrasound picture of right horn pregnancy

A connection between the pregnant horn and the second horn could not be shown, and diagnosis of right rudimentary horn pregnancy was made (Figure2).

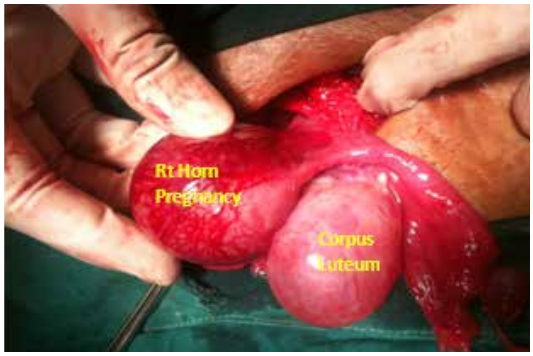

Figure 2-Right horn pregnancy with corpus luteum cyst

Her medical and gynecologic histories were normal. The pregnant horn was attached to the uterus with a fibrotic band. The tubes and ovaries appeared normal. Because of the size and massive vascularity of the pregnant horn, the decision of laparotomy was taken, and the pregnant horn was excised (Figure 3).

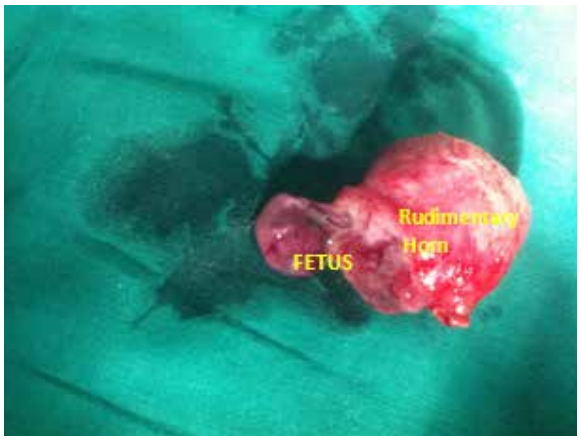

Figure 3- Excised Rudimentary Horn with fetus

Gross examination of resected horn revealed a fetus of around 9 weeks gestation . Her Renal anomalies were excluded by sonography. Her postoperative recovery was uneventful. She was discharged from the hospital on the fifth postoperative day.

Discussion

A rudimentary horn with a unicornuate uterus results due to failure of the complete development of one of the Mullerian ducts and incomplete fusion with the contra lateral side. The incidence is estimated at 1 per 100,000 to 140,000 pregnancies [3]. Pregnancy in a noncommunicating rudimentary horn occurs through the transperitoneal migration of the spermatozoon or the transperitoneal migration of the fertilized ovum [4]. The first case of uterine rupture associated with rudimentary horn was reported in 1669 by Mauriceau [5]. The timing of rupture varies from 5 to 35 weeks depending on the horn musculature and its ability to hypertrophy and dilate. 70–90% ruptures before 20 weeks and can be catastrophic [6]. As the uterine wall is thicker and more vascular, bleeding is more severe in rudimentary horn pregnancy rupture [7]. Kadan and Romano described rudimentary horn rupture as the most significant threat to pregnancy and a life-threatening situation [8]. Early diagnosis of the condition is essential and can be challenging. Ultrasound, hysterosalpingogram, hysteroscopy, laparoscopy, and MRI are diagnostic tools [10]. Fedele et al. have found ultrasonography to be useful in the diagnosis [11]. But the sensitivity of ultrasound is only

26% and sensitivity decreases as the pregnancy advances [12]. Tubal pregnancy, cornual pregnancy, intrauterine pregnancy, and abdominal pregnancy are common sonographic misdiagnosis [13]. There are no definitive clinical criteria to detect this are (1) a pseudo pattern of asymmetrical bicornuate uterus; (2) absent visual continuity tissue surrounding the gestation sac and the uterine cervix; (3) presence of myometrial tissue surrounding the gestational sac. Nonetheless, most of the cases remain undiagnosed until it ruptures and present as emergency. Samuels and Awonuga reported rupture after use of misoprostol due to misdiagnosis [15].Primary strategy of management of rudimentary horn is surgical removal [9]. There are instances of early diagnosis and laparoscopic excision of rudimentary horns. Medical management with methotrexate and its resection by laparoscopy is also reported. Removal of the horn prior to pregnancy in order to prevent complications is also advised. Renal anomalies are found in 36% of cases [12]; hence it is mandatory to further assess these women.

REFERENCES

1. F. Mauriceau, Traite des maladaies des femmes grosses, vol. 1, Compaigne des libraries, Paris, France, 1721. | 2. J. L. O'leary and J. A. O'leary, "Rudimentary horn pregnancy," Obstetrics and Gynecology, vol. 22, pp. 371–374, 1963. | 3. S. Chowdhury, T. Chowdhury, and E. Azim, "Pregnancy in a non-communicating rudimentary horn of uterus: a clinical case report," Bangladesh Medical Journal, vol. 39, no. 1, pp. 47–48, 2010. | 4. Y. Kadan and S. Romano, "Rudimentary horn pregnancy diagnosed by ultrasound and treated by laparoscopy—a case report and review of the literature," Journal of Minimally Invasive Gynecology, vol. 15, no. 5, pp. 527–530, 2008. | 5. B. P. Lawhon, J. R. Wax, and R. T. Dufort, "Rudimentary uterine horn pregnancy diagnosed with magnetic resonance imaging," Obstetrics and Gynecology, vol. 91, no. 5, p. 869, 1998. | 6. L. Fedele, M. Dorta, P. Vercellini, D. Brioschi, and G. B. Candiani, "Ultrasound in the diagnosis of subclasses of unicornuate uterus," Obstetrics and Gynecology, vol. 71, no. 2, pp. 274–277, 1988. | 7. Y. Jayasinghe, A. Rane, H. Stalewski, and S. Grover, "The presentation and early diagnosis of the rudimentary uterine horn," Obstetrics and Gynecology, vol. 105, no. 6, pp. 1456–1467, 2005. | 8. C. H. C. Hassan, A. Kadir, A. Karim, N. A. M. Ismail, and M. H. Omar, "Case report of ruptured non-communicating right rudimentary horn pregnancy: an acute emergency," Acta Medica, vol. 54, no. 3, pp. 125–126, 2011. | 9. C. Simon, L. Martinez, F. Pardo, M. Tortajada, and A. Pellicer, "Mullerian defects in women with normal reproductive outcome," Fertility and Sterility, vol. 56, no. 6, pp. 1192–1193, 1991. | 10. K. Sevtap, A. M. Aral, and B. Sertac, "An early diagnosis and successful local medical treatment of a rudimentary uterine horn pregnancy: a case report," Archives of Gynecology and Obstetrics, vol. 275, no. 4, pp. 297–298, 2007. | 11. M. Scholtz, "A full-time pregnancy in a rudimentary horn of the uterus," British Journal of Obstetrics & Gynaecology, vol. 58, pp. 293–296, 1951. | | 12. G. Nahum, "Rudimentary uterine horn pregnancy: the 20th-century worldwide experience of 588 cases," Journal of Reproductive Medicine, vol. 47, no. 2, pp. 151–163, 2002. | 13. F. Bahadori, S. Borna, T. Behroozlak, S. Hoseini, and H. Ayatollahi, "Failed induction in second trimester due to pregnancy in an uncommunicated rudimentary horn: case report," Journal of Family and Reproductive Health, vol. 3, no. 3, pp. 95–97, 2009. | 14 A.Tsafrir, N. Rojansky, H. Y. Sela, J. M. Gomori, and M. Nadjari, "Rudimentary horn pregnancy: first-trimester prerupture sonographic diagnosis and confirmation by magnetic resonance imaging," Journal of Ultrasound in Medicine, vol. 24, no. 2, pp. 219–223, 2005. | 15. A. Samuels and A. Awonuga, "Second-trimester rudimentary uterine horn pregnancy: rupture after labor induction with misoprostol," Obstetrics and Gynecology, vol. 106, no. 5, pp. 1160–1162, 2005. |



Sara Publishing Academy

GLOBAL RESEARCH ANALYSIS

Multi-Subject Journal

Editor,

GLOBAL RESEARCH ANALYSIS

3, SUHANA, Nr. Ruby Apartment,
B/h NID, Rajnagar Circle, Paldi, Ahmedabad - 380007

Printed at Unique Offset, Novatsing Rupam Estate, Opp. Abhay Estate, Tavdipura, Shahibaug, Ahmedabad

Designed By : AdVoice Inc. +91 9824484447