Volume : 3 | Issue : 4 | April 2014 • ISSN No 2277 - 8160

Research Paper | Medical Science

Review of Literature on Bioceramics

Dr Kalyani Trivedi	Professor and Head of Department of Orthodontics and Dentofacial Orthopedics , Karnavati School of Dentistry.
* Dr Jagruti Ahir	Postgraduate Student of Department of Orthodontics and Dentofacial Orthopedics, Karnavati School of Dentistry. * corresponding author.
Dr Zeal Patel	Postgraduate Student of Department of Orthodontics and Dentofacial Orthopedics, Karnavati School of Dentistry.
Dr Jalpesh Jingar	Postgraduate Student of Department of Orthodontics and Dentofacial Orthopedics, Karnavati School of Dentistry.
Dr Zahid Patel	Postgraduate Student of Department of Orthodontics and Dentofacial Orthopedics, Karnavati School of Dentistry.

ABSTRACT *Transverse maxillary deficiency is a common problem among orthodontic patients. Orthopedic and orthodontic forces are used to correct transverse maxillary deficiency in young patients. Correction of transverse maxillary deficiency in a skeletally mature patient is carried out by Surgically assisted rapid palatal expansion (SARPE). The aim of this article is to present a comprehensive review of the literature, for diagnosis and selecting the suitable treatment options and stability of transverse maxillary discrepancy.*

KEYWORDS : Maxillary Expansion, Palatal Expansion Technique, Crossbite.

Introduction

Transverse maxillary deficiency is identified by narrow maxilla in relation to the rest of the craniofacial structures, and narrow palatal vault. Many a times Transverse maxillary deficiency may cause crossbite, anteroposterior discrepancies, dental crowding, and airway problems. Among the various etiologies of transverse maxillary deficiency it can be due to both genetic and environmental factors, soft tissue influences, cleft palate, and habits[1]. There are various treatment modalities which are used to correct Transverse maxillary deficiency such as, slow maxillary expansion ,Rapid maxillary expansion, Surgically assisted Rapid maxillary expansion etc. Selection of appliance and method is based on the age of patient, nature of discrepancy, etiology and type of malocclusion.

Growth of Mid Palatal Suture

After 12 weeks the midpalatal suture develops in utero. According to a study by Snodell et al.[2] the transverse dimension reaches first to the adult size, followed by sagittal and vertical. The midpalatal suture does not fuse till somewhere between the ages of 15-18 years on average and even older in some cases. Bjork found that at the age 17 the median suture fused[3].Melsen stated that the maxillary suture fused at the age 16 years in females and 18 years in males, while Snodell et al. found that completion of the transverse growth for majority of females at age 15 and 17 years for males[2].This is important for determining the timing of rapid maxillary expansion treatment, as it is expected to be successful in patients that have not reached the age in which their midpalatal suture has fused. Implant studies by Bjork and Skieller concluded that there is greater amount of transverse growth posteriorly than anteriorly[3].

Etiology of transverse discrepancies:

Transverse maxillary discrepancies can be dental or skeletal in origin or a combination of both. Likewise, the discrepancy may be in the maxilla or the mandible or a combination of both. Haas makes an important point in distinguishing true maxillary deficiency from relative maxillary deficiency[4,5,6].

Etiology of Transverse maxillary deficiency :

Etiology of transverse maxillary discrepancies are Palatal dimensions and inheritance[7,8], Iatrogenic (cleft repair)[9,10,11], Cleft lip and palate[12,13], Muscular[14-18], Habits like thumb sucking[14-17], Obstructive sleep apnea[14-17], Klippel-Feil syndrome[19], Marfan syndrome[13], Duchenne muscular dystrophy[18], Non-syndromic palatal synostosis[20], Osteopatia striata[21], Treacher Collins[21] and Multifactorial.

Diagnosis

There are various methods used to diagnose the maxillary transverse deficiency.Clinical evaluation, model analysis, occlusograms, and radiographic measurements are recommended for an accurate assessment[6].

In Clinical evaluation assessment of the maxillary arch form and symmetry, width of the buccal corridors on smiling, shape of the palatal vault, severe crowding, Unilateral or bilateral crossbite, and mode of breathing, the soft-tissue thickness should also be evaluated. Another factor which should be evaluated is a mandibular shift on closure. This can often be a chin deviation with a unilateral crossbite[22,23].

Study models should be used to assess the shape and arch form and make specific measurements to evaluate transverse maxillary deficiency. There are various indices which have been proposed to measure lateral discrepancies.The most common are Pont, Linder-Harth, and Korkhaus[24].The digital model are also useful in diagnosis, they give desired cross-sectional view that gives better visualization of the buccolingual inclination of the teeth, it can also generate images for occlusograms[25,26].

Lehman et al.[27] said that a palatal or an occlusal radiograph is an essential tool to evaluate the ossification of the midpalatal suture which can be unreliable because of the superimposition of other bony structures on the midpalatal suture.

Betts et al.[28] suggested that postero-anterior cephalograms are the most readily available and reliable means to identify and evaluate transverse skeletal discrepancies between the maxilla and the mandible, using cephalometric landmarks as described by Ricketts[29] .The advent of 3-dimensional imaging techniques is the most recent tool for diagnosis that gives an

accurate visualization of the craniofacial region. It also allows for evaluation of the spatial relationships of various areas of the jaws[30].

INDICATIONS FOR MAXILLARY EXPANSION

The clinical situations in which maxillary expansion should be considered are:

Crossbites:

Unilateral and bilateral Crossbites.

Distal Molar Movement

Headgear is often used to distalize the maxillary molars to increase arch length for crowding and overjet reduction. During distal molar movement, it is important to increase the intermolar distance , so that crossbite is not created in the molar region as a narrower part of the upper arch is moved back against a wider part of the lower arch. Expansion in these cases can be achieved by keeping the inner bow of the headgear slightly expanded[31].

Functional Appliance Treatment

Functional appliances are commonly used in the treatment of moderate Class II malocclusion in growing patients. In the majority of cases, it is important to expand the maxillary arch during treatment in order to maintain arch co-ordination. The amount of expansion required can be judged by asking the patient to bite the incisors in an edge-to-edge position and checking the size of the transverse discrepancy that develops in the buccal segments.

A number of techniques can be used to increase inter-molar width along with the functional appliance treatment, like the use of a midline expansion screw (e.g. the Twin Block appliance), and buccal shields (The Function Regulator appliances of Frankel) [31].

Surgical Cases

Arch expansion may be indicated in a number of joint orthodontic-orthognathic cases in order to maintain arch coordination following correction of the sagittal skeletal discrepancy[31].

Maxillary Protraction

Rapid maxillary expansion may be used for maxillary protraction using reverse pull headgear as it disrupts the circummaxillary sutures, it can be used for the treatment of skeletal Class III malocclusion in growing patients.

Mild Crowding: Maxillary expansion may be used in selected cases for the relief of mild crowding.

TECHNIQUES AVAILABLE FOR MAXILLARY EXPANSION

Rapid maxillary expansion

Rapid maxillary expansion (RME) is one of the most commonly used methods by orthodontics to treat this problem. Philosophy of RME is widening the dental arch by means of opening the mid palatal suture. The concept was given in 1860 when Angell described rapid expansion in a paper to the dental community. RME produces expansion that is 50% dental and 50% skeletal[32].

Factors to be considered prior to RME[33].

- Discrepancy between maxillary and mandibular first molars & bicuspid width is more than 4mm is indicated.
- Severity of cross bite: i.e. number of teeth involved.
- Initial angulation of molars or premolars.
- Assessment of roots of deciduous tooth.
- Physical availability of space for expansion.
- Rate of expansion: Expansion of dental arch increases as rate of expansion is increased.
- Form of expansion: Effect of expansion increases as rigidity is increased.
- Age of patient: Effect of expansion diminishes as age advances.

Tooth borne RME Appliances

HYRAX TYPE

With the help of special type of screw HYRAX (Hygienic rapid expander)[34] which consist of heavy gauge wire extensions adapted to follow palatal contour which are soldered to bands on premolars and molars, and can produced expansion of 11 mm in very less period of time ,each activation of screw produced 0.2 mm of lateral expansion.



Figure-1 Hyrax expander

ISAAC SON TYPE

Spring loaded screw-MINNE expander (Developed at University of Minnesota Dental School) are used. The First premolars and molars are banded. Metal flanges are soldered to bands on both buccal and lingual sides. Coil spring made to extend between the lingual metal flanges. Activation is done by closing the nut[34].

Tooth and tissue born

HAAS TYPE

First premolar and molar of either side are banded, 0.045 inch length SS wire is welded and soldered in buccal and palatal aspects of bands. Lingual wire is kept long and extends anteriorly and posteriorly. Extension are bent palatally and embedded in palatal acrylic. It can produced expansion in 10-14 days[5]. It produces force up to 3-10 pounds.

Derichsweiler type

First premolars and first molars are banded. Wire tags are soldered on the palatal aspect of bands and the wire tags are inserted into split palatal acrylic plate with screw at the centre.

The advantage of a banded appliance is that oral hygiene can be maintained. The Haas appliance contains palatal flanges, which are in contact with the palatal mucosa, through which expansion forces are transmitted directly to the skeletal structures. The bonded appliance can be given easily during the mixed dentition stage, when retention from other appliances can be poor. The buccal capping limits extrusion of the molars during treatment and so overbite control is improved[35].

Mode of action

RME produces expansion by a greater degree of skeletal movement and less tipping of the molars. Wertz[36] found that approximately 40% of the expansion achieved could be due to skeletal changes. The ratio between anterior to posterior skeletal expansion was approximately 2:1 and the greatest skeletal response was achieved when treatment was carried out before or during puberty. The expansion in posterior maxilla is less because of the resistance produced by the zygomatic buttress and pterygoid plates. In long-term, it appears that there is continual relapse after initial treatment up to five years [37].

Clinical Management of RME

Activation schedule: Schedule by Timms[38].

Patients of up to 15 years of age, 90° rotation in the morning and evening. In patients over 15 years, Timms recommends 45° activation 4 times a day.

Schedule by Zimring and Isaacson: In young growing patient, two turns each day for 4-5 days and later one turn each day till the desired expansion is achieved. In case of non growing adult patients, two turns each day for first two days, one turn per day for next 5-7 days and one turn every alternate day till the desired expansion is achieved[34].Active treatment is usually required for a period of 2–3 weeks, after which a retention period of three months is recommended to allow for bony infilling of the separated suture. During retention, a ligature wire can be tied around the expansion screw to prevent it turning inadvertently[31].

Effect of RME on The Maxillary Complex

Structure	Effect of RME
Maxillary halves	The two halves of the maxilla rotated in both the sagittal and frontal planes.
Palatal vault	Maxilla displaced downward and forward[5].
Alveolar process	The palatal vault height decreased significantly during RME, Lateral bending of the alveolar processes occurs early during RME[39].
Circummaxillary sutures	Increased width in the intermaxillary, internasal, maxillonasal, frontomaxillary, and frontonasal sutures[40].
Maxillary teeth	Midline diastema between 1/1 Posterior Teeth show buccal tipping and believed to extrude to a limited extent[41].
Effects of RME on the mandible	RME could lead to a concurrent expansion of the lower arch as much as 4 mm in inter-canine width and 6 mm in inter-molar width[42].
Effects of RME on nasal volume changes	Nasal width and volume increases by RME[43].
Effect of RME on soft tissue	Nihat Kilic and et al , concluded in their study that the soft tissue facial angle decreases and the H angle and profile convexity increases after RME[44].

Table 1: Effect of RME on The Maxillary Complex

SURGICAL TECHNIQUES

Surgically assisted expansion techniques can be considered in skeletally mature patients with significant transverse discrepancies.

The techniques available include:

Surgically Assisted Rapid Palatal Expansion (SARPE);

Segmental maxillary surgery.

SARPE

The main resistance to maxillary skeletal expansion comes from the buttressing effect of the zygomatic and sphenoid bones at their point of attachment to the maxilla and from the integrity of the midpalatal suture. With SARPE, these attachments are surgically altered because which expansion to be easily achieved with a conventional RME appliance. Fixed appliances can be used to move apart the roots of the central incisors before surgery so that the roots are not damaged by the midline maxillary cuts. Expansion is typically carried out at a rate of 0.5 mm a day and patients develop a significant midline diastema. Surgical expansion has a high relapse tendency,because of the inelasticity of the palatal mucoperiosteum, and so it is advised to achieve a greater degree of over correction[31].

Segmental Maxillary Surgery

Transverse expansion can be produced during a Le Fort 1 osteotomy by creating an additional surgical cut along the midpalatal suture. The maxillary halves are then separated and retained in the new position. The relative inelasticity of the palatal mucoperiosteum limits the degree of expansion that may be achieved. Before surgery, orthodontic treatment involves moving the roots of the maxillary central incisors apart to improve surgical access to the osteotomy site. This is the technique of choice in patients who require expansion and have co-existing sagittal and/or vertical maxillary discrepancies[31].

Slow Maxillary expansion (SME)

Slow maxillary expansion produces less tissue resistance around the circummaxillary structures and, therefore we get improved bone formation in the intermaxillary sutures, which is a limitation of RME.

Slow expansion has a greater post expansion stability[39,41] if given an adequate retention period. It delivers a constant and physiologic force. The desirable force level is 400 g 450 to 900 gm, which may be insufficient to separate a progressively maturing suture[31,33,41,45]. Maxillary arch width can increases up to range 3.8 to 8.7 mm with slow expansion of as much as 1 mm per week.

Slow maxillary expansion Appliance

Coffin spring

Walter gave the coffin 1975.It is a Removable appliance producing slow dento alveolar expansion. It Consist of one omega shape wire of 1.25 mm thickness, placed in mid palatal region. The spring is activated by pulling two asides apart manually.



Figure-2 Coffin spring

W –ARCH

Rickets used to treat cleft palate conditions[46]. It is constructed of 36 mil steel wire which is soldered to molar bands. The w –arch is activated by opening the apices of w-arch and can even be adjusted to provide more anterior than posterior expansion, or vice versa . The appliance delivers proper force levels when opened 3-4mm wider than the width and should be adjusted to this dimension before inserting[35].

The Quadhelix Appliance

It is a modification of Coffin's W-spring and was given by Ricketts[47].The incorporation of four helices into the W-spring increases the flexibility and range of activation. The length of the palatal arms of the appliance can be altered, depending upon which teeth are in crossbite. The appliance is soldered to the orthodontic bands which are cemented onto the first permanent molars.

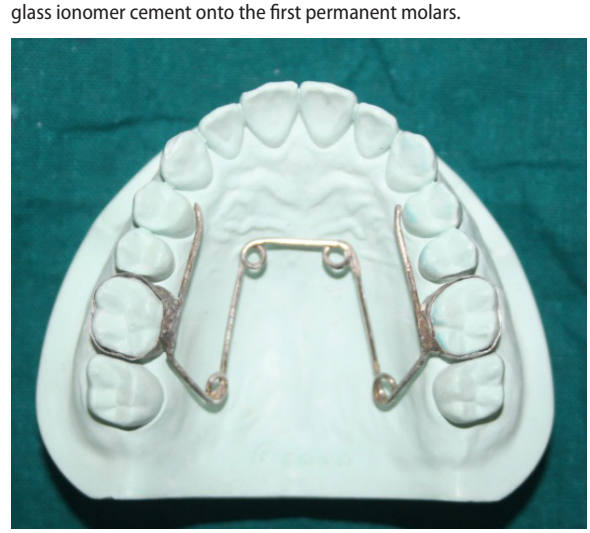

Figure-3 Quadhelix

Mode of Action

The quadhelix appliance gives both buccal tipping and skeletal expansion in a ratio of 6:1 in prepubertal children[48].

Clinical Management
The desirable level of force which is 400 g can be achieved by activating the appliance by approximately 8 mm, which is equal to approximately one molar width. Patients should be reviewed on a six-weekly basis. A three-month retention period, with the quadhelix in place, is recommended[31].

NiTi Expander
Wendell V gave the nickel titanium expanders[49] which gives optimal, constant expansion forces. Its central component is made from a thermally activated nickel titanium alloy, the rest of the appliance, is made of stainless steel. The nickel titanium component has a transition temperature of 94°F[50]. At room temperature, the expander is too stiff to bend for insertion. To manipulate the appliance it has to be chilled to soften the central component. A 3mm expansion exerts only about 350g of force, and the nickel titanium alloy provides relatively uniform force levels as the expander deactivates[35].



Figure4 - NiTi Expander

The Spring jet
The active components of the spring Jet are soldered or attached to the molar bands like any traditional expander. Instead of the transpalatal arch a telescopic unit with a nickel titanium coil spring and a lock screw are given. Activation of the coil spring is done by moving the lock screw horizontally along the telescopic tube. There is a ball stop on the transpalatal wire which allows the spring to be compressed.

The telescopic unit is kept 5mm up from the center of the molar bands, so that the line of force passes close to the center of resistance of the maxillary teeth. Two different coil springs are available using the 240g spring in the mixed dentition and the 400g spring in the permanent dentition[35].

Removable Appliances
A removable appliance, with a midline expansion screw, is a popular device for achieving maxillary expansion. Expansion is produced by tipping the molar teeth buccally. A very small amount of skeletal expansion,can be achieved in prepubertal children.

The patients should be instructed to turn the expansion screw a quarter turn (0.2 mm expansion) once a week. After achieving desired expansion, the appliance can be used as a retaining appliance for at least three months. However, patient cooperation is needed[31].

EXPANSION WITH FIXED APPLIANCES
Expansion with Archwires
Significant expansion can also be produced with over expanded stainless steel archwires, particularly those with a large dimension (for example, 0.021" x 0.025"). The archwire should be over expanded by approximately 10 mm[31].

Auxiliary Arches
Expansion arches, also called as jockey arches, are auxiliary wires given with a fixed appliance during treatment. The expansion arch, which can be made from 0.019" x 0.025" rectangular stainless steel or a larger round steel wire with a diameter of 1–1.13 mm, is given over the main archwire and is inserted into the extra-oral traction tubes of the first molar bands posteriorly and secured anteriorly with a ligature[31].

Self-Ligating brackets- The Damon System
The Damon System introduced by Dr. Dwight Damon is a passive self-ligation system[52]. Damon System's helps to achieve transverse arch development which minimize the need for tooth extractions and procedures like rapid palatal expanders or surgery[51].The necessary expansion can be achieved by the force of the archwires[52].

Pandis *et al.*[53] found that conventional and self-ligating brackets relieves crowding by lower incisor proclination and slight expansion of the dental arches. The intermolar width gained in the Damon2 bracket reached 1.5 mm above the value of conventional appliances. The difference in posterior expansion is because of the differences in the archwire forms and cross-sectional thicknesses.

STABILITY OF CROSSBITE CORRECTION
The factors which may be important for stability of maxillary expansion include:

- Achievement of good intercuspation;
- Alteration in tongue position.

Expanding the maxilla in some cases allows the tongue to adopt a higher resting position which may helps to stabilize the increase in transverse arch dimensions and Mode of respiration. Expansion is less stable in mouth breathers as the position of the tongue is lower[31].

Retention: Retainers should be constructed from acylic and the Hawley type is recommended. The more flexible Essix type of retainer may not have adequate rigidity to counteract the relapse forces[31].

CONCLUSIONS
Maxillary transverse Deficiency can be treated successfully by proper diagnosis and treatment planning. Review of literature suggest different mechanisms for expansion. The precise method selected will depend on the nature of the crossbite (i.e. skeletal versus dental), the size of the discrepancy, the age of the patients and other factors related to the dentition (e.g. amount of dento-alveolar compensation).There are chances of high relapse potential in transverse expansion, so it is important to achieve a degree of over correction and provide adequate retention.

REFERENCES

1. Malandris M, Mahoney EK. Aetiology, diagnosis and treatment of posterior cross-bites in the primary dentition. Int J Paediatr Dent. 2004 May;14(3):155–66. | 2. Snodell SF. Nanda RS, Currier GF.A Longitudinal Cephalometric study of transverse | And vertical craniofacial growth. Am J Orthod Dentofacial Orthop 1993;Nov:104(5) :471-83. | 3. Bjork A.Skieller V.Growth of the maxilla in three dimensions as revealed radiographically by the implant method.Br j Orthod.1977Apr;4(2):53-64. | 4. Haas AJ. Long-term posttreatment evaluation of rapid palatal expansion. Angle Orthod. 1980 Jul;50(3):189–217. | 5. Haas AJ. The treatment of maxillary deficiency by opening the midpalatal suture. Angle Orthod. 1965 Jul;35:200–17. | 6. Lokesh Suri and Parul Taneja Surgically assisted rapid palatal expansion: A literature review(Am J Orthod Dentofacial Orthop 2008;133:290-302) | 7. King L, Harris EF, Tolley EA. Heritability of cephalometric and occlusal variables as assessed from siblings with overt malocclusions. Am J Orthod Dentofacial Orthop 1993;104:121-31. | 8. Westling L, Mohlin B. Palatal dimensions and some inherited factors (body height and metacarpal index). Swed Dent J 1996;20:141-9. | 9. Capelozza Filho L, Cardoso Neto J, da Silva Filho OG, Ursi WJ. Non-surgically assisted rapid maxillary expansion in adults. Int J Adult Orthod Orthognath Surg 1996;11:57-66. | 10. Kim T, Ishikawa H, Chu S, Handa A, Iida J, Yoshida S. Constriction of the maxillary dental arch by mucoperiosteal denudation of the palate. Cleft Palate Craniofac J 2002;39: 425-31. | | 11. Ishikawa H, Nakamura S, Misaki K, Kudoh M, Fukuda H, Yoshida S. Scar tissue distribution on palates and its relation to maxillary dental arch form. Cleft Palate Craniofac J 1998;35: 313-9. | 12. Susami T, Kuroda T, Amagasa T. Orthodontic treatment of a cleft palate patient with surgically assisted rapid maxillary expansion. Cleft Palate Craniofac J 1996;33:445-9. | | 13. Gorlin RJ, Cohen MM Jr, Hennekam RCM. Syndromes of the head and neck. New York: Oxford University Press; 2001. | 14. Harrison JE, Ashby D. Orthodontic treatment for posterior crossbites [update of Cochrane Database Syst Rev. 2000;(2): CD000979; PMID: 10796568]. Cochrane Database of Systematic Reviews 2001:CD000979. | 15. Harrison JE, Ashby D. Orthodontic treatment for posterior crossbites [update in Cochrane Database Syst Rev. 2001;(1): CD000979; PMID: 11279699]. Cochran Database of Systematic Reviews 2000:CD000979. | 16. Zhu JF, Crevoisier R, King DL, Henry R, Mills CM. Posterior crossbites in children. Compend Contin Educ Dent 1996;17: 1051-4, 1056, 1058. | 17. Oulis CJ, Vadiakas GP, Ekonomides J, Dratsa J. The effect of hypertrophic adenoids and tonsils on the development of posterio crossbite and oral habits. J Clin Pediatr Dent 1994;18:197-201. | 18. Symons AL, Townsend GC, Hughes TE. Dental characteristics of patients with Duchenne muscular dystrophy. ASDC J Dent Child 2002;69:277-83, 234. | 19. Barbosa V, Maganzini AL, Nieberg LG. Dento-skeletal implications of Klippel-Feil syndrome. N Y State Dent J 2005;71: 48-51. | 20. Rice DP, Rice R, Thesleff I. Molecular mechanisms in calvarial bone and suture development, and their relation to craniosynostosis. Eur J Orthod 2003;25:139-48. | 21. Koudstaal MJ, van der Wal KG, Wolvius EB, Schulten AJ. The Rotterdam palatal distractor: introduction of the new boneborne device and report of the pilot study. Int J Oral MaxillofacSurg 2006;35:31-5. | 22. Dawson PE. New definition for relating occlusion to varying conditions of the temporomandibular joint. J Prosthet Dent 1995;74:619-27. | 23. Guichet NF. Biologic laws governing functions of muscles that move the mandible. Part I. Occlusal programming. J Prosthet Dent 1977;37:648-56. | 24. Rakosi T, Jonas I, Graber TM. Color atlas of dental medicine: orthodontic diagnosis. New York: Thieme Medical Publishers; 1993. | 25. Faber RD. Occlusograms in orthodontic treatment planning. J Clin Orthod 1992;26:396-401. | 26. White LW. The clinical use of occlusograms. J Clin Orthod 1982;16:92-103. | 27. Lehman JA Jr, Haas AJ, Haas DG. Surgical orthodontic correction of transverse maxillary deficiency: a simplified approach. Plast Reconst Surg 1984;73:62-8. | 28. Betts NJ, Vanarsdall RL, Barber HD, Higgins-Barber K, Fonseca RJ. Diagnosis and treatment of transverse maxillary deficiency. Int J Adult Orthod Orthognath Surg 1995;10:75-96. | 29. Ricketts RM. Perspectives in the clinical application of cephalometrics.The first fifty years. Angle Orthod 1981;51:115-50. | 30. Macchi A, Carrafiello G, Cacciafesta V, Norcini A. Threedimensional digital modeling and setup. Am J Orthod Dentofacial Orthop 2006;129:605-10. | 31. D. Gill, F. Naini, M. Mcnally and A. Jones The Management of Transverse Maxillary Deficiency, Dental Update – November 2004 | 32. Proffit WR, Henry W. Fields, Jr. Contemporary Orthodontics. Third. Mosby, Inc. 2000. | 33. Moyers RE, Vander Linden, FPGM and Riolo ML. Standers of Human Occlusal development ,Monograph 5, craniofacial growth series, Center for Human Growth and Development, Univercity of Michingan. Ann Arbor 1976. | 34. Bishara SE, Staley RN. Maxillary expansion: clinical implications. Am J Orthod Dentofacial Orthop 1987;91:13-4. | 35. Anirudh Agarwal, Rinku Mature. Maxillary Expansion. International Journal of Clinical Pediatric Dentistry, September-desember 2010:3(3):139-146. | 36. Wertz RA. Skeletal and dental changes accompanying rapid midpalatal suture opening. Am J Orthod 1970; 58: 41–66. | 37. Krebs A. Midpalatal suture expansion studies by the implant method over a seven-year period. Trans Eur Soc 1964; 40: 131–142. | 38. Timms DJ. A study of basal movement with rapid maxillary expansion. Am J Orthod 1980;77:500-7. | 39. Issacson R J,Ingram AH.Forces produced by rapid maxillary expansion. Part II.forces present during treatment. Angle Orthod 1964;34:261-9. | 40. Ahmed Ghoneima, Ezzat Abdel-Fattah.et al. Effects of rapid maxillary expansion on the cranial and circummaxillary sutures. Am J Orthod Dentofacial Orthop. Volume 140,Issue 4, Pages 510-519.October 2011. | | 41. Hicks EP. Slow maxillary expansion: a clinical study of the skeletal vs dental response in low magnitude force. Am J Orthod 1978;73:121-41. | 42. Sandstrom RA, Klaper L, and Papaconstantinou S.Expansion of the lower arch concurrent with rapid maxillary expansion. Am J Orthod 1988;94: 296-302 | 43. Doruk Cenk, Comparison of nasal volume changes during rapid maxillary expansion using acoustic rhinometry and computed tomography, European Journal of Orthodontics,2007:29;251–255 | 44. Nihat Kiliç, Effects of rapid maxillary expansion on Holdaway soft tissue measurements, European Journal of Orthodontics, 1998, Vol 30, Issue 3 ;239-243 | 45. Haas, A. J.: Rapid Expansion of the Maxillary Dental Arch and Nasal Cavity by Opening the Midpalatal Suture, Angle Ortho., 31:73-89, 1961. | 46. Ricketts RM. Bench RW . gungino CF. Hilger JJ. Schulhof RJ. Bioprogrresive therapy.Rockey Mt orthod 1979:1:255-58. | 47. Ricketts RM. Growth prediction: Part 2. J Clin Orthodont 1975; 9: 340–362. | 48. Frank SW, Engel AB. The effects of maxillary quadhelix appliance expansion on cephalometric measurements in growing orthodontic patients. Am J Orthod 1982; 81: 378–389. | 49. Wendell V. Arndt, Nickel Titanium Palatal Expander,JCO 1997 MAR 129-137 | 50. Robert Marzban, Ravindra Nanda. Slow Maxillary Expansion with Nickel Titanium ,JCO Volume XXXIII Number 8 1999 | 51. D. Birnie. The Damon Passive Self-Ligating Appliance System. Semin Orthod 2008;14:19-35. | 52. Damon DH. The Damon low friction bracket: a biologically compatible straight-wire system. J Clin Orthod 1998; 32: 670–680 | | 53. Pandis N, Polychronopoulou A, Eliades T. Selfligating vs conventional brackets in the treatment of mandibular crowding: a prospective clinical trial of treatment duration and dental effects. Am J Orthod Dentofac Orthop 2007; 132: 208–215 |