



Ossicular Reconstruction and Hearing Outcome

Dr Trupal Solanki	4th year Resident, Department of ENT, Civil Hospital, Ahmedabad
Dr Ankur Barot	2nd year Resident, Department of ENT, Civil Hospital, Ahmedabad
Dr Nisharg Mehta	2nd year Resident, Department of ENT, Civil Hospital, Ahmedabad
Dr Roma Gandhi	3rd year Resident, Department of ENT, Civil Hospital, Ahmedabad
Dr Rohan Patel	3rd year Resident, Department of ENT, Civil Hospital, Ahmedabad
Dr Rajesh Vishwakarma	Professor & HOD, Department of ENT, Civil Hospital, Ahmedabad

ABSTRACT

Aims & Objectives The purpose of this study was to evaluate the hearing outcome of ossicular reconstruction using 3 different materials namely auricular cartilage (chondral and tragal), titanium prosthesis (total and partial replacement) and autologous bone (incus)

Material & Methods Prospective study was conducted in 40 patients with chronic suppurative otitis media with mastoidectomy with Tympanoplasty at Civil Hospital, Ahmedabad in year 2013-2014. 20 patients were reconstructed with cartilage, 20 with PORP & 20 with autologous bone. Follow up was taken at 6 to 18 months post operatively.

Results Pre operative air-bone gap was 35 to 60 dB. Out of 20 patients who were reconstructed with cartilage, 16 had AB gap less than 25 dB, 4 patient had AB gap less than 20 dB. Out of 20 patients who were reconstructed with bone, 14 had AB gap less than 25 dB, 6 patient had AB gap less than 20 dB. Out of 20 patients who were reconstructed with PORP, 5 had AB gap less than 25 dB, 15 patient had AB gap less than 20 dB.

Conclusion Ossicular reconstruction with cartilage may have possibility of migration, adhesions with promontory and recurrent conductive hearing loss. Autologous bone (incus) restores the integrity of ossicular chain in most natural ways and improves hearing. Although chance of extrusion of titanium prosthesis is possible, but it provides better hearing outcome than cartilage and bone, therefore titanium prosthesis provides excellent alternative to currently accepted method.

KEYWORDS :**Introduction**

- Surgical reconstruction of ossicular chain optimizes the middle ear transformer mechanisms so that the sound energy is directed to the inner ear with minimal energy loss which significantly enhances the hearing outcome.
- **Physiology** : Role of tympanic membrane in sound conduction:
 - Sound pressure collected over the area of the tympanic membrane and transmitted to the area of the smaller footplate results in an increase in force proportional to the ratio of the areas
 - The average ratio has been calculated to be 20.8:1.
 - Taking the three levers together, the middle ear offers a theoretical gain of approximately 34 dB
- **Etiology**
 - Fixation
 - – Malleus head ankylosis (idiopathic)
 - – Ossicular tympanosclerosis
 - – Scar bands in chronic otitis media
 - Discontinuity
 - – Trauma
 - – Erosion by chronic otitis media
 - cholesteotoma (mostcommon)
 - Eroded incudostapedial joint (80% of patients)
 - Absent incus
 - Absent incus and stapes superstructure

According to Merchant & Rosawski five important principles should be kept in mind while doing ossicular reconstruction.

- 1) Tension: The tension under which the implant is placed should be appropriate for optimum hearing.

- 2) Round window : Round window protection is an important factor while doing ossicular reconstruction.
- 3) Angle : A prosthesis (or autograft) should contact the tympanic membrane or malleus at an angle of 45 to 90 degrees.
- 4) Centre: A prosthesis should be positioned so that it can contact tympanic membrane as close to the centre if possible to take advantage of maximum vibratory excursion at this location.
- 5) Space : The air space surrounding the ossicular chain should be more than 0.3 ml.

Aim of the study

The purpose of this study was to evaluate the hearing outcome of ossicular reconstruction using 3 different materials namely auricular cartilage (chondral and tragal), titanium prosthesis (total and partial replacement) and autologous bone (incus)

Method:

It is prospective study consisting of sixty patients who had chronic suppurative otitis media. In this patients mastoidectomy with tympanoplasty at civil hospital, Ahmedabad in year 2013-2014 was done. Twenty patients were reconstructed using auricular cartilage, twenty patients were reconstructed with titanium prosthesis (PORP) and rest twenty with autologous bone (incus). follow up was taken for 6 to 18 months with audiometry pre and postoperatively.

Inclusion Criteria:

Appropriate candidates who had Resolved otorrhoea with no middle ear disease, who had Conductive or mixed hearing loss & had No Eustachian tube dysfunction (ideal) because enough middle ear space and aeration are required to allow for prosthesis and function.

Exclusion Criteria

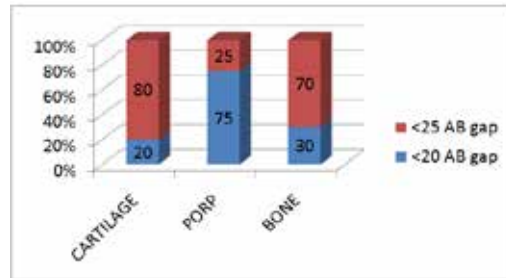
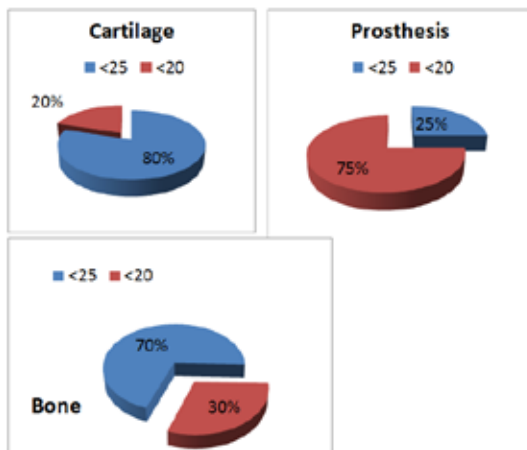
Acute infection of the ear, will most likely result in poor healing, prosthesis extrusion, or both. Relative contraindications include persistent middle ear mucosal disease, tympanic membrane perforation, and repeated unsuccessful use of the same or similar prostheses.

According to Austin classification, ossicular problems are based upon 1) Malleus handle (M+/-), 2) Stapes suprastructure. There are four types of ossicular defect- a) M+ S+, b) M+ S-, c) M- S+, d) M- S-. Cartilage, PORP or remodelled incus are kept between malleus & stapes suprastructure when there is erosion or necrosis of lenticular process of incus. This procedure is performed in conjunction with tympanoplasty & mastoidectomy. If lenticular process is eroded & if the manubrium is in close proximity to stapes supra structure, a sculptated incus is an excellent choice. A groove is made in incus with 1.5mm diamond burr roughly following the natural groove of the joint & acetabulum is created in its short process with 0.5 or 0.7 mm diamond burr. If lenticular process is eroded & if the manubrium is positioned far anterior to the stapes suprastructure because of its inherent instability, use of the PORP has been reported in better Air Bone gap closure. The prosthesis intended to contact the tympanic membrane will usually require a thin conchal or tragal cartilage graft interposition.

Results

Method	Pre operatively (hearing loss in dB)	No of patients	Post operative audiogram (hearing loss in dB)
Cartilage	35-60	16 4	<25 <20
PORP	35-60	15 5	<20 <25
Bone	35-60	14 6	<25 <20

Pre operative air-bone gap was 35 to 60 dB. Out of 20 patients who were reconstructed with cartilage, 16(80%) had AB gap less than 25 dB, 4(20%) patient had AB gap less than 20 dB. Out of 20 patients who were reconstructed with bone, 14(70%) had AB gap less than 25 dB, 6(30%) patient had AB gap less than 20 dB. Out of 20 patients who were reconstructed with PORP, 5(25%) had AB gap less than 25 dB, 15(75%) patient had AB gap less than 20 dB.



Discussion :

Ossicular repositioning was described in 1957 continues to be used today. Early plastic prosthesis suffered from high extrusion rate & stapes foot plate fistula. Homograft ossicles were convenient especially for complete tympanic membrane & ossicular chain reconstruction but ultimately were largely abandoned due to transmission of viral or prion disease.

Wire prosthesis made up of stainless steel, platinum or tantalum were better tolerated in the middle ear but had problems with displacement and extrusion over time. Longest clinical experience exist with plastipore made up of high density polyethylene sponge in 1976.

Plastipore, stapes to tympanic membrane (partial ossicular reconstruction prosthesis) for using cases with an intact stapes supra structure extrusion rates ranging from 5-10% been reported in large series in 5-10 years of follow up.

Brackmann attributed 70% of the extrusions in his series to middle ear pathology such as atelectasis, middle ear fibrosis & otitis media. In early 1970s, hydroxylapatite was introduced had satisfactory long term results in reconstructive procedures but subsequent lighter porous hydroxylapatite became available enhancing intra operative stability & likely hood of osseointegration. Titanium prosthesis were introduced in 1993. They were strong, light weight & has excellent bio-compatibility with remarkable tendency of osseointegration.

Kyrodemos et al used type 3 cartilage shield tympanoplasty in 52 patients, out of that 54% patients had less than 20 dB AB gap & 79% patients had less than 25 dB AB gap.

Schember S et al used PORP or TORP in 111 patients. With PORP 77% patients had less than 20 dB AB gap, with TORP 52% patients had less than 20 dB AB gap.

Gardener EK et al used PORP or TORP in 102 patients. With PORP 70% patients had less than 20 dB AB gap, with TORP 44% patients had less than 30 dB AB gap.

Dalchow et al used PORP or TORP in 1300 patients. With PORP 70% patients had less than 20 dB AB gap, with TORP 76% patients had less than 20 dB AB gap.

In our study 15 patients had less than 20 dB AB gap while 5 patients had less than 25dB AB gap which is better AB gap closure than incus interposition & cartilage.

Conclusion

- Ossicular reconstruction with cartilage may have possibility of migration, adhesions with promontory and recurrent conductive hearing loss. Autologous bone (incus) restores the integrity of ossicular chain in most natural ways and improves hearing. Although chance of extrusion of titanium prosthesis is possible, but it provides better hearing outcome than cartilage and bone, therefore titanium prosthesis provides excellent alternative to currently accepted method.

REFERENCES

- Hall A, Rytznar C. Stapedectomy and autotransplantation of ossicles. *cta otolaryngol(stockh)* 1957;47:318
- Goldenberg R, Emmet JR. current use of implants in middle ear surgery. *Otol Neurotol* 2001;22:145-52
- Kartush JM. Ossicular chain reconstruction. *capitulum to malleus*. *OCNA* 1994;27:689-715
- Goldenberg RA. Hydroxylapatite ossicular reconstruction prosthesis. Results in 157 consecutive cases. *Laryngoscope* 1992;102:1091-6.
- Austin DF. Ossicular reconstruction. *arch otolaryngol* 1971;94(6):525-35.
- Dornhoffer JL. Cartilage tympanoplasty. *OCNA* 2006;39:1161-76.
- Dornhoffer JL, Gardener E. prognostic factors in ossiculoplasty: A statistical staging system. *Otol Neurotol* 2001;22:299-304.
- Pennington CL. Incus interposition techniques. *Ann Otol Rhinol Laryngol* 1973;82(4):518-31.
- Truy e, Naiman AN, Huttenbrink KB. Titanium shoe- a new technique for stabilization of total ossicular reconstruction prosthesis at centre of stapes foot plate. *J Laryngol Otol* 2008;12:682-6.
- De Vos C, Gersdorff M, Gerard JM. prognostic factors in ossiculoplasty. *Otol Neurotol* 2007;28(1):61-7.
- Seidman MD, Babu S, A new approach for malleus/incus fixation: No prosthesis necessary. *Otol Neurotol* 2004;25(5):669-73.