



Neurohistological effects of gentamycin on the Pons of Adult Albino Rat

Dr S M Dawar
Husain

MS (Anatomy), Associate Professor, Department of Anatomy, J N M C,
A M U Aligarh, U.P., INDIA

ABSTRACT

Gentamicin, an aminoglycosidic antibiotic and it is toxic to various parts of the human body. It is ototoxic, nephrotoxic and it causes neuromuscular blockade as well.

A total of twenty albino rats (10 males and 10 females) were used in the present study, and they were equally divided into control and experimental groups. Experimental group rats received gentamicin intramuscularly for 21 days. Control group rats received normal saline. Then rats of both the groups were anaesthetized with ether and perfused with 10% formalin. 10 μ thick sections of pon were stained with Glees Silver stain.

Observation under light microscope revealed degenerative changes.

KEYWORDS : Albino rats, Pons, Gentamicin, Toxic effects

INTRODUCTION

Gentamicin belongs to aminoglycosides that are used to treat aerobic gram negative bacterial infections. Other antibiotics in this group are Amikacin, kanamycin, neomycin, streptomycin, paromomycin etc. Toxicity of these agents is dose related. Aminoglycosidic antibiotics block neuromuscular junction (1) Gentamicin was introduced in 1958 by Weinstein. It is nephrotoxic, neurotoxic and ototoxic and its side effects include ringing in ears, hearing loss, tinnitus, dizziness and anuria. Study was conducted on pharmacokinetics and dosage requirement of gentamicin in 1640 patients receiving treatment of gram-negative infections (daily dose ranged from 0.5 to 25.8 mg/kg) (2). The effects of gentamicin were studied on 1327 patients, of which 31 patients (2.3%) had significant ototoxicity (3). The average frequency of cochlear toxicity for gentamicin was reported to be 8.3% and exact incidence of vestibule-ototoxicity as about 3% (4). Disequilibrium and ataxia were noted as main symptoms of vestibulotoxicity (5). The chronic toxicity was related to aminoglycoside-phosphonitol binding (6). Evidence of neurotoxicity due to gentamicin and other aminoglycosides is available (7). A biochemical basis for the inherited susceptibility to aminoglycoside ototoxicity, has also been reported (8). Greater sensitivity of the auditory cortex to aminoglycosidic antibiotics as compared to the periphery (cochlea) was reported (9). Gentamicin toxicity was reported to depend on other factors like: dose and kidney function, other potentiating medications, genetic susceptibility and age (10)

Though the effects on auditory pathway have been reported along with ototoxic effects but the neurohistological effects of gentamicin on auditory cortex have less well been documented.

So, the present study is aimed to have further insight into the effects of gentamicin on the histology of the pons.

MATERIAL AND METHODS

20 adult albino rats, with equal number of males and females and weighing approximately 130 gms, were used in the present study. They were divided into control and experimental groups. Each group was comprised of 10 rats with equal male and female ratio. Experimental group rats were injected with gentamicin, 135mg/kg of body weight, intramuscularly for 21 days (Gentamicin WHO food Additives series 34, www.inchem.org/documents). Control group rats were treated with normal saline in same volume by intramuscular route for 21 days. After this duration, rats were anaesthetized with ether and perfused with buffered 10% formalin. Pons tissue samples were obtained. Tissue samples were processed for paraffin embedding. Then 10 μ thick sections were obtained with rotatory microtome. Sections were stained with Glees Silver stain for observation under light microscope.

OBSERVATIONS

Pons of the control group shows well stained and defined nerve fibres in high power (Fig- 1). On examination under light microscope, Pons

of the experimental group showed broken, less defined and disorganized nerve fibres and tracts in high power (Fig- 2)

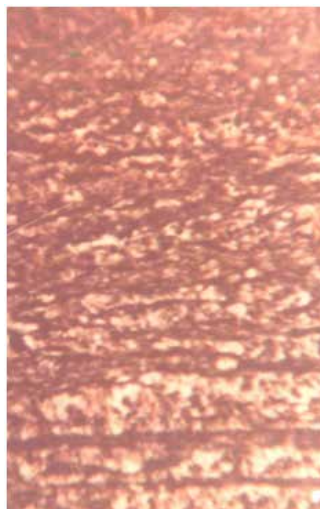


Fig -1 Pons of (control group) shows well stained and defined nerve fibres in high power (Glees Silver stain)

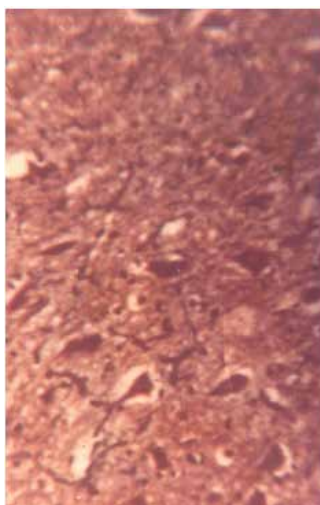


Fig -2 Pons of (experimental group) shows broken, less defined and nerve fibres (Glees Silver stain)

DISCUSSION

Histological findings in present study were suggestive of degenerative changes in the Pons of experimental group rats. These findings are in conformity with other neurohistological studies as it was stated that neurotoxic injury induces changes in nerve cell body in the form of swelling and vacuolation (11). It was also reported that prominent nuclear changes with increased size, irregular outline and dispersion of chromatin are characteristic features of neurotoxic injury (12) Effect of sepsis and systemic inflammatory response syndrome on neonatal hearing screening outcomes following gentamicin exposure was reported (13) Gentamicin extended interval regimen and ototoxicity in neonates, was noted (14) The histological findings observed in our study confirmed the pons neurotoxicity.

CONCLUSION

Exposure of rat to gentamicin for three weeks produces demonstrable histological alterations in the pons.

REFERENCES

1. Pittenger C and Adamson R. Antibiotic blockade of neuromuscular function. Annual review of pharmacology. 1972; 12, 169-184.
2. Zaske DE, Cipolle RJ, Rotschafer JC, Solem DL and Strate RJ. Gentamicin pharmacokinetics in 1640 patients: method for control of serum concentration. Antimicrobial agents and chemotherapy. 1982; 407-411.
3. Arceiri G and Jackson GG Ototoxicity of gentamicin in man: a survey and controlled analysis of clinical experience in the United States. J Inf Dis. 1971; 124 (suppl0, 130-137).
4. Kahlmeter G and Dahlager JI. Aminoglycoside toxicity: a review of clinical studies published between: 1975 to 1982. J Antimicrob Chemother. 1984; 13 Suppl A, 9-22.
5. Takada A and Schacht J. Calcium antagonist and reversibility of gentamicin induced loss of cochlear microphonics in the guinea pig. Hear Res. 1982; 8, 179-186.
6. Ganesan MG, Weiner ND, Schacht J. Effects of calcium and neomycin on phase behaviour of phospholipids bilayers. J Pharma Sci. 1983; 72,1465-1466.
7. Faruqi NA and Khan HS. Effect of streptomycin and kanamycin on central nervous system: an Experimental Study. Indian Journal of Experimental Biology. 1986; 24, 97-99.
8. Guan M, Fischeh-Ghodsian N and Attardi G. A biochemical basis for the inherited susceptibility to aminoglycoside ototoxicity. Human Mol Gen. 2000; 9, 12, 1787-93
9. Fissenko VP and Gusseinov NM. Electrophysiological study of the ototoxic effect of aminoglycoside antibiotics in freely moving animals. Vestn Otorhinolaryngol, Moscow Sachenov Medical Academy. 2003.
10. Hain TC. Gentamicin toxicity. Dizziness and Blance.com. 1999
11. Fix AS, Ultrastructural pathology of the nervous system. V111 international symposium of the society of toxicologic pathologists meeting abstracts: " toxicologic pathology of nervous system". Toxicologic pathology of nervous system. Toxic pathol. 1999; 27, 690-704.
12. Aschners M and Costa LG. The reactive astrocytes. The role of Glia in Neurotoxicity. 2004; 2nd edition, 74.
13. Cross CP, Liao S, Urdang ZD, Srikanth P, Garinis AC, Steyger PS. Effect of sepsis and systemic inflammatory response syndrome on neonatal hearing screening outcomes following gentamicin exposure. Int J Pediatr Otorhinolaryngol. 2015 Nov;79 (11):1915-9.
14. El-Barbary MN, Ismail RI, Ibrahim AA. Gentamicin extended interval regimen and ototoxicity in neonates. Int J Pediatr Otorhinolaryngol. 2015 Aug; 79(8):1294-8.